

# OSTEOPOROTIC VERTEBRAL FRACTURE; COMPARATIVE ANALYSIS OF UNILATERAL AND BILATERAL VERTEBROPLASTY RESULTS

● Mehmet Meral<sup>1</sup>, ● Merdan Orunoğlu<sup>2</sup>, ● Erhan Biçer<sup>1</sup>, ● Eser Berkürek<sup>1</sup>, ● Rahmi Kemal Koç<sup>3</sup>

<sup>1</sup>Private Erciyes Hospital, Clinic of Neurosurgery, Kayseri, Turkey

<sup>2</sup>Kayseri State Hospital, Clinic of Neurosurgery, Kayseri, Turkey

<sup>3</sup>Erciyes University Faculty of Medicine, Department of Neurosurgery, Kayseri, Turkey

## ABSTRACT

**Objective:** Osteoporotic vertebral fracture (OVF) results in increased morbidity and mortality, primarily in the elderly, leading to severe limitation of movement. In this study, we evaluated the results of unilateral and bilateral vertebroplasty (VP) procedures in OVF.

**Materials and Methods:** Two hundred fifty-seven patients who underwent VP for OVF were retrospectively studied and divided into two groups: unilateral (204 patients) and bilateral (53 patients) VP. The visual Analogue Scale (VAS) pain score and kyphotic angle were comparatively analyzed between the two groups.

**Results:** There was no statistically significant difference between the groups (unilateral and bilateral VP) in terms of VAS preop/postop variables and kyphosis.

**Conclusion:** We believe that unilateral VP is sufficient for significantly reducing the complication rate with anesthesia and radiation exposure and reducing the cost of the surgical procedure.

**Keywords:** Unilateral vertebroplasty, osteoporotic fracture, osteoporotic vertebral fracture, vertebroplasty, vertebral fracture

## INTRODUCTION

Osteoporosis is a systemic bone disease that is usually seen in elderly individuals, characterized by loss of bone mass due to deterioration in bone tissue and increased likelihood of fracture<sup>(1)</sup>. Vertebral fractures are one of the most common complications of osteoporosis<sup>(2)</sup>.

Osteoporotic vertebral fracture (OVF) results in increased morbidity and mortality, primarily in the elderly, leading to severe limitation of movement<sup>(3)</sup>. A significant portion of the pain that occurs as a result of vertebral fracture is due to the instability caused by the fracture. The pain increases significantly when the patient is moving and it is less at rest. The symptoms of OVF may result in loss of height due to vertebral collapse, spinal instability, and even kyphotic deformity. Therefore, rapid relief of pain and restoration of mobility and sagittal contour allows the patient to normalize<sup>(1,4)</sup>. Since the bones are osteoporotic in patients undergoing stabilization surgery, the use of long supports to increase strength and the use of anterior and posterior surgery together increase the surgical

risks in patients. For these reasons, percutaneous vertebroplasty (VP), which is described as minimally invasive, has been used in recent years. The risk of complications is lower compared to radical surgical interventions<sup>(5)</sup>. This method usually relieves fracture pain effectively in elderly patients<sup>(6)</sup>.

Recently, unilateral interventions have been recommended by some authors because they shorten the duration of surgery and anesthesia, reduce the cost of the procedure and the radiation dose received during the operation, reduce the risk of escape from the cement used, and avoid complications of placing a second working cannula<sup>(7,8)</sup>. In this study, we evaluated the clinical and radiologic results of unilateral and bilateral VP procedures in OVF.

## MATERIALS AND METHODS

This study included 257 patients who underwent VP for OVFs in our clinic between 2011 and 2022 (204 patients with unilateral and 53 patients with bilateral VP). The patients were studied retrospectively. Detailed informed consent was obtained from

**Address for Correspondence:** Rahmi Kemal Koç, Erciyes University Faculty of Medicine, Department of Neurosurgery, Kayseri, Turkey

**Phone:** +90 352 222 41 42 **E-mail:** kocrk@erciyes.edu.tr **Received:** 04.10.2023 **Accepted:** 26.01.2024

**ORCID ID:** orcid.org/0000-0001-9928-0468



© Copyright 2024 The Author. Published by Galenos Publishing House on behalf of Turkish Spine Society.

This is an open access article under the Creative Commons Attribution-NonCommercial-NoDerivatives 4.0 (CC BY-NC-ND) International License.



all patients for these interventions. All patients underwent a detailed physical and neurologic examination. Bone mineral density was evaluated by the T-Score method. Routine perop specimen for pathology was obtained from all patients. Primary bone tumors and metastatic tumors were excluded based on preoperative evaluation and/or postoperative pathology results. In addition, patients receiving radiation, those with active infection in the region, and chemotherapy patients were excluded from the study. A visual analog scale (VAS) score was used for preoperative and postoperative pain assessment. Angle measurements were performed for kyphotic angle restoration before and after surgery. Cobb angle measurements were used for this. The measurements were evaluated as segmenter Cobb angle on standing lateral radiographs. Cobb measurements were made using the software in Picture Archiving and Communication Systems.

### Surgical Technique

Prophylactic antibiotics were administered to all patients preoperatively. All VP procedures were performed percutaneously in the operating room in the prone position under fluoroscopy guidance. Kyphosis was attempted to be corrected by placing two transverse plane cylinders under the chest and iliac crest. Local anesthesia and sedation were preferred. In 12 cases, general anesthesia was used due to a lack of cooperation and failure of sedation. Local anesthesia was performed with 1% lidocaine before surgical intervention. During unilateral VP, we preferred to enter 5 mm lateral from the normal entry site to centralize the targeted point. Polymethylmethacrylate (PMMA) bone cement (Aditus Medical GmbH Berlin Germany) was used in all cases. Patients were continuously monitored for possible complications. The patients were mobilized with a brace 3 hours after surgery. Patients who had no problems were discharged the next day after a control X-ray and a control computed tomography (CT) if needed (according to the X-ray image).

This study was approved by the Kayseri Governorship Provincial Directorate of Health (approval number: E-75717723-619, date: 11.04.2023).

### Statistical Analysis

Statistical analysis was performed using IBM SPSS Statistics 21.0 (SPSS Inc, Chicago, IL, USA). Shapiro-Wilk test was used (data were found to be suitable for normal distribution using the Shapiro-Wilk test, histogram, and Q-Q graphs). Data were expressed as mean and expressed as standard deviation. Independent Samples t-test (alternative; Mann-Whitney U test) was used for intergroup comparisons. Paired Samples t-test was used for comparisons between times (preoperative and postoperative). The relationship between categorical variables was evaluated using Pearson's chi-square ( $\chi^2$ ) test and Fisher's exact test. A p-value <0.05 was considered statistically significant.

## RESULTS

Of the 257 patients operated on, 161 were female (62%) and 96 were male (37%). Their ages ranged between 50 and 90 years (mean: 68.2). Ninety seven of the patients had a significant history of trauma. Eighty six had a compelling movement that could be defined as trauma, while 74 had no history of trauma. Most fractures occurred at the L1 level and the least and above level at the T7 (Table 1). The pain was the presenting complaint in all patients and was the main reason for hospitalization. Of all patients, 88% had low back pain, 41% back pain, 56% low back and back pain, and 21% low back and leg pain.

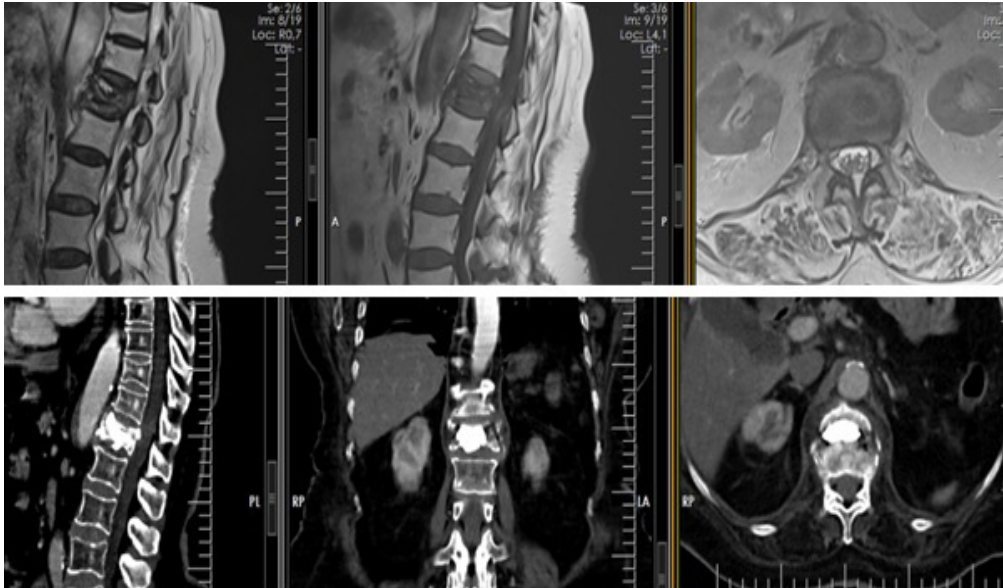
In addition, 43% of the patients had difficulty walking and postural disturbance, and 5% had numbness and loss of sensation in the legs. Physical and neurologic examinations of all patients revealed no deficits originating from the OVF except partial limitation of movement due to pain, posture disorder, and variable sensory deficits. Bone densitometry showed varying degrees of osteoporosis (T-score: -2.5 to -5). Two hundred thirteen fractures were in the lumbar region and 88 in the thoracic region. One hundred forty nine patients had a single-level vertebral fracture, 31 patients had two-level vertebral fractures and 30 patients had three or more level vertebral fractures. Unilateral VP was performed in 204 patients and bilateral VP in 53 patients. On average, 2-3.5 mL of PMMA was used for unilateral and 3.5-4 mL for bilateral VP. In the postoperative controls, the low back pain had disappeared in 214 of 228 patients and it had decreased in 14. Of the 107 patients with back pain, pain disappeared in 102, decreased in 3, and remained unchanged in 2. Of the 112 patients with posture disorder and difficulty in walking, 94 had improvement, 7 had partial improvement and 11 had no change (Table 1, Figure 1). The median VAS postop score [3.0 (2.0-4.0)] was statistically significantly lower than the VAS preop score [7.5 (6.0-9.0)] in patients operated through unilateral VP ( $p<0.001$ ). Similarly, the median VAS postop score [3.0 (2.0-4.0)] was statistically significantly lower than the VAS preop score [7.0 (6.0-8.0)] in patients operated through bilateral VP ( $p<0.001$ ). There was no statistically significant difference between the groups in terms of VAS preop/postop variables (Table 2). Similarly, there was no statistically significant difference between the groups in terms of kyphosis restoration variables (Figure 2, Table 3).

One patient with a single-level vertebral fracture and one patient with four or more levels of vertebral fractures died in the early postoperative period. Thromboembolism was considered as the cause of death. In two patients, the cement was found

**Table 1.** Distribution of fractures level

Levels	L5	L4	L3	L2	L1	T10-12	T7-9	T5-6
Unilateral VP	4	16	34	34	88	61	8	2
Bilateral VP	-	2	9	12	17	15	2	-

VP: Vertebroplasty



**Figure 1.** T12 unilateral VP. It was observed that the corpus can be completely filled with VP performed from a single pedicle  
 VP: Vertebroplasty

**Table 2.** Comparison of VAS preop and VAS postop scores between groups

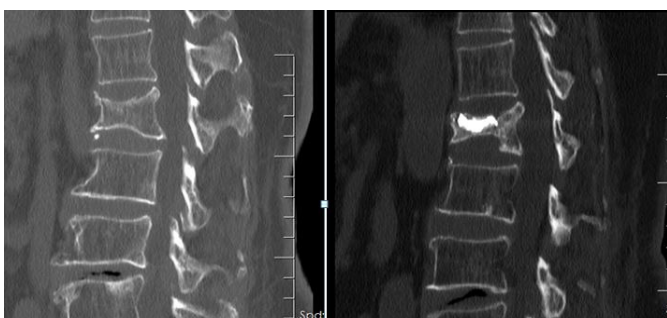
	<b>Unilateral VP (n=204)</b>	<b>Bilateral VP (n=53)</b>	<b>p-values</b>
Preop VAS	7.6±0.9 7.5 (6.0-9.0)	7.4±0.6 7.0 (6.0-8.0)	0.218
Postop VAS	3.2±0.5 3.0 (2.00-4.0)	3.1±0.5 3.0 (2.0-4.0)	0.109
p-values	<0.001	<0.001	

Data were expressed as mean ± standard deviation and median (minimum-maximum). Different lowercase letters in the same column indicate differences between groups, VP: Vertebroplasty, VAS: Visual analog scale

**Table 3.** Comparison of kyphosis restoration between groups

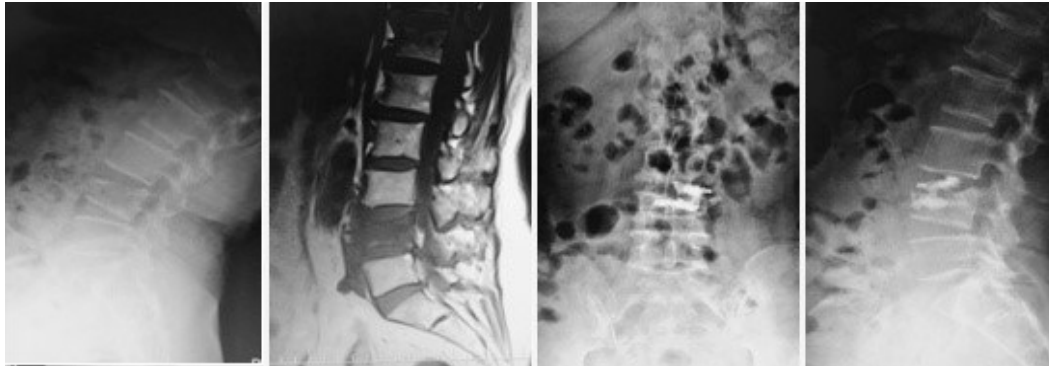
	<b>Unilateral VP (n=204)</b>	<b>Bilateral VP (n=53)</b>	<b>p-values</b>
Kyphosis restoration	6.1° ± 1.2 5.9° (4.0-9.1)	5.8° ± 1.2 5.8 (4.1-8.0)	0.057

Data were expressed as mean ± standard deviation and median (minimum-maximum). Different lowercase letters in the same column indicate differences between groups, VP: Vertebroplasty



**Figure 2.** Restoration of kyphosis

to have escaped into the canal. Although they did not cause a neurologic deficit, they were surgically removed. Two patients had a postoperative transient loss of strength in the lower extremity, which resolved during follow-up (no compression of the canal or root was detected on radiographs and CT scans). It was thought that the local anesthetic used was absorbed into the epidural region. In one patient who underwent VP with unilateral and single level, a new fracture occurred at the sixth upper level. Scoliosis was detected in one patient 19 months after unilateral VP. In 107 patients (42%), postoperative X-rays and CT scans showed small cement leaks at various sites with no clinical significance. Most of the leaks occurred in the disc space, paravertebral region, epidural space, and pedicle (Figure 3, Table 4). No infection was observed in any patient.



**Figure 3.** Escape of cement into the pedicle and disc space

<b>Table 4.</b> Distribution of complaints			
	<b>Unilateral VP (n=204)</b>	<b>Bilateral VP (n=53)</b>	<b>χ<sup>2</sup> p-values</b>
Low back pain	90.2 (184/204)	83.0 (47/53)	0.165 0.112
Back pain	42.6 (87/204)	37.7 (20/53)	0.314 0.418
Low/leg pain	18.6 (38/204)	30.2 (16/53)	3.388 0.052
Difficulty walking/ posture disorders	41.2 (84/204)	52.8 (28/53)	2.324 0.086
Numbness	4.9 (10/204)	7.5 (4/53)	0.572 0.321

Data expressed as % (n/total), VP: Vertebroplasty

## DISCUSSION

Vertebroplasty is a procedure in which cement is applied to the fractured vertebra at high pressure. Mostly PMMA is used. This method was first applied in 1987 by Galibert et al.<sup>(9)</sup> for the minimally invasive treatment of painful hemangiomas. In recent years, it has been widely used in the treatment of OVF causing severe pain and limitation of movement<sup>(10)</sup>. VP is a widely preferred technique for the stabilization of vertebral fractures, especially those that develop due to osteoporosis, and for the treatment of pain<sup>(1)</sup>. This method is also widely used in hemangiomas and malignant tumors of the spine<sup>(7)</sup>. This method also has complication risks. There may be risks related to anesthesia, surgical technique, and cement. The cement may escape into the epidural veins or epidural space, neural foramen, intervertebral disc, perivertebral venous plexus, or paravertebral soft tissues<sup>(11-13)</sup>. In addition, complications such as pneumothorax, pedicle fracture, pulmonary embolism, and infection may occur<sup>(14)</sup>.

In this technique, it is thought that the pain is controlled by filling the fractured vertebral body with cement, preventing gradual collapse and stabilizing micro-movements. However, it should not be ignored that thermal and chemical nerve ablation may also be effective. Aebli et al.<sup>(15)</sup> showed that

intravertebral temperature levels caused thermal necrosis after the use of intervertebral PMMA cement. Hulme et al.<sup>(10)</sup> reported in a study that VP gave 87% positive results on pain. In our study, VAS scores decreased postoperatively, and similar values were obtained in terms of the change in VAS scores between unilateral (7.6 to 3.2) or bilateral (7.4 to 3.1) VP and there was no statistical difference between them. In a published meta-analysis, both techniques provided excellent pain relief and improved quality of life. They encouraged the use of the unipedicular approach as the preferred surgical technique for the treatment of osteoporotic compression fractures due to shorter operative time, limited X-ray exposure, and minimal cement ingress and extravasation<sup>(16)</sup>.

In a biomechanical study, the distribution of cement in the corpus was investigated in unilateral and bilateral VP. As a result, it was shown that the stress of the vertebral body could be better balanced in bilateral VP, the maximum stress of the intervertebral disc was reduced and this was advantageous in terms of stability<sup>(17)</sup>.

While publications are indicating that VP has positive effects on height loss and improvement of kyphotic deformity, there are also publications showing that it has no effect<sup>(18)</sup>. Generally, studies have shown that the mean kyphotic angle restoration is 5-8.4 degrees for VP<sup>(18)</sup>. In our study, the effects of the unilateral or bilateral VP on kyphotic angle restoration were similar in preop and postop measurements, and no statistical difference was found between them. In addition to the relief of the patient's pain, we think that the fact that kyphosis was recovered to a certain extent with pillows during the operation and the osteoporotic vertebra was filled in this form contributed to this. Berlemann et al.<sup>(19)</sup> reported that fracture stage was an important determinant in achieving correction in their study, while Phillips et al.<sup>(20)</sup> reported that there was no relationship between fracture stage and deformity correction. It is thought that better results can be obtained in VP applications in single-level osteoporotic fractures compared to multilevel fractures. Chen et al.<sup>(7)</sup> reported that the clinical and radiologic results of unilateral or bilateral VP interventions were very similar.

Various studies have tried to reduce the effectiveness and complications of unilateral VP. Zhang and Deng<sup>(21)</sup> reported that a unilateral extrapedicular puncture route was used to ensure good distribution of bone cement and prevent leakage

of cement into the spinal canal. Hu et al.<sup>(22)</sup> also reported that unilateral VP using a curved diffusion needle in osteoporotic vertebral compression fractures provided a good distribution of bone cement and was safe.

McKiernan et al.<sup>(23)</sup> stated that the height loss of mobile fractures resulting from osteoporosis can be partially corrected, but there is no improvement in height loss with VP in immobile fractures. There is no mechanical method that provides kyphosis reduction in VP, so correction of the deformity is not possible. In order to reduce the kyphotic angle and maintain vertebral height, the patient can be positioned during the procedure, or support pads can be used. Cement injected after positioning may be effective in maintaining this position<sup>(1)</sup>. In our study, two transverse plane cylinders under the chest and iliac crest was placed in an attempt to correct kyphosis. We think that this procedure is effective in correcting fracture-related kyphosis.

## CONCLUSION

Unilateral VP provides fast and effective pain relief with local anesthesia and low surgical risk, especially in the treatment of patients with OVF. It is an effective method for preventing kyphosis and improving quality of life. The clinical and radiologic results of unilateral access and bilateral access are similar. Improvement in VAS scores and kyphotic angle restoration rates are similar in both techniques. No statistical difference was found between them. We believe that a unilateral approach is sufficient in terms of significantly reducing the complication rate with anesthesia and radiation exposure and reducing the cost of the surgical procedure.

## Ethics

**Ethics Committee Approval:** This study was approved by the Kayseri Governorship Provincial Directorate of Health (approval number: E-75717723-619, date: 11.04.2023).

**Informed Consent:** The patients were studied retrospectively. Detailed informed consent was obtained from all patients for these interventions.

## Authorship Contributions

Surgical and Medical Practices: M.M., M.O., E.B., Es.B., R.K.K., Concept: M.M., R.K.K., Design: M.M., R.K.K., Data Collection or Processing: M.M., M.O., E.B., Es.B., Analysis or Interpretation: M.M., R.K.K., Literature Search: M.M., R.K.K., Writing: M.M.

**Conflict of Interest:** The authors have no conflicts of interest to declare.

**Financial Disclosure:** The authors declared that this study received no financial support.

## REFERENCES

1. Kiraz I, Dağtekin A. Osteoporotik vertebra kırıkları vertebroplastisi/kifoplastisi-Avantajları/dezavantajları. *Türk Nöroşir Derg.* 2020;30:516-20.
2. Melton LJ 3rd, Atkinson EJ, Cooper C, O'Fallon WM, Riggs BL. Vertebral fractures predict subsequent fractures. *Osteoporos Int.* 1999;10:214-21.
3. Fribourg D, Tang C, Sra P, Delamarter R, Bae H. Incidence of subsequent vertebral fracture after kyphoplasty. *Spine (Phila Pa 1976).* 2004;29:2270-6.
4. Bademci G, Aydın Z, Batay F, Attar A, Çağlar Ş. Yaşlılarda ağrılı osteoporotik vertebra çökme kırıklarının tedavisinde kifoplasti, vertebroplastisi etkinliğinin değerlendirilmesi. *Türk Geriatri Dergisi.* 2005;8:5-9.
5. Çopuroğlu C, Çopuroğlu E, Çiftdemir M, Özcan M, Yalnız E. Vertebroplasty can intraoperative systemic complications be prevented. *J Turk Spinal Surg.* 2011;22:195-203.
6. Lieberman IH, Dudeney S, Reinhardt MK, Bell G. Initial outcome and efficacy of "kyphoplasty" in the treatment of painful osteoporotic vertebral compression fractures. *Spine (Phila Pa 1976).* 2001;26:1631-8.
7. Chen L, Yang H, Tang T. Unilateral versus bilateral balloon kyphoplasty for multilevel osteoporotic vertebral compression fractures: a prospective study. *Spine (Phila Pa 1976).* 2011;36:534-40.
8. Yılmaz A, Çakır M, Yücetaş CŞ, Urfalı B, Üçler N, Altaş M, et al. Percutaneous kyphoplasty: Is bilateral approach necessary? *Spine (Phila Pa 1976).* 2018;43:977-83.
9. Galibert P, Deramond H, Rosat P, Le Gars D. Note préliminaire sur le traitement des angiomes vertébraux par vertébroplastie acrylique percutanée [Preliminary note on the treatment of vertebral angioma by percutaneous acrylic vertebroplasty]. *Neurochirurgie.* 1987;33:166-8.
10. Hulme PA, Krebs J, Ferguson SJ, Berlemann U. Vertebroplasty and kyphoplasty: a systematic review of 69 clinical studies. *Spine (Phila Pa 1976).* 2006;31:1983-2001.
11. Deramond H, Dion JE, Chiras J. Complications. IN: Mathis JM, Deramond H, Belkoff SM (Eds). *Percutaneous vertebroplasty.* 1st ed. New York: Springer-Verlag Inc. 2002;p:165-74.
12. Katsanos K, Sabharwal T, Adam A. Percutaneous cementoplasty. *Semin Intervent Radiol.* 2010;27:137-47.
13. Perez-Cruet MJ, Fessler RG, Perin NI. Review: complications of minimally invasive spinal surgery. *Neurosurgery.* 2002;51(5 Suppl):S26-36.
14. Hacıyakupoğlu E, Kınalı B, Oktay K, Yılmaz DM, Hacıyakupoğlu S. Vertebroplastisi. *Arşiv Kaynak Tarama Dergisi.* 2012;21:283-98.
15. Aebli N, Goss BG, Thorpe P, Williams R, Krebs J. In vivo temperature profile of intervertebral discs and vertebral endplates during vertebroplasty: an experimental study in sheep. *Spine (Phila Pa 1976).* 2006;31:1674-8.
16. Sun H, Li C. Comparison of unilateral and bilateral percutaneous vertebroplasty for osteoporotic vertebral compression fractures: a systematic review and meta-analysis. *J Orthop Surg Res.* 2016;11:156.
17. Dai H, Liu Y, Han Q, Zhang A, Chen H, Qu Y, et al. Biomechanical comparison between unilateral and bilateral percutaneous vertebroplasty for osteoporotic vertebral compression fractures: A finite element analysis. *Front Bioeng Biotechnol.* 2022;10:978917.
18. Kim DY, Lee SH, Jang JS, Chung SK, Lee HY. Intravertebral vacuum phenomenon in osteoporotic compression fracture: report of 67 cases with quantitative evaluation of intravertebral instability. *J Neurosurg.* 2004;100(1 Suppl Spine):24-31.
19. Berlemann U, Franz T, Orler R, Heini PF. Kyphoplasty for treatment of osteoporotic vertebral fractures: a prospective non-randomized study. *Eur Spine J.* 2004;13:496-501.
20. Phillips FM, Ho E, Campbell-Hupp M, McNally T, Todd Wetzel F, Gupta P. Early radiographic and clinical results of balloon kyphoplasty for the treatment of osteoporotic vertebral compression fractures. *Spine (Phila Pa 1976).* 2003;28:2260-5.
21. Zhang T, Deng Y. A design of a targeted puncture trajectory applied to unilateral extrapedicular percutaneous vertebroplasty. *BMC Musculoskelet Disord.* 2023;24:268.
22. Hu H, Lin X, Tan L. Thoracolumbar osteoporotic vertebral compression fracture treatment by unilateral percutaneous vertebroplasty using curved diffusion needle. *Indian J Orthop.* 2023;57:899-906.
23. McKiernan F, Faciszewski T, Jensen R. Does vertebral height restoration achieved at vertebroplasty matter? *J Vasc Interv Radiol.* 2005;16:973-9.