

# COMPARISON OF CERVICAL CAGE AND CERVICAL DISC PROSTHESIS IN CERVICAL DISC HERNIATION: A SINGLE-CENTER STUDY

© Faruk Altinel<sup>1</sup>, © Bora Limnili<sup>2</sup>, © Gözde Özcan Söylev<sup>3</sup>, © Yonca Özvardar Pekcan<sup>4</sup>

<sup>1</sup>Başkent University Zübeyde Hanım Application and Research Centre, Clinic of Neurosurgery, İzmir, Turkey

<sup>2</sup>Başkent University Zübeyde Hanım Application and Research Centre, Clinic of Orthopedics and Traumatology, İzmir, Turkey

<sup>3</sup>Başkent University Zübeyde Hanım Application and Research Centre, Clinic of Physical Therapy and Rehabilitation, İzmir, Turkey

<sup>4</sup>Başkent University Zübeyde Hanım Application and Research Centre, Clinic of Anaesthesiology and Reanimation, İzmir, Turkey

## ABSTRACT

**Objective:** Anterior cervical discectomy (ACD) and fusion is the standard surgical treatment for cervical radiculopathy. The cervical disc prosthesis is designed to prevent complications such as pseudoarthrosis and adjacent segment degeneration and to preserve spinal motion.

**Materials and Methods:** In this retrospective study, 57 patients who underwent microsurgical ACD between 2015 and 2020 were included. Patients were divided into four groups: I group cervical cage (CC), II group cervical disc prosthesis (CDP) at one level, III group and CDP, and IV group CC+CC at two levels. For cage application, 1 cc of canceled bone graft was used in each case. In our study, the clinical outcomes, operations, and complications of patients who underwent CC and CDP and those who underwent double-level hybrid CC and CDP were evaluated during the 2-year follow-up period.

**Results:** When the groups were compared according to the localization of patient complaints ( $p=0.235$ ) and neurological findings such as preoperative brachial neuropathy, upper extremity paresis, and cord compression ( $p=0.781$ ), there was no statistically significant difference ( $p>0.05$ ). In preoperative cervical magnetic resonance imaging (MRI) reports; In the CDP group, protrusion and extrusion were reported in the midline in 13 (22.8%) patients and in the lateral location in 17 (29.8%) patients. Osteophyte formation was more frequently encountered in the midline and lateral locations in the CC group (17.5%). Osteophyte formation was not observed in the CDP group. A significant difference was found in the preoperative cervical MRI results ( $p=0.006$ ) and postoperative cervical spinal alignment averages ( $p=0.021$ ). In all groups, C 5/6 (64.9%) and C 6/7 (40.4%) were the frequently affected disc spaces. In those who underwent CDP, soft disc was observed in 24 (80.0%) patients, and hard disc, CC, CDP+CC, was observed in 6 (20%) cases. A hard disc was detected in the entire group with CC (two distances). There was a statistically significant difference according to the affected disc nature and spacing ( $p<0.001$ ). When all groups were compared according to operation times, operation results, and complications, there was no significant difference between the groups ( $p=0.074$ ).

**Conclusion:** Microsurgical ACD is an effective and reliable method preferred in cervical disc herniations. Although autologous or heterologous bone grafts and cages are used to ensure fusion, CDP, which reduces adjacent segment disease and provides spinal mobility, has been preferred more frequently in recent years.

**Keywords:** Anterior, cervical discectomy, cage, disc prosthesis

## INTRODUCTION

Cervical intervertebral disc herniations occur when a part of the nucleus pulposus or annulus fibrosus occupies space within the spinal canal and are an important pathology that causes neck pain, radiculopathy, and myelopathy. It may limit working life and daily activities, and cervical spine surgery is effective when conservative treatment is not sufficient to reduce pain<sup>(1,2)</sup>. The most appropriate method for treating symptomatic cervical disc herniation is microsurgical anterior cervical discectomy. In recent years, with the introduction of the microscope, non-fusion or fusion techniques have been used<sup>(1,3)</sup>. Discectomy with fusion relieves the pressure on the spinal cord and nerve roots,

and autologous or heterologous bone grafting and cervical cage (CC) are applied to achieve appropriate cervical vertebra alignment and solid arthrodesis with minimal risk<sup>(4-6)</sup>. Although there are many surgical options for cervical disc herniation, cervical disc prosthesis (CDP) is now an established and validated option that has demonstrated its safety and effectiveness with good clinical results<sup>(4)</sup>. In the posterior approach, posterior cervical foraminotomy (PCF) can be performed openly or endoscopically<sup>(7-9)</sup>.

In this study, in 57 patients with single- and double-level cervical disc herniation who were operated on using a microscope with an anterior approach in our clinic, posterior longitudinal ligament excision was performed and cage and/or CDP were used instead of bone graft. In cases of double-level

**Address for Correspondence:** Faruk Altinel, Başkent University Zübeyde Hanım Application and Research Centre, Clinic of Neurosurgery, İzmir, Turkey

**Phone:** +90 532 215 42 36 **E-mail:** farukaltinel@gmail.com **Received:** 23.12.2023 **Accepted:** 02.04.2024

**ORCID ID:** orcid.org/0000-0002-8326-3900



degenerative disc herniation, a hybrid cage or cage and CDP were used together.

## MATERIALS AND METHODS

The information of 57 patients who underwent surgery with a diagnosis of cervical disc herniation in our clinic between 2015 and 2020 was collected from the nucleus database. In patient groups, age, gender, motor and sensitive deficits, disc nature (hard, soft), osteophyte formation, the most common disc level, two or more affected levels, the relationship of the disc with the posterior longitudinal ligament and postoperative cervical vertebra curvature, early and postoperative 6<sup>th</sup>-month Visual Analogue Scale (VAS) results, healing status according to Odom's criteria, reoperation, and developing complications were evaluated. It was questioned whether there might be other reasons for symptoms such as neck pain, pain radiating to the arm, and shoulder pain. Preoperative plain radiographs, cervical magnetic resonance imaging (MRI), and computer tomography were examined in all patients. Cervical lordosis changes, intervertebral level stenosis, and osteophyte formation in the posterior vertebra were recorded. Patients with fractures, infections, deformities, tumors, and chronic systemic illnesses, such as rheumatoid arthritis and neurodegenerative diseases, were not included in this study. Postoperative cervical vertebral sagittal alignment was compared between the groups (Figure 1). The number of patients meeting the criteria was 29 males (50.9%) and 28 females (49.1%), and the follow-up period was 2 years. Patients according to the type and level of fusion; were divided into 4 groups: group I, CC; group II, CDP at one level; group III, CC+CDP; and group IV, CC+CC at two levels. In cases with CC, 1 cc canceled bone allograft was placed inside the cage and placed at the level to achieve better fusion. Patients with cervical trauma, neoplasm, infection, bleeding tendency, and chronic systemic disease were not included in the study. The patients had neck pain before and after surgery. Severity was evaluated using VAS results, and postoperative quality of life was evaluated using Odom's criteria.

This study was approved by the Başkent University Medicine and Health Sciences Research Board (approval number: KA23/267, date: 22.08.2023) and supported by the Başkent University Research Fund.

## Statistical Analysis

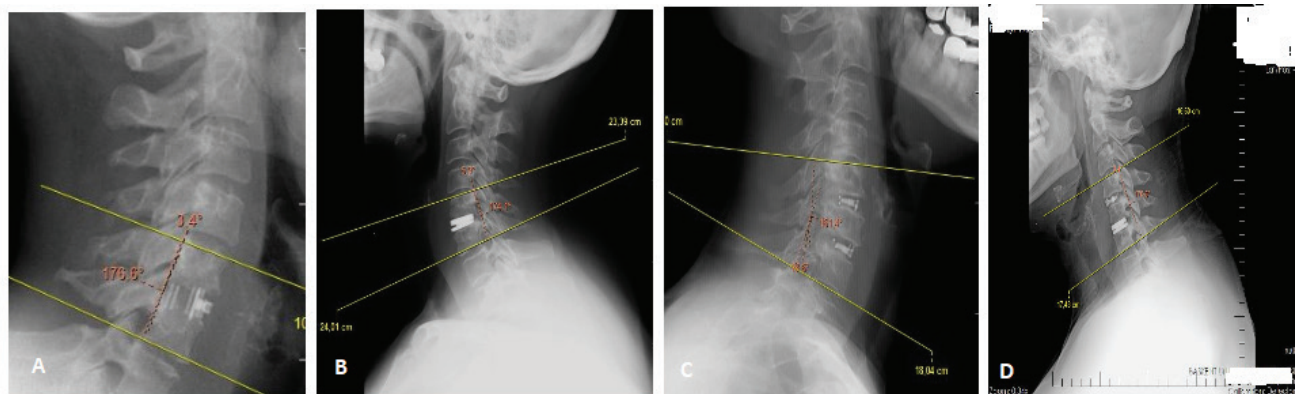
Statistical Package for Social Sciences for Windows 11.0 program (SPSS Inc., Chicago) was used. While evaluating the data, descriptive statistics were given as mean, standard deviation, and n (%). Categorical variables were compared using the chi-square ( $\chi^2$ -test). If the alpha value was less than 0.05 ( $p < 0.05$ ), the data were considered statistically significant.

## RESULTS

When the groups were evaluated, the average age of the group I cases was 46.5 years, 20 (66.7%) of whom were female, and in the II, III, and IV group cases, the average age was over 55 years, 19 (70.3%) of whom were male. In preoperative cases, brachial neuropathy (pain radiating to the arm) in group I was found in 10 (33.3%), reflex disorders in 7 (23.3%), paresis in the upper extremity in 12 (40.0%), and Brown-Séquard findings in 1 (3.3%). In groups II and IV, brachial neuropathy and paresis were more frequent. It was determined that cord compression findings (clonus) developed in 2 (6.7%) cases. Because of the comparisons, there was no statistically significant difference ( $p > 0.05$ ) (Table 1).

In operated cases, in all groups, the affected disc space was frequently C 5/6 in 37 cases (64.9%) and C 6/7 in 23 cases (40.4%). In those who underwent CDP, soft disc was observed in 24 (80.0%) patients and hard discs in 6 (20%) cases. Hardness was detected in the entire group with CC, CDP+CC, and CC (two distances). There was a statistically significant difference according to the affected disc nature and spacing ( $p < 0.001$ ) (Table 2).

In the preoperative cervical MRI reports of the cases; In the CDP group, protrusion and extrusion were reported in the midline in 13 (22.8%) patients and in the lateral location in



**Figure 1.** Post operative cervical sagittal alignment of the cases in cervical lateral radiograph, A) C5-6 cervical cage, B) C5-6 cervical disc prosthesis, C) hybrid C5-6 and C6-7 cage (CC+CC), D) hybrid C4-5 cage and C5-6 disc prosthesis (CDP+C)  
 CDP: Cervical disc prosthesis, CC: Cervical cage

17 (29.8%) patients. Osteophyte formation was more frequently encountered in the midline and lateral locations in the CC group (17.5%). Osteophyte formation and autofusion were not observed in the CDP group. Due to restrictions set by the Social Security Institution in Turkey, patient selection for CDP was limited to those who met certain criteria. However, if used in a single distance, at C3/4, C4/5, C5/6, and C6/7 disc distances, over the age of 18, it can be used in patients with no degenerative changes in the posterior elements (such as facet arthropathy, osteoporosis), no listhesis, no infection, and traumatic disc herniation. CDP was applied to patients who met all the criteria, such as having no cervical kyphosis or cervical lordotic, and showing on MRI that the height of the disc space

to be applied was at least half of the height of the healthy adjacent disc. There was a statistically significant difference between the preoperative cervical MRI results ( $p=0.006$ ) and the postoperative cervical spinal alignment averages ( $p=0.021$ ) was determined to be  $4.28^{\circ}$ - $5.84^{\circ}$  on average in the single-level CDP and CC groups and  $4.66^{\circ}$ - $7.22^{\circ}$  in those who underwent two-level CDP+CC and CC hybrid surgery (Table 3).

Although the operation time was performed at an average of 115.50-141.60 min in all 4 groups, postoperative VAS results showed a significant decrease and excellent improvement was detected in 47 (82.45%) cases. As a result of the surgeries in all cases, temporary dysphagia was observed in 2 (3.50%) cases, and only 1 patient (1.75%) who underwent hybrid CC was re-

**Table 1.** Demography, symptoms, and neurological findings of preoperative cases

Operation	n	Age	Sex	Arm pain			Neurological findings						
				W/M	R	L	Bilateral	Radicular		Cord compression			
				B/N		Reflex disorder	Paresis	Br-Sq clonus					
CDP	30	46.5	20/10	14	12	4	10	7	12	1	-	$\chi^2=8.037$ $p=0.235$	$\chi^2=5.574$ $p=0.781$
CC	10	58.2	4/6	2	8	-	5	-	4	-	1		
CDP+CC	5	51.2	1/4	2	3	-	2	2	1	-	-		
CC+CC	12	55.5	3/9	5	4	3	4	2	5	-	1		
Total	57												

$\chi^2$ : Chi-squared test statistic, W: Woman, M: Male, R: Right, L: Left, B/N: Brachial neuropathy, Br-Sq: Brown-sequard, CDP: Cervical disc prosthesis, CC: Cervical cage, n: Number

**Table 2.** Intervertebral disc levels and disc nature characteristics of operated patients

Operation	Disc levels				Disc nature			
	C3/4	C4/5	C5/6	C6/7	Hard	Soft	n	
CDP	1	3	19	7	6	24	30	$\chi^2=5.684$ $p=0.771$
CC	1	1	4	4	8	-	10	
CDP+CC	-	1	4	3	5	-	5	
	2	-	-	-	5	-	-	
CC+CC	2	3	10	9	24	-	12	$\chi^2=46.981$ $p<0.001$
	-	-	-	-	-	-	-	
Total	6	8	37	23	49	24	-	

$\chi^2$ : Chi-squared test statistic, CDP: Cervical disc prosthesis, CC: Cervical cage, SDP: n: Number

**Table 3.** Preoperative cervical MRI results and postoperative CSA averages

Operation	n	Cervical MRI				Postop CSA				
		Protruded	Extrusion	Osteophyte		Protruded	Extrusion	Osteophyte		
CDP	30	6	7	-	$\chi^2=17.918$ $p=0.006$	10	7	-	4.28	$\chi^2=14.898$ $p=0.021$
CC	10	2	2	3		2	-	1	5.84	
CDP+CC	5	2	1	1		2	2	2	4.66	
CC+CC	12	14	-	2		4	-	4	7.22	
Total	57									

$\chi^2$ : Chi-squared test statistic, CDP: Cervical disc prosthesis, CC: Cervical cage, MRI: Magnetic resonance imaging, CSA: Cervical spinal alignment, n: Number

operated because of cage displacement (CD). When all groups are compared according to operation times, operation results, and complications, there is no statistically significant difference between the groups ( $p=0.074$ ) (Table 4).

## DISCUSSION

Cervical intervertebral disc herniations occur when part of the nucleus pulposus or annulus fibrosus occupies space within the spinal canal. Disc degeneration can lead to symptoms such as osteophyte formation, disc narrowing, subluxation, instability of one cervical vertebra relative to another, or disc protrusion, i.e., pathological changes. Symptoms such as neck pain, radicular, motor, and sensory disorders, and signs of cord compression may occur, whereas MRI shows signs of radicular and cord compression. C3-4, C4-5, and often C5-6, C6-7 levels are affected<sup>(3,10)</sup>.

In surgical treatment, discectomy without fusion with the anterior approach or cervical discectomy with fusion (mACDF), in which different bone grafts and devices are used to obtain good bone fusion, and PCF with the posterior approach are the preferred surgical techniques<sup>(1,2,10)</sup>. Anterior contralateral microdiscectomy without fusion is a minimally invasive technique that can be recommended in foraminal or lateral disc lesions, ventral osteophytes, and instability of the affected disc space<sup>(11)</sup>. Although titanium cages, carbon fiber-reinforced polymer cages, polyetheretherketone, and polymethylmethacrylate cages are frequently used in mASDF surgery to provide mechanical support to the spine, preserve disc height, and restore sagittal lordosis, negative results have also been reported in some studies<sup>(1)</sup>. In recent years, microsurgical cervical surgery with anterior intervention has been reported. CDP surgeries were preferred over mACDF, and good results were obtained<sup>(4)</sup>.

It has also been reported that there is an increase in the number of hybrid surgeries in which mACDF and CDP are used together in patients with multilevel cervical degenerative disc disease<sup>(12,13)</sup>. Such hybrid surgeries are performed because the degree of degeneration at each level is different and fusion or arthroplasty is applied equally to all levels. It is recommended in cases where application is difficult. Such hybrid surgeries limit the hypermobility of adjacent segments while preserving

the segmental motion of each segment. In patients with multilevel cervical degenerative disc disease, several studies have reported better outcomes with combined mACDF and CDP than with mACDF or CDP alone. In addition, postoperative evaluation has shown that the complication rate and functional score are excellent or similar, the arthroplasty level is above the fusion level, or there is no significant difference in the pressure applied to the adjacent disc<sup>(13)</sup>.

Although successful clinical outcomes can be achieved with mACDF, postoperative complications such as pseudoarthrosis, instrumentation failure, and adjacent segment degeneration (ASD) have been the biggest concerns<sup>(4,14,15,16)</sup>. However, pseudoarthrosis is not observed in CDP, new problems such as heterotopic ossification and bone loss occur, and it has proven to be cost-effective compared with long-term follow-up<sup>(4,17,18)</sup>. In CDP, selecting the appropriate patient group is important to achieve a good prognosis. In addition, the postoperative prognosis of patients with one-or two-segment radiculopathy or myelopathy caused by soft disc herniation is excellent<sup>(16)</sup>.

There are many studies in the literature comparing long-term results after CDP and mACDF. In these studies, no significant difference was found in the results of CDP and mACDF when comparing patients followed for short periods of up to 2 years. However, in the 4-7-year patient follow-up results, CDP results were superior to mACDF in outcomes such as neck disability index, 36-item short health form survey results, and dysphagia, and the incidence of postoperative ASD was found to be lower in the CDP group than in the mACDF group<sup>(19,20,21)</sup>. Hilibrand and Robbins<sup>(14)</sup> It has been reported that 2.9% of patients undergoing anterior interbody fusion will most likely develop ASD requiring cervical intervention<sup>(14)</sup>. Again, in studies comparing mACDF and PCF, although there is no difference in clinical outcomes, complication, and reoperation rates, PCF has a lower rate. Cervical alignment, which is costly, is better and does not increase the risk of adjacent segment disease (ASD)<sup>(22)</sup>. Although ASD was not encountered in our four-group case series, long-term follow-up over 2 years could not be performed because of the distribution of the cases to different centers and the patients' non-compliance with the long-term follow-up protocol.

**Table 4.** Operation times, outcomes and complications of the cases

Operation	n	Operation time (mean)	Operation outcome							
			VAS		Odom's			Complication		
			Pre	post	E	G	F	P	Tdf	CD
CDP	30	115.50	7.0	0.03	29	1	-	-	1	-
CC	10	122.78	6.2	0.7	6	3	1	-	-	1
CDP+CC	5	141.60	7.4	0.2	5	-	-	-	-	-
CC+CC	12	132.83	6.9	1.0	7	2	2	1	1	-

Odom's criteria: excellent (E), good (G), fair (F), poor (P),  $\chi^2$ : Chi-squared test statistic, CDP: Cervical disc prosthesis, CC: Cervical cage, VAS: Visual analogue scale, Tdf: Temporary dysphagia, CD: Cage displacement, CDP: Cervical disc prosthesis, n: Number

$\chi^2=23.460$   
 $p=0.074$

Long-term prognosis results are important in the fusion of the operated segment after mACDF surgery. The surgeon should also consider the instruments and techniques used in surgery and patient factors. Diabetes, smoking, body mass index, vitamin D deficiency, and cortisone use are factors that negatively affect surgical results<sup>(1)</sup>. To achieve bone fusion in mACDF surgeries, products such as autologous spongy bone and demineralized bone matrix combined with bone substitute tricalciumphosphate or bone morphogenic protein can be used; however, high fusion cannot be achieved with bone substitutes, and infection may develop<sup>(5)</sup>.

In recent years, different cages have been discussed to achieve osteosynthesis<sup>(2,5)</sup>. Better fusion was achieved using self-locking cages. Different types of anchors and screws (passing through the cage and settling on adjacent vertebrae) were designed for the cages. In our cases, cages with anchors were mostly used, and in fewer cases, cages with screws were used. Only in 1 case in hybrid surgery in the IV group, a decrease in the height of the vertebral body due to the displacement of the screw cage, pseudoarthrosis and CD, and spinal cord compression findings were detected, and the patient was re-admitted for surgery. In this case, dysphagia, vocal cord paresis, and right upper extremity paresis were detected in the early postoperative period after reoperation, and the vocal cord paresis resolved within 45 days.

CDP is preferred because it facilitates vertebral movement at the operation level and is less likely to cause ASD<sup>(4)</sup>. With CDP, patients can return to work early and the neck can maintain its natural range of motion. In recent years, disc prostheses made of titanium, chrome cobalt, ceramics, and hard silicone have been introduced<sup>(4)</sup>.

During CDP surgery, which is similar to mACDF surgery, discectomy is performed using an anterior approach. After foraminal decompression, an appropriate disc prosthesis is placed between the intervertebral level. However, some results may be encountered after CDP, such as pseudoarthrosis, ASD, and height loss at the intervertebral level<sup>(17,23)</sup>. Nevertheless, there have been no long-term consequences related to CDP and cage use in our cases.

Anterior bone loss (ABL) is a potential complication that occurs mid-term at the 5-year follow-up and has been reported in >50% of cases. It can cause disability, increased pain, and loss of the anterior part of the implant, among other issues. The cause of ABL is unknown, but it may be related to infection, debris accumulation, micromotion, and stress protection<sup>(23)</sup>.

In our hybrid case, there was a displacement of the CD and ABL within the first 3 weeks. It is unclear whether the subchondral collapse and ABL in the upper and lower vertebrae of our patient were caused by the surgical technique or the screw cage used. In the relevant retrospective evaluation, it was believed that the bone cancellous structure of the case developed because of the screw cage compression applied at a softer and double distance.

In the last two decades, many randomized controlled trials have been conducted on SDP. The results indicate that CDP helps reduce ASD. It also prevents complications such as pseudoarthrosis and ABL. Moreover, it helps in achieving a more appropriate movement of the spine<sup>(2,4)</sup>.

## CONCLUSION

Microdiscectomy with an anterior approach is the preferred surgical method for the treatment of cervical disc disease. Advances in minimally invasive techniques, imaging, microsurgery, and endoscopy techniques have led to the development of current surgical approaches. In the 2-year follow-up of our cases, it was determined that the results were excellent in the CDP patient groups after microdiscectomy. Therefore, in mACDF and CDP surgery, preoperative clinical and radiological evaluation, surgical team skill, instrument characteristics, and early and late postoperative follow-ups are the main factors affecting prognosis.

## Ethics

**Ethics Committee Approval:** This study was approved by the Başkent University Medicine and Health Sciences Research Board (approval number: KA23/267, date: 22.08.2023) and supported by the Başkent University Research Fund.

**Informed Consent:** Retrospective study.

## Authorship Contributions

Surgical and Medical Practices: F.A., B.L., G.Ö.S., Y.Ö.P., Concept: F.A., Design: F.A., Data Collection or Processing: F.A., B.L., G.Ö.S., Analysis or Interpretation: F.A., B.L., G.Ö.S., Literature Search: F.A., B.L., G.Ö.S., Y.Ö.P., Writing: F.A., Y.Ö.P.,

**Conflict of Interest:** The authors have no conflicts of interest to declare.

**Financial Disclosure:** The authors declared that this study received no financial support.

## REFERENCES

1. Kang KC, Jang TS, Jung CH. Cervical radiculopathy: focus on factors for better surgical outcomes and operative techniques. *Asian Spine J*. 2022;16:995-1012.
2. Mazas S, Benzakour A, Castelain JE, Damade C, Ghailane S, Gille O. Cervical disc herniation: which surgery? *Int Orthop*. 2019;43:761-6.
3. Sefo H, Ahmetpahic A, Hajdarpasic E, Barucija M, Muftic M. Surgical Treatment of the Patients with Cervical Disc Herniation at Clinical Center of University of Sarajevo, Bosnia and Herzegovina. *Med Arch*. 2021;75:116-21.
4. Wang QL, Tu ZM, Hu P, Kontos F, Li YW, Li L, et al. Long-term results comparing cervical disc arthroplasty to anterior cervical discectomy and fusion: a systematic review and meta-analysis of randomized controlled trials. *Orthop Surg*. 2020;12:16-30.
5. Faldini C, Chehrassan M, Miscione MT, Aciri F, d'Amato M, Pungetti C, et al. Single-level anterior cervical discectomy and interbody fusion using PEEK anatomical cervical cage and allograft bone. *J Orthop Traumatol*. 2011;12:201-5.

6. Buchowski JM, Liu G, Bunmaprasert T, Rose PS, Riew KD. Anterior cervical fusion assessment: surgical exploration versus radiographic evaluation. *Spine (Phila Pa 1976)*. 2008;33:1185-91.
7. Parihar VS, Yadav N, Ratte S, Dubey A, Yadav YR. Endoscopic anterior approach for cervical disc disease (disc preserving surgery). *World Neurosurg*. 2018;115:e599-609.
8. Song Z, Zhang Z, Hao J, Shen J, Zhou N, Xu S, et al. Microsurgery or open cervical foraminotomy for cervical radiculopathy? A systematic review. *Int Orthop*. 2016;40:1335-43.
9. O'Toole JE, Sheikh H, Eichholz KM, Fessler RG, Perez-Cruet MJ. Endoscopic posterior cervical foraminotomy and discectomy. *Neurosurg Clin N Am*. 2006;17:411-22.
10. Denaro V, Di Martino A. Cervical spine surgery: an historical perspective. *Clin Orthop Relat Res*. 2011;469:639-48.
11. Aydin Y, Kaya RA, Can SM, Türkmenoğlu O, Cavusoglu H, Ziyal IM. Minimally invasive anterior contralateral approach for the treatment of cervical disc herniation. *Surg Neurol*. 2005;63:210-8.
12. Sharma JK, Varma KKK, Mallepally AR, Marathe N, Rustagi T, Mohapatra B, et al. Two-level anterior cervical discectomy and fusion versus hybrid total disc replacement for bilevel pathology with cervical radiculopathy/myelopathy: a comparative study with a minimum 2-year follow-up in an Indian population. *Asian Spine J*. 2022;16:493-501.
13. Jia Z, Mo Z, Ding F, He Q, Fan Y, Ruan D. Hybrid surgery for multilevel cervical degenerative disc diseases: a systematic review of biomechanical and clinical evidence. *Eur Spine J*. 2014;23:1619-32.
14. Hilibrand AS, Robbins M. Adjacent segment degeneration and adjacent segment disease: the consequences of spinal fusion? *Spine J*. 2004;4:190S-4S.
15. Eck JC, Humphreys SC, Lim TH, Jeong ST, Kim JG, Hodges SD, et al. Biomechanical study on the effect of cervical spine fusion on adjacent-level intradiscal pressure and segmental motion. *Spine (Phila Pa 1976)*. 2002;27:2431-4.
16. Park DH, Ramakrishnan P, Cho TH, Lorenz E, Eck JC, Humphreys SC, et al. Effect of lower two-level anterior cervical fusion on the superior adjacent level. *J Neurosurg Spine*. 2007;7:336-40.
17. Heo DH, Lee DC, Oh JY, Park CK. Bone loss of vertebral bodies at the operative segment after cervical arthroplasty: a potential complication? *Neurosurg Focus*. 2017;42:E7.
18. Kong L, Ma Q, Meng F, Cao J, Yu K, Shen Y. The prevalence of heterotopic ossification among patients after cervical artificial disc replacement: A systematic review and meta-analysis. *Medicine (Baltimore)*. 2017;96:e7163.
19. Dong L, Xu Z, Chen X, Wang D, Li D, Liu T, et al. The change of adjacent segment after cervical disc arthroplasty compared with anterior cervical discectomy and fusion: a meta-analysis of randomized controlled trials. *Spine J*. 2017;17:1549-58.
20. Zhong ZM, Zhu SY, Zhuang JS, Wu Q, Chen JT. Reoperation after cervical disc arthroplasty versus anterior cervical discectomy and fusion: a meta-analysis. *Clin Orthop Relat Res*. 2016;474:1307-16.
21. Janssen ME, Zigler JE, Spivak JM, Delamarter RB, Darden BV 2nd, Kopjar B. ProDisc-C total disc replacement versus anterior cervical discectomy and fusion for single-level symptomatic cervical disc disease: seven-year follow-up of the prospective randomized U.S. Food and Drug Administration Investigational Device Exemption Study. *J Bone Joint Surg Am*. 2015;97:1738-47.
22. Liu WJ, Hu L, Chou PH, Wang JW, Kan WS. Comparison of anterior cervical discectomy and fusion versus posterior cervical foraminotomy in the treatment of cervical radiculopathy: a systematic review. *Orthop Surg*. 2016;8:425-31.
23. Kieser DC, Cawley DT, Fujishiro T, Mazas S, Boissière L, Obeid I, et al. Risk factors for anterior bone loss in cervical disc arthroplasty. *J Neurosurg Spine*. 2018;29:123-9.