

CLINICAL OUTCOMES OF EN-BLOC CERVICAL LAMINOPLASTY FOR CERVICAL SPONDYLOTIC MYELOPATHY

© Mehmet Meral¹, © Rahmi Kemal Koç²

¹Private Erciyes Hospital, Clinic of Neurosurgery, Kayseri, Turkey

²Erciyes University Faculty of Medicine, Department of Neurosurgery, Kayseri, Turkey

ABSTRACT

Objective: To evaluate the clinical outcomes of patients with cervical spondylotic myelopathy (CSM) operated using the en-bloc laminoplasty technique and the effects of surgical timing on clinical outcomes.

Materials and Methods: This study analyzed the preoperative and postoperative outcomes of 32 patients who underwent en-bloc cervical laminoplasty for CSM. The effect of preoperative symptom duration on postoperative clinical outcomes and the clinical outcomes of en-bloc cervical laminoplasty were evaluated. The modified Japanese Orthopedic Association (mJOA) score and Nurick scale were used for preoperative and postoperative functional and neurological evaluation.

Results: The mean age of the patients was 66.3 years. Twenty-one patients were male (65.6%) and 11 were female (34.4%), and the mean follow-up period was 34.7 months. Seven of eight patients with mJOA scores of 15 and above had complete recovery and one had partial benefit. Of the 10 patients with mJOA scores between 12 and 15, 7 improved above 15 points and 3 showed partial improvement. Of the 14 patients with a score below 12, 10 had improved to the 12-15 range, whereas 3 had remained unchanged. Deterioration was observed in one patient.

Conclusion: Low mJOA scores, high Nurick grade, and long preoperative symptom duration negatively affected surgical treatment results.

Keywords: Cervical laminoplasty, cervical spondylotic myelopathy, cervical spinal stenosis, en-bloc cervical laminoplasty, myelopathy

INTRODUCTION

Cervical spondylotic myelopathy (CSM) was described by Stookey in 1928. It is one of the most serious complications of cervical spondylosis⁽¹⁾. These presentations may occur because of cervical disc degeneration, nerve root compression, and cervical spinal cord compression (myelopathy). One, two, or all of these presentations may be observed together in patients⁽²⁾. Characteristic symptoms include gait and balance disturbance, ataxia, decreased manual dexterity, dysesthesia, and difficulty in writing. It is the most common cause of spinal cord dysfunction in the adult population⁽³⁾. In the cervical region, the canal diameter between C3 and C7 is 17-18 mm and the cervical cord diameter between C1 and C7 is 10 mm. CSM findings develop when the sagittal diameter is 12 mm or less⁽⁴⁾. The disease usually progresses with symptoms and signs related to spinal cord compression. Atrophy and weakness in small muscles of the hands are common in the late stage. In the lower extremities, spastic gait, hyperreflexia, and Babinski symptoms are typical^(4,5).

The main factors considered for treating CSM are the time of onset of clinical symptoms, the rate of progression, and the

degree of neurologic damage. The aim of surgery is to correct neurological damage and stop the progression of the disease⁽⁶⁻⁸⁾. Various surgical methods have been used to date, such as laminectomy and corpectomy. Alternatively, to reduce the complications of laminectomy and corpectomy, Hirabayashi et al.⁽⁹⁾ described the open-door laminoplasty method in 1977 to widen the narrowed cervical canal. Later, different laminoplasty techniques were developed. The most commonly used method today is hardware-augmented Hirabayashi's open-door laminoplasty⁽¹⁰⁾. En-bloc C3-7 laminoplasty was described by Itoh and Tsuji⁽¹¹⁾. It was adopted by Hosono et al.⁽¹²⁾. Turturk et al.⁽⁸⁾ popularized C3-6 en-bloc laminoplasty to prevent axial neck pain and loss of lordosis by preserving the posterior ligamentous structure such as interspinous and supraspinous ligaments. They also recommend preservation of the nuchal ligament attached to the C7 spinous process. If C6-7 levels are affected, they recommend C7 arcocristectomy⁽⁸⁾. There is controversy regarding the various techniques that provide the best clinical outcome with the fewest complications⁽¹³⁾.

In this study, we evaluated the results of en-bloc C3-6 laminoplasty to prevent axial neck pain and loss of lordosis by preserving the posterior ligamentous structure.

Address for Correspondence: Rahmi Kemal Koç, Erciyes University Faculty of Medicine, Department of Neurosurgery, Kayseri, Turkey

Phone: +90 352 222 41 42 **E-mail:** kocrk@erciyes.edu.tr **Received:** 05.01.2024 **Accepted:** 17.03.2024

ORCID ID: orcid.org/0000-0001-9928-0468



MATERIALS AND METHODS

This study was retrospective. In this study, we analyzed the preoperative and postoperative results of 32 patients who underwent en-bloc cervical laminoplasty for CSM in our clinic between 2008 and 2022. The preoperative symptom duration was divided into three categories. Those who underwent surgery in the first 6 months, 6-18 months and after 18 months. The modified Japanese Orthopedic Association (mJOA) score⁽¹⁴⁾ and Nurick scale⁽¹⁵⁾ were used for functional and neurological evaluation. In the mJOA score, upper extremity, lower extremity, and trunk motor dysfunction, sensory loss, and sphincter dysfunction are evaluated in separate categories, and the full score is 18⁽¹⁶⁾. Patients were divided into three groups according to their mJOA scores. Fifteen and above, between 12-14, and below 12. The postoperative recovery rate was calculated using the Hirabayashi et al.⁽⁹⁾ method. Recovery rate (%)=(postoperative JOA-preoperative JOA)/(18-preoperative JOA)×100⁽⁴⁾. In the Nurick scale, each patient was assigned one of six grades of disability (0-5), based on the degree of difficulty in walking recorded at the time of admission. All patients in our series underwent surgery using the hardware-augmented en-bloc laminoplasty technique^(8,17). One side of the lamina is cut using a high-speed drill. On the other hand, only the outer cortex is cut and the inner cortex of the inner lamina is left untouched. The lamina is then lifted using small angled currents. The

ligamentum flavum, interspinous, and supraspinous ligaments are preserved. The lifted lamina was then fixed with mini plates (Figure 1). This study was approved by the institutional ethics committee of Erciyes University Clinical Research Ethics Committee (approval number: 2023/298, date: 26.04.2023).

Statistical Analysis

The data were recorded using SPSS 22 software and analyzed using the same program. Frequency, percentage, mean value, standard deviation, and highest and lowest (min.-max.) values were used for descriptive statistics. For statistical analysis of categorical data, Fisher's exact test was applied because there were fewer than five values. The Shapiro-Wilk test was used to check the suitability of the data for normal distribution. The One-Way Analysis of Variance test was used for statistical analysis of quantitative data in independent groups. Spearman's correlation coefficient was used to show the relationship between the variables. The statistical significance of the difference was set as $p < 0.05$.

RESULTS

The mean age of the patients was 66.3 ± 8.5 (min.-max.: 52-88) years. Twenty-one patients were male (65.6%) and 11 patients were female (34.4%), and the mean follow-up period was 34.7 ± 8.8 (min.-max.: 18-52) months. Three patients had single levels, six had two levels, 10 had three levels, and 13 had four levels of spinal stenosis.

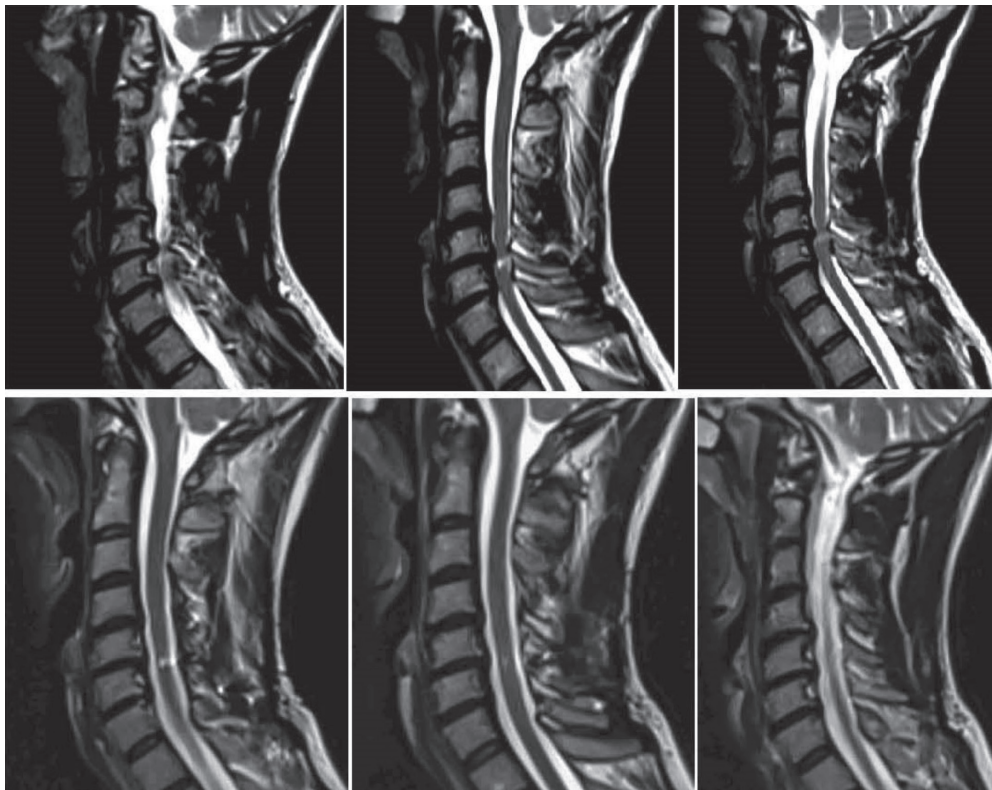


Figure 1. MR images before and after surgery (en-bloc laminoplasty technique) for cervical spondylotic myelopathy
 MR: Magnetic resonance

Half of the patients were in the group with symptom duration of 6-18 months. The frequency of symptom durations and recovery rates are presented in Table 1. Although there was no significant correlation between symptom duration and complete recovery ($p>0.05$), complete recovery rates were higher in patients with symptoms lasting 6 months (Table 1).

The mJOA scores of patients with a symptom duration of 6 months were significantly higher, whereas the mJOA scores of patients with increasing symptom duration also decreased (Table 2).

Seven of 8 patients with mJOA scores of 15 had complete recovery and 1 had partial recovery. Of the 10 patients with mJOA scores between 12 and 15, 7 showed improvement above 15 points and 3 showed partial improvement. Of the 14 patients with a score below 12, 10 improved to the 12-15 range, whereas 3 had no change. Worsening was observed in one patient. Recovery rates according to the mJOA score are given in Table 3. Although there was no significant difference between the groups in terms of recovery rates, recovery rates were higher in the group with an mJOA score of 15 and above. It was observed that the worse the preoperative mJOA value of the patients, the lower the success rate of the operation (Table 3).

The Nurick scores of the patients are given in Table 4. Complete recovery rates were significantly higher in patients with Nurick

grades 0, 1, and 2 ($p<0.05$). Complete recovery was not observed in patients with grades 3 and 4 (Table 4). Nurick grades were also correlated with the mJOA scale at postoperative neurologic follow-up compared with preoperative results.

In our series, axial/radicular pain was relieved in 91% of patients, decreased in 6%, and unchanged in 3%. Sensory deficits were relieved in 35%, decreased in 45%, and unchanged in 20%. Improvement in the complaints of patients with sensory loss started after the 6th month, and sensory loss was permanent in three patients. The motor losses of patients improved good in 18%, fair in 54%, unchanged in 22%, and worsened in 6% after surgery.

The number of operated levels had no effect on functional follow-ups for the mJOA scale and Nurick grade. No complications occurred requiring reoperation, such as cerebrospinal fluid leakage, wound infection, bleeding, or plate-screw malposition, during follow-up.

DISCUSSION

When planning treatment for CSM, the severity of neurologic involvement, the rate of disease progression, and the duration of symptoms are essential in deciding the treatment method; however, it is difficult to determine the treatment strategy⁽⁷⁾. Impairment in neurological functions may vary from mild to severe. The mJOA score⁽¹⁵⁾ and Nurick grade⁽¹⁶⁾ are most commonly used in neurologic functional assessment. Patients with an mJOA score above 15 points are considered mildly affected. They have impaired fine motor movements due to loss and dysfunction of intrinsic muscles in the hands and complaints of numbness and clumsiness due to accompanying sensory loss. Patients with mJOA scores of 12-15 are considered moderately affected and have a wide-based gait or loss of balance due to rigidity. Findings such as hyperreflexia, clonus, positive Babinski sign, and positive Romberg test are usually present. Patients who are considered severely disabled (mJOA score below 12) have a severe need for assistance and loss of urinary control in addition to the previously mentioned findings⁽¹⁸⁾. In the presence of CSM in the narrow canal, the functional neurological picture at presentation may also vary according to the etiology. Again, most patients without pathologic signal change on magnetic resonance imaging are in the mild myelopathic group⁽¹⁸⁾. Late findings of atrophy and fasciculations in the distal upper extremity and sphincter dysfunction are signs of poor recovery prognosis⁽¹⁹⁾. It has been observed that 18% of patients with CSM recover spontaneously, 40% are stable, and 40% may worsen without treatment. Intensive conservative treatment has also been reported to give successful results⁽²⁰⁾. Cervical traction, cervical immobilization, and other physical therapy agents can be used in conservative treatment, but studies on these agents are insufficient⁽²¹⁾. A short symptom duration increases the success of surgical treatment. It has been reported that surgery performed within the first 18 months from the onset of symptoms gives more successful results⁽²²⁾.

Table 1. Duration of symptoms and complete recovery rates

Symptom durations	Patients		Full recovery		p-value
	n	%	n	%	
<6 months	7	21.9	6	85.7	0.765
6-18 months	16	50.0	12	75.0	
>18 months	9	28.1	6	66.7	

Fisher's exact test, n: Patient count

Table 2. Symptom duration and mJOA scores

mJOA scores	Symptom durations						p-value
	<6 months		6-18 months		>18 months		
	n	%*	n	%*	n	%*	
>15	7	100.0	0	0.0	0	0.0	<0.001
12-14	1	6.3	10	62.5	5	31.3	
<12	0	0.0	0	0.0	9	100.0	

Fisher's exact test, *: Row percentage, mJOA: Modified Japanese Orthopedic Association, n: Patient count

Table 3. mJOA score and recovery rates

mJOA scores	Patients		Full recovery		p-value
	n	%*	n	%**	
>15	8	25.0	7	87.5	0.764
12-14	10	31.3	7	70.0	
<12	14	43.8	10	71.4	

Fisher's exact test, *: Column percentage, **: Row percentage, mJOA: Modified Japanese Orthopedic Association, n: Patient count

Table 4. Nurick grades and recovery rates of patients

Nurick grades	Recovery							
	Patients		Full recovery		No complete recovery		mJOA scores	
	n	%*	n	%**	n	%**	Mean	SD
Grade 0	11	34.4	9	81.8	2	18.2	14.5	1.9
Grade 1	12	37.5	10	83.3	2	16.7	12.2	1.7
Grade 2	5	15.6	5	100.0	0	0.0	10.4	0.5
Grade 3	3	9.4	0	0.0	3	100.0	9.3	0.6
Grade 4	1	3.1	0	0.0	1	100.0	8	-
p-value			0.009 ^a				<0.001 ^b	

*: Column percentage, **: Row percentage, ^a: Fisher's exact test, ^b: One-Way Analysis of Variance, SD: Standard deviation, n: Patient count

Surgical treatment should be preferred in patients with a moderate or severe involvement (mJOA) score of 10 or less⁽¹⁶⁾. Arnasson et al.⁽²³⁾ reported a 69% improvement with posterior surgical intervention in their study and that the results were not related to the patient's age and symptom duration. The main aim of surgical treatment is to stop the progression of deterioration in neurological functions and correct neurological loss^(6,8). The goals of surgical treatment of CSM include decompression of the spinal cord, prevention of cervical instability, and restoration of cervical lordotic alignment^(24,25). Various surgical approaches have been developed to treat CSM. However, there is controversy regarding which surgery provides the best clinical results with the least complications. Factors such as the site of compression, length of the compression level, canal compression ratio, age of the patient, cervical alignment (lordotic, kyphotic, or straight), bone quality, and presence of instability should be considered when choosing the appropriate approach in surgically planned cases⁽¹²⁾. The surgical approach can be performed as an anterior approach, posterior approach, or combined anterior and posterior approach⁽¹⁶⁾.

The use of laminoplasty in cervical myelopathy was first described by Krita in 1968⁽²⁶⁾. Cervical laminoplasty was developed in Japan in the 1970s and became popular after the 1980s. There are different laminoplasty techniques. One important consideration is to preserve the structure of the nuchal ligaments attaching to the C7 spinous processes to prevent neck pain. Preservation of the attachment site of the erector spinae muscles to C2 is important for preventing kyphotic deformity^(18,27,28). It has also been reported that the exclusion of C7 in laminoplasty has a positive effect on axial pain in the postoperative period⁽⁸⁾. Tumturk et al.⁽⁸⁾ suggested that en-bloc cervical laminoplasty while preserving posterior structures such as interspinous and supraspinous ligaments is useful in preventing postoperative spinal malalignment and axial pain. Arcocristectomy is an effective technique for preventing postoperative axial pain in patients with C6-7 spinal stenosis. Therefore, the en-bloc laminoplasty technique was used in our study.

Arnasson et al.⁽²³⁾ reported a 69% improvement with posterior surgical intervention in these cases and stated that the results

were not related to the patient's age or symptom duration. Wang et al.⁽²²⁾ suggested that the patient's age over 50 years was not effective in recovery. The researchers reported that surgery performed within the first 18 months from the onset of symptoms gave more successful results, and the recovery rate was 35% with conservative treatment and 43% with surgical treatment⁽²²⁾. In our series, as the preoperative symptom duration of the patients was prolonged, the success rate in treatment decreased. The best recovery rate was found in patients operated on within the first 6 months (recovery rate 91%), and the worst recovery rate was found in patients with a symptom duration longer than 18 months (69%). Again in this study, the worse the mJOA score, the lower the postoperative success rate (mJOA 15 and above-91.8%, mJOA 12 to 15-82.5%, mJOA below 12 and lower 73.0%). Evaluation according to Nurick's test was also correlated with mJOA. In our series, a patient with an mJOA score of 8 had worsening neurological status after surgery. We believe that a preoperative symptom duration of approximately 2 years and an mJOA score of 8 were effective in this worsening.

CONCLUSION

In our study, low mJOA scores, high Nurick grades, and long preoperative symptom duration were found to negatively affect the results of en-bloc cervical laminoplasty for CSM. We believe that this situation should be considered when planning the treatment. We believe that further studies in larger series will be useful in this regard.

Ethics

Ethics Committee Approval: This study was approved by the institutional ethics committee of Erciyes University Clinical Research Ethics Committee (approval number: 2023/298, date: 26.04.2023).

Informed Consent: This study was retrospective.

Authorship Contributions

Surgical and Medical Practices: M.M., R.K.K., Concept: M.M., R.K.K., Design: M.M., Data Collection or Processing: M.M., Analysis or Interpretation: M.M., R.K.K., Literature Search: M.M., Writing: M.M.

Conflict of Interest: The authors have no conflicts of interest to declare.

Financial Disclosure: The authors declared that this study received no financial support.

REFERENCES

1. Fehlings MG, Skaf G. A review of the pathophysiology of cervical spondylotic myelopathy with insights for potential novel mechanisms drawn from traumatic spinal cord injury. *Spine (Phila Pa 1976)*. 1998;23:2730-7.
2. Clark CR. Differential diagnosis and non-operative management. *The Adult Spine: Principles and Practice*. Philadelphia: Lippincott-Raven Publishers. 1997:1323-47.
3. Şahin A, Küçük A, Dağtekin A, Koç RK. Posterior surgical techniques in cervical spondylotic myelopathy. *Türk Nöroşir Derg*. 2022;32:435-49.
4. Collias Roberts PR. Posterior surgical exposures for cervical disc herniation and spondylotic myelopathy. In: *Operative neurosurgical techniques. Indications, methods, and results*. Schmiedek HH, WB Saunders Eds. Philadelphia 1995;1805-16.
5. Dagi TF, Tarkington MA, Leech JJ. Tandem lumbar and cervical spinal stenosis. Natural history, prognostic indices, and results after surgical decompression. *J Neurosurg*. 1987;66:842-9.
6. Goh BC, Striano BM, Lopez WY, Upadhyaya S, et al. Laminoplasty versus laminectomy and fusion for cervical spondylotic myelopathy: a cost analysis. *The Spine Journal : Official Journal of the North American Spine Society*. 2020;20:1770-5.
7. Şahin N, Berker E. A Late diagnosed cervical myelopathy case. *Turk J Phys Med Rehab*. 2006;52:42-7.
8. Tumturk A, Kucuk A, Menku A, Koc RK. En bloc cervical laminoplasty while preserving the posterior structure with arcocristectomy in cervical spondylotic myelopathy. *Turk Neurosurg*. 2017;27:790-6.
9. Hirabayashi K, Miyakawa J, Satomi K, Maruyama T, et al. Operative results and postoperative progression of ossification among patients with ossification of cervical posterior longitudinal ligament. *Spine (Phila Pa 1976)*. 1981;6:354-64.
10. Benglis DM, Guest JD, Wang MY. Clinical feasibility of minimally invasive cervical laminoplasty. *Neurosurg Focus*. 2008;25:E3.
11. Itoh T, Tsuji H. Technical improvements and results of laminoplasty for compressive myelopathy in the cervical spine. *Spine (Phila Pa 1976)*. 1985;10:729-36.
12. Hosono N, Sakaura H, Mukai Y, Ishii T, et al. En bloc laminoplasty without dissection of paraspinal muscles. *J Neurosurg Spine*. 2005;3:29-33.
13. Yağlı ÖE, Temiz C. Deciding on the surgical approach in cervical spondylotic myelopathy. *Türk Nöroşir Derg*. 2018;28:165-70.
14. Benzel EC, Lancon J, Kesterson L, Hadden T. Cervical laminectomy and dentate ligament section for cervical spondylotic myelopathy. *J Spinal Disord*. 1991;4:286-95.
15. Nurick S. The pathogenesis of the spinal cord disorder associated with cervical spondylosis. *Brain*. 1972;95:87-100.
16. O'Duffy JD. Spinal stenosis, development of the lesion, clinical classification, and presentation. *The adult spine: principles and practice* 2nd edition. Philadelphia: Lippincott-Raven Publishers. 1997;719-69.
17. Sakaura H, Hosono N, Mukai Y, Oshima K, et al. Preservation of the nuchal ligament plays an important role in preventing unfavorable radiologic changes after laminoplasty. *J Spinal Disord Tech*. 2008;21:338-43.
18. Nouri A, Martin AR, Tetreault L, Nater A, et al. MRI analysis of the combined prospectively collected aospine north america and international data: the prevalence and spectrum of pathologies in a global cohort of patients with degenerative cervical myelopathy. *Spine (Phila Pa 1976)*. 2017;42:1058-67.
19. Shedid D, Benzel EC. Cervical spondylosis anatomy: pathophysiology and biomechanics. *Neurosurgery*. 2007;60:S7-13.
20. Yoshimatsu H, Nagata K, Goto H, Sonoda K, et al. Conservative treatment for cervical spondylotic myelopathy. Prediction of treatment effects by multivariate analysis. *Spine J*. 2001;1:269-73.
21. Young WF. Cervical spondylotic myelopathy: a common cause of spinal cord dysfunction in older persons. *Am Fam Physician*. 2000;62:1064-70.
22. Wang YL, Tsau JC, Huang MH. The prognosis of patients with cervical spondylotic myelopathy. *Kaohsiung J Med Sci*. 1997;13:425-31.
23. Arnasson O, Carlsson CA, Pellettieri L. Surgical and conservative treatment of cervical spondylotic radiculopathy and myelopathy. *Acta Neurochir (Wien)*. 1987;84:48-53.
24. Iyer A, Azad TD, Tharin S. Cervical spondylotic myelopathy. *Clin Spine Surg*. 2016;29:408-14.
25. Lawrence BD, Shamji MF, Traynelis VC, Yoon ST, et al. Surgical management of degenerative cervical myelopathy: a consensus statement. *Spine (Phila Pa 1976)*. 2013;38:S171-2.
26. Herkowitz HN. A comparison of anterior cervical fusion, cervical laminectomy, and cervical laminoplasty for the surgical management of multiple level spondylotic radiculopathy. *Spine (Phila Pa 1976)*. 1988;13:774-80.
27. Liu J, Ebraheim NA, Sanford CG Jr, Patil V, et al. Preservation of the spinous process-ligament-muscle complex to prevent kyphotic deformity following laminoplasty. *Spine J*. 2007;7:159-64.
28. Takeuchi T, Shono Y. Importance of preserving the C7 spinous process and attached nuchal ligament in French-door laminoplasty to reduce postoperative axial symptoms. *Eur Spine J*. 2007;16:1417-22.