

DURAL FIBROSIS IN SPINAL SURGERY: COMPARISON OF LIGAMENTUM FLAVUM SPARING AND ANTI-ADHESION GEL USE TECHNIQUE

© Mehdi Hekimoğlu¹, © Hıdır Özer²

¹American Hospital, Clinic of Neurosurgery, İstanbul, Turkey

²Ordu University Faculty of Medicine, Department of Neurosurgery, İstanbul, Turkey

ABSTRACT

Objective: Fibrosis around the dura is a concern in spinal surgery, affecting outcomes. Ligamentum flavum (LF) sparing and anti-adhesion barrier gel are potential strategies. This study aimed to compare LF-sparing and anti-adhesion barrier gels in reducing dural fibrosis in spinal surgery patients.

Materials and Methods: Fifty patients underwent surgery at the thoracic/lumbar levels (T1 to S1). Twenty five received LF sparing and 25 received anti-adhesion barrier gels. Postoperative magnetic resonance imaging was performed 6 months post-surgery, using Ross classification for fibrosis assessment. Median fibrosis degree was computed, and surgical levels' impact on fibrosis was analyzed.

Results: The anti-adhesion barrier gel group had a higher mean age (53.68±7.54) than the LF-sparing group (48.36±8.03) ($p<0.05$, t-test). Gender distribution showed no significant difference ($p=0.777$, Chi-square test). The LF-sparing group had a lower mean degree of fibrosis (1.091.09±0.16) than the anti-adhesion barrier gel group (2.28±0.53) ($p<0.001$, Mann-Whitney U test). The LF sparing group's mean fibrosis had no significant variance among spinal levels ($p>0.05$), while the anti-adhesion barrier gel group showed significant differences ($p=0.004$, $p<0.01$) with the highest fibrosis at L4-S1, followed by T12-L1 and L2-L3, and the lowest at T1-T11.

Conclusion: LF sparing is more effective in reducing dural fibrosis than anti-adhesion barrier gel. Surgical level influence fibrosis, with LF sparing advantageous in the lower lumbar and thoracolumbar transitional zones.

Keywords: Ligamentum flavum sparing, anti-adhesion gels, postoperative fibrosis, hypermobility

INTRODUCTION

Spinal surgery is a common procedure for treating a variety of spinal disorders, including herniated discs, spinal stenosis, and spinal fractures. While the benefits of spinal surgery are well-established, the procedure also carries a risk of complications, including fibrosis around the dura. Fibrosis around the dura refers to the formation of scar tissue around the dura mater, which is the protective layer surrounding the spinal cord. This scar tissue can lead to nerve root compression, chronic pain, and other complications that can negatively impact patient outcomes.

To mitigate the risk of fibrosis around the dura, several techniques have been proposed, including ligamentum flavum (LF) sparing and the use of anti-adhesion barrier gels. The LF is a ligament located in the posterior spinal canal that is intimately associated with the dura mater. During spinal surgery, the LF can be thinned or completely removed to reduce the risk of fibrosis around the dura. Anti-adhesion barrier gels, on the other hand, are used to create a physical barrier between the

dura mater and surrounding tissue, preventing the formation of scar tissue.

While both techniques have been shown to be effective in reducing the incidence of fibrosis around the dura, it is unclear which technique is more effective. Previous studies have reported conflicting results, with some studies suggesting that LF sparing is more effective than anti-adhesion barrier gel use, while others have found the opposite to be true⁽¹⁻⁴⁾. The purpose of this study is to compare the degree of fibrosis around the dura in patients undergoing spinal surgery with LF-sparing and anti-adhesion barrier gel use. By comparing the degree of fibrosis in these two groups, we can gain insight into the effectiveness of these techniques and potentially identify the best approach for reducing the incidence of fibrosis around the dura in spinal surgery patients.

MATERIALS AND METHODS

The study was conducted between 2019 and 2022. A total of 50 patients were included in the study, with 25 patients undergoing LF sparing and 25 patients receiving anti-adhesion

Address for Correspondence: Mehdi Hekimoğlu, American Hospital, Clinic of Neurosurgery, İstanbul, Turkey

Phone: +90 212 311 20 00 **E-mail:** mehdi@amerikanhastanesi.org **Received:** 31.08.2023 **Accepted:** 18.10.2023

ORCID ID: orcid.org/0000-0002-1182-2216



© Copyright 2024 The Author. Published by Galenos Publishing House on behalf of Turkish Spine Society.

This is an open access article under the Creative Commons Attribution-NonCommercial-NoDerivatives 4.0 (CC BY-NC-ND) International License.



barrier gels during surgery. All patients underwent spinal surgery in the thoracic and lumbar region between T1 and S1 levels. Informed consent was obtained from our patients for our study. Institutional review board approval was obtained from the Ordu University Ethics Committee (approval number: 2023/167, date: 09.06.2023). In the ligament flavum sparing group, the ligament flavum was thinned and spared during surgery, while in the anti-adhesion barrier gel group, LF was totally removed and an anti-adhesion barrier gel was used to prevent adhesion formation. To provide detailed information on the degree of fibrosis in each patient, we evaluated the T1 and T2-weighted contrast-enhanced magnetic resonance imaging (MRI) assessments in relation to the extent of epidural fibrosis across five consecutive axial sections centered on the operated level. These sections were divided into four quadrants, with perpendicular lines drawn from the central aspect of the thecal sac as a reference. We graded the extent of fibrosis in each quadrant on a scale of 0 to 4, following Ross et al.'s⁽⁵⁾ system. Grade 0 indicated no or minimal fibrosis, while Grade 4 indicated extensive fibrosis filling the quadrant. Fibrosis grades were recorded for each patient, considering four quadrants per section across the five sections. The median grade observed was used to determine the patient's scarring grade. The patient characteristics, including age, sex, and surgical levels, were also recorded for each patient. To investigate whether the degree of fibrosis is influenced by the surgical level in addition to the applied surgical technique, we divided the patients into four groups based on the level of surgery: upper thoracic (T1-T11), transitional zone (T12-L1), upper lumbar (L2-L3), and lower lumbar (L4-S1). The statistics for each level were calculated separately.

Statistical Analysis

The data were analyzed using SPSS version 27.0. Descriptive data were expressed in mean ± standard deviation (SD), median (minimum-maximum) or number and frequency. The Shapiro-Wilk test was used to check normality of distribution of quantitative variables. The independent samples t-test was used to compare normally distributed quantitative variables, while the Mann-Whitney U test was used to compare non-normally distributed quantitative variables between the groups. Kruskal-Wallis test was used for the between group comparisons of parameters without normal distribution. Chi-square test was used to compare qualitative variables. A p-value less than 0.05 were considered statistically significant.

RESULTS

In a total of 50 cases; including 50% (n=25) female and 50% (n=25) male, the ages of the cases ranged from 35 to 68, with a median age of 50.0 and a mean age of 51.02±8.16 years. The mean degree of fibrosis ranged from 0.8 to 3.2, with a median value of 1.4 and a mean value of 1.69±0.71 (Table 1). In addition, the mean age was significantly higher in the anti-adhesion

barrier gel group (mean=53.68, SD=7.54) compared to the LF sparing group (mean=48.36, SD=8.03) (p<0.05, t-test). There was no statistically significant difference in sex (p=0.777, chi-square test) between the two groups (Table 2).

The degree of fibrosis was significantly lower in the LF-sparing group (mean=1.09, SD=0.16) compared to the anti-adhesion barrier gel group (mean=2.28, SD=0.53) (p<0.001, Mann-Whitney U test). The difference in mean fibrosis between the two groups was statistically significant (Table 2) (Figure 1).

There was no statistically significant difference observed in the mean degree of fibrosis measurements among the spinal levels in the Ligament Flavum Sparing group (p>0.05), and in all levels, the degree of fibrosis was lower (Table 3). However, in the Anti-Adhesion Barrier Gel Use group, a statistically significant difference was found in the mean degree of fibrosis measurements among the spinal levels (p=0.004; p<0.01). The highest mean degree of fibrosis was observed in the L4-S1 (Lower Lumbar) level, followed by the T12-L1 (Transitional Zone) and L2-L3 (Upper Lumbar) levels. The lowest mean degree of fibrosis was found in the T1-T11 (Upper Thoracic) level (Table 4) (Figure 2).

DISCUSSION

The LF is a thin, fibrous band that helps to maintain spinal stability and runs between adjacent vertebrae. LF serves as an important barrier against connective tissue formation on the dura after surgery^(5,6). During spinal surgery, the LF is often removed to access the spinal cord and other structures. However, recent studies have shown that preserving the LF during surgery can reduce the extent of fibrosis and improve surgical outcomes^(7,8).

The present study investigated the degree of fibrosis around the dura in patients undergoing spinal surgery with ligament flavum sparing and anti-adhesion barrier gel use. Our results showed that the degree of fibrosis was significantly lower in the ligament flavum sparing group compared to the anti-adhesion barrier gel group, indicating that the use of ligament flavum sparing technique during spinal surgery may better reduce the degree of fibrosis around the dura.

These findings are in line with previous studies that have shown the benefits of LF sparing in reducing postoperative fibrosis and improving surgical outcomes^(9,10). Some studies have demonstrated that patients who underwent surgery

Table 1. Distribution of descriptive characteristics

	Min.-max. (Median)	Mean ± SD	
Age (year)	35-68 (50.0)	51.02±8.16	
Mean degree of fibrosis	0.8-3.2 (1.4)	1.69±0.71	
	n	%	
Gender	Female	25	50.0
	Male	25	50.0

SD: Standard deviation, Min.-max.: Minimum-maximum

with LF preservation had a significantly lower incidence of postoperative fibrosis and lower back pain compared to those who underwent surgery without LF preservation^(11,12).

On the other hand, there have been some conflicting findings in the literature regarding the effectiveness of anti-adhesion barrier gel in reducing fibrosis^(13,14). The use of anti-adhesion barrier gel significantly showed that can reduce the incidence of postoperative fibrosis compared to the control group, suggesting that it can also be effective in reducing the degree of fibrosis around the dura⁽¹⁵⁾.

Several techniques have been described for reducing postoperative fibrosis. A systematic review and meta-analysis by Hosseini et al.⁽¹⁶⁾ found that the use of anti-adhesion barrier gel was effective in reducing epidural fibrosis. Another study also recommended one-day adhesiolysis to reduce the extent of epidural fibrosis with a significant success rate⁽¹⁷⁾.

Wang et al.⁽¹⁸⁾ evaluated the use of cross-linked hyaluronic acid gel in reducing epidural fibrosis after lumbar discectomy. Cross-linked hyaluronic acid gel was found to prevent epidural adhesion by inhibiting inflammatory factors and downregulating the expression of TGFβ1 and COL1A1 mRNA, as demonstrated through *in vivo* and *in vitro* studies. This suggests that the use of an anti-adhesion barrier gel may have additional benefits beyond reducing fibrosis^(18,19).

Various views have been proposed as to why connective tissue forms. Connective tissue formation may be a result of instability with age, sex, comorbidities, and axial predicates⁽²⁰⁻²²⁾. Removal of the developing connective tissue may cause new adhesions, and its removal with a second operation poses a major problem, especially because of nerve damage and dural opening^(23,24). Various suggestions on how to prevent connective tissue development have been reported. Among them are good control of wound bleeding, use of adhesion barriers agents, and recently, use of antifibrotic drugs^(4,20,25,26). However, the most effective method is LF preservation. This structure has an important role in the biomechanics of the spinal region. It helps stabilizes of the spinal column and prevents hypermobility by protecting the range of motion. It also supports elasticity and stability by being among the spinal posterior column elements. Recent studies have shown that preserving the LF during spinal surgery can help maintain the biomechanical stability of the spine and reduce the risk of complications such as hypermobility and adjacent segment degeneration. While preserving the LF

may help maintain spinal stability, there is limited evidence to suggest that it can reduce the risk of hypermobility specifically. However, preserving the LF can help maintain the integrity of the posterior spinal ligaments and reduce the risk of iatrogenic injury to these structures, which can lead to instability and hypermobility. Additionally, preserving the LF may help maintain the biomechanical function of the spinal column, which can contribute to overall spinal stability^(8,27,28).

Also, we identified a significant relationship between the type of surgical technique used, the level of spinal surgery, and the degree of fibrosis. In the case of using the anti-adhesion barrier gel, higher degrees of fibrosis were observed in the hypermobile spine regions, specifically the lower lumbar region and thoracolumbar transitional zone. This suggests that better control of fibrosis development, especially in hypermobile regions, can be achieved through the preservation of the LF. These findings are consistent with previous studies reporting higher degrees of fibrosis in the hypermobile region or in the presence of instability. Thoracic and lumbar and lumbosacral regions of the spine are subject to different biomechanical stresses compared to other spinal levels, which might influence the healing process and the development of fibrosis. Additionally, hypermobility itself can contribute to the formation of fibrosis. Excessive movement in the spinal

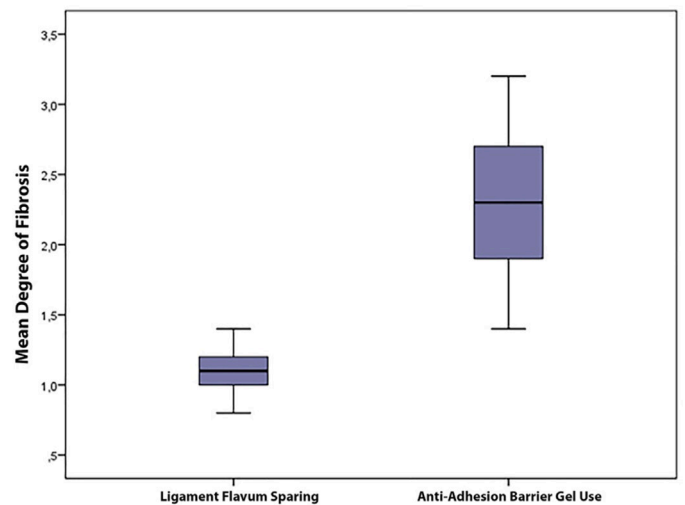


Figure 1. Distribution of mean degree of fibrosis levels by groups

Table 2. Evaluation of variables by groups

		Ligament flavum sparing	Anti-adhesion barrier gel use	p-value
Age (year)	Mean ± SD	48.36±8.03	53.68±7.54	^a 0.020*
	Median (Min.-max.)	48 (35-63)	54 (41-68)	
Sex; n (%)	Female	12 (48.0)	13 (52.0)	^b 0.777
	Male	13 (52.0)	12 (48.0)	
Mean degree of fibrosis	Mean ± SD	1.09±0.16	2.28±0.53	^c 0.001**
	Median (Min.-max.)	1.1 (0.8-1.4)	2.3 (1.4-3.2)	

^aStudent's t-test, ^bChi-square test, ^cMann-Whitney U test, *p<0.05, **p<0.01, SD: Standard deviation, Min.-max.: Minimum-maximum

segment can disrupt the delicate balance of tissue healing and increase the deposition of scar tissue. This can result in the formation of fibrotic adhesions around the spinal structures, including the epidural space^(29,30).

The present study has some limitations, including a relatively small sample size and a lack of long-term follow-up data.

Table 3. Evaluation of mean degree of fibrosis among the spinal levels in the ligament flavum sparing group, (n=25)

Spinal level	Mean degree of fibrosis		p-value
	Mean ± SD	Median (Min.-max.)	
L2-L3 (Upper lumbar)	1.10±1.73	1.2 (0.9-1.2)	0.660
L4-S1 (Lower lumbar)	1.16±0.11	1.2 (1-1.3)	
T1-T11 (Upper thoracic)	1.04±0.18	1 (0.8-1.3)	
T12-L1 (Transitional zone)	1.11±0.18	1.1 (0.9-1.4)	

Kruskal-Wallis test, Bold value is not significant at the mentioned level of spine, SD: Standard deviation, Min.-max.: Minimum-maximum

Table 4. Evaluation of mean degree of fibrosis among the spinal levels in the anti-adhesion barrier gel use group (n=25)

Spinal level	Mean degree of fibrosis		p-value
	Mean ± SD	Median (Min.-max.)	
L2-L3 (Upper lumbar)	1.94±0.11	1.9 (1.8-2.1)	0.004**
L4-S1 (Lower lumbar)	2.72±0.31	2.65 (2.3-3.2)	
T1-T11 (Upper thoracic)	1.76±0.36	1.6 (1.4-3.2)	
T12-L1 (Transitional zone)	2.28±0.58	2.60 (1.6-2.8)	

Kruskal-Wallis test, **p<0.01, SD: Standard deviation, Min.-max.: Minimum-maximum

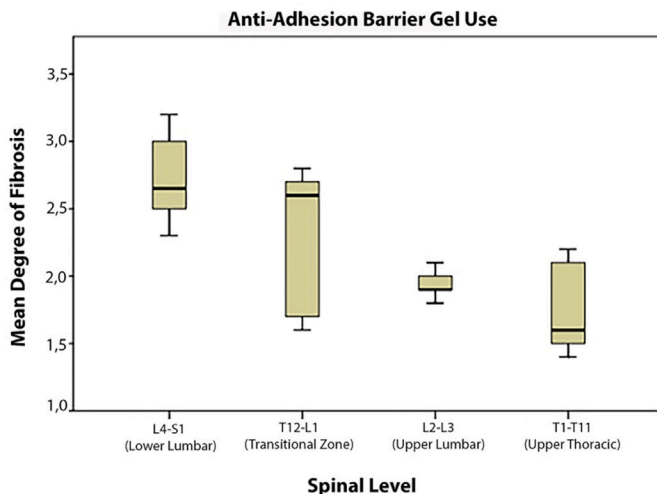


Figure 2. Distribution of mean degree of fibrosis levels in the anti-adhesion barrier gel use group by spinal level

However, further studies are required to identify the most effective strategies for preventing fibrosis, to determine the long-term effects of different surgical techniques on fibrosis and clinical outcomes in larger patient populations

In brief, minimizing fibrosis formation is crucial in achieving successful spinal surgery outcomes, and recent literature suggests that the preservation of the LF and the use of minimally invasive surgical techniques may help reduce the extent of fibrosis and adhesion formation. Our study highlights the importance of using LF preserving technique that can reduce the degree of fibrosis around the dura during spinal surgery, particularly in the lower lumbar and thoracolumbar transitional region.

CONCLUSION

The use of the LF sparing technique can significantly reduce the degree of fibrosis around the dura compared to the use of anti-adhesion barrier gel. This reduction in fibrosis may result in improved patient outcomes and a decreased incidence of nerve root compression and chronic pain. Additionally, the level of surgery plays a crucial role in the development of fibrosis around the dura. To select the most effective surgical techniques for minimizing postoperative fibrosis, it is better to utilize the LF sparing technique rather than anti-adhesion barrier gels, particularly in the lower lumbar region and thoracolumbar transitional zone.

Ethics

Ethics Committee Approval: Institutional review board approval was obtained from the Ordu University Ethics Committee (approval number: 2023/167, date: 09.06.2023).

Informed Consent: Informed consent was obtained from our patients for our study.

Authorship Contributions

Surgical and Medical Practices: M.H., H.Ö., Concept: M.H., Design: M.H., Data Collection or Processing: M.H., H.Ö., Analysis or Interpretation: M.H., Literature Search: M.H., Writing: M.H., H.Ö.

Conflict of Interest: The authors have no conflicts of interest to declare.

Financial Disclosure: The authors declared that this study received no financial support.

REFERENCES

- Geisler FH. Prevention of peridural fibrosis: current methodologies. *Neurol Res.* 1999;21(Suppl 1):S9-22.
- Subach BR, Copay AG. The use of a dehydrated amnion/chorion membrane allograft in patients who subsequently undergo reexploration after posterior lumbar instrumentation. *Adv Orthop.* 2015;2015:501202.
- Petrie JL, Ross JS. Use of ADCON-L to inhibit postoperative peridural fibrosis and related symptoms following lumbar disc surgery: a preliminary report. *Eur Spine J.* 1996;5(Suppl 1):S10-7.



4. Wu L, Xu L, Chen Y, Xu G, Guo Q, Meng D, et al. Rolipram plays an anti-fibrotic effect in ligamentum flavum fibroblasts by inhibiting the activation of ERK1/2. *BMC Musculoskelet Disord.* 2021;22:818.
5. Ross JS, Robertson JT, Frederickson RC, Petrie JL, Obuchowski N, Modic MT, et al. Association between peridural scar and recurrent radicular pain after lumbar discectomy: magnetic resonance evaluation. *ADCON-L European Study Group. Neurosurgery.* 1996;38:855-61; discussion 861-3.
6. Çokluk C, Aydın K, Tümkaya L. Grading of epidural fibrosis in a new rabbit experimental model for epidural adhesive scar tissue formation. *Journal of Experimental and Clinical Medicine (Turkey).* 2009;26:107-11.
7. Olszewski AD, Yaszemski MJ, White AA 3rd. The anatomy of the human lumbar ligamentum flavum. New observations and their surgical importance. *Spine (Phila Pa 1976).* 1996;21:2307-12.
8. Wu CC, Jin HM, Yan YZ, Chen J, Wang K, Wang JL, et al. Biomechanical Role of the Thoracolumbar Ligaments of the Posterior Ligamentous Complex: A Finite Element Study. *World Neurosurg.* 2018;112:e125-33.
9. Song J, Park Y. Ligament-sparing lumbar microdiscectomy: technical note. *Surg Neurol.* 2000;53:592-6; discussion 596-7.
10. Ozer AF, Oktenoglu T, Sasani M, Bozkus H, Canbulat N, Karaarslan E, et al. Preserving the ligamentum flavum in lumbar discectomy: a new technique that prevents scar tissue formation in the first 6 months postsurgery. *Neurosurgery.* 2006;59:ONS126-33; discussion ONS126-33.
11. Li S, Xia H, Han C. Retrospective analysis on correlation factors of preserving the ligamentum flavum in microendoscopic discectomy. *Clin Neurol Neurosurg.* 2015;139:46-50.
12. Özyay R, Ogur T, Durmaz HA, Turkoglu E, Caglar YS, Sekerci Z, et al. Revisiting Ligament-Sparing Lumbar Microdiscectomy: When to Preserve Ligamentum Flavum and How to Evaluate Radiological Results for Epidural Fibrosis. *World Neurosurg.* 2018;114:e378-87.
13. LeHuec JC, Sadikci R, Cogniet A, Rigal J, Demezou H, Aunoble S. Role of a collagen membrane in adhesion prevention strategy for complex spinal surgeries. *Int Orthop.* 2015;39:1383-90.
14. Chaturvedi AA, Lomme RM, Hendriks T, van Goor H. Prevention of postsurgical adhesions using an ultrapure alginate-based gel. *Br J Surg.* 2013;100:904-10.
15. de Tribollet N, Porchet F, Lutz TW, Gratzl O, Brotchi J, van Alphen HA, et al. Clinical assessment of a novel antiadhesion barrier gel: prospective, randomized, multicenter, clinical trial of ADCON-L to inhibit postoperative peridural fibrosis and related symptoms after lumbar discectomy. *Am J Orthop (Belle Mead NJ).* 1998;27:111-20.
16. Hosseini S, Niakan A, Dehghankhalili M, Dehdab R, Shahjouei S, Rekabdar Y, et al. Effects of adhesion barrier gel on functional outcomes of patients with lumbar disc herniation surgery: A systematic review and meta-analysis of clinical trials. *Heliyon.* 2021;7:e07286.
17. Masopust V, Holubová J, Skalický P, Rokyta R, Fricová J, Lacman J, et al. Neuromodulation in the treatment of postoperative epidural fibrosis: comparison of the extent of epidural fibrosis and the effect of stimulation. *Physiol Res.* 2021;70:461-8.
18. Wang K, Li XL, Liu J, Sun X, Yang H, Gao X. Using cross-linked hyaluronic acid gel to prevent postoperative lumbar epidural space adhesion: in vitro and in vivo studies. *Eur Spine J.* 2020;29:129-40.
19. Turkoglu E, Dinc C, Tuncer C, Oktay M, Serbes G, Sekerci Z. Use of decorin to prevent epidural fibrosis in a post-laminectomy rat model. *Eur J Pharmacol.* 2014;724:86-91.
20. Sun C, Zhang H, Wang X, Liu X. Ligamentum flavum fibrosis and hypertrophy: Molecular pathways, cellular mechanisms, and future directions. *FASEB J.* 2020;34:9854-68.
21. Li S, Xia H, Han C. Retrospective analysis on correlation factors of preserving the ligamentum flavum in microendoscopic discectomy. *Clin Neurol Neurosurg.* 2015;139:46-50.
22. Yasargil MG. *Microsurgical operation of herniated lumbar disc. Lumbar Disc Adult Hydrocephalus.* Berlin, Heidelberg: Springer Berlin Heidelberg. 1977;81.
23. Askar Z, Wardlaw D, Choudhary S, Rege A. A ligamentum flavum-preserving approach to the lumbar spinal canal. *Spine (Phila Pa 1976).* 2003;28:E385-90.
24. Tatsui CE, Martinez G, Li X, Pattany P, Levi AD. Evaluation of DuraGen in preventing peridural fibrosis in rabbits. Invited submission from the Joint Section Meeting on Disorders of the Spine and Peripheral Nerves, March 2005. *J Neurosurg Spine.* 2006;4:51-9.
25. Aydın Y, Ziyal IM, Duman H, Türkmen CS, Başak M, Sahin Y. Clinical and radiological results of lumbar microdiscectomy technique with preserving of ligamentum flavum comparing to the standard microdiscectomy technique. *Surg Neurol.* 2002;57:5-13; discussion 13-4.
26. Mastronardi L, Pappagallo M, Tatta C, Roperto R, Elsawaf A, Ferrante L. Prevention of postoperative pain and of epidural fibrosis after lumbar microdiscectomy: pilot study in a series of forty cases treated with epidural vaseline-sterile-oil-morphine compound. *Spine (Phila Pa 1976).* 2008;33:1562-6.
27. Widmer J, Cornaz F, Scheibler G, Spirig JM, Snedeker JG, Farshad M. Biomechanical contribution of spinal structures to stability of the lumbar spine-novel biomechanical insights. *Spine J.* 2020;20:1705-16.
28. Damm N, Rockenfeller R, Gruber K. Lumbar spinal ligament characteristics extracted from stepwise reduction experiments allow for preciser modeling than literature data. *Biomech Model Mechanobiol.* 2020;19:893-910.
29. Bezer M, Gokkus K, Kocaoglu B, Guven O. The influence of vertebral instability on peridural circulation and concomitant peridural fibrosis formation. *Eur Spine J.* 2006;15:959-64.
30. Izzo R, Guarneri G, Guglielmi G, Muto M. Biomechanics of the spine. Part II: spinal instability. *Eur J Radiol.* 2013;82:127-38.