

## INTERNAL FIXATION OF UNSTABLE THORACOLUMBAR FRACTURES WITH St. GEORGE SPINAL PLATES

A. M. Alpaslan \*, G. Leblebicioğlu \*\*, M. Eryılmaz \*\*\*

*Spinal plating with pedicle screw plates is one of the most stable methods of fixation of spinal column fractures. During the period between May 1988 and Feb 1990, twelve patients with thoracic, thoracolumbar and lumbar injuries have been treated with St.George spinal plates. The preoperative and postoperative neurologic findings of these patients have been documented in terms of their functional capacity. In addition to routine preoperative and postoperative plain x-rays, myelographies and CT scannings, we performed sagittal CT scannings postoperatively.*

*We suggest that although spinal plating with pedicle screw plates is a very effective method of spinal stabilization, prebend (and axially rotated) plates are anatomically more filling than St.George plates.*

*Key Words : Spinal Fractures, Pedical Screw Plates, Internal fixation of thoracolumbar fractures, St.George spinal plating.*

Optimal treatment of the fractures of the thoracic and lumbar spine still remains controversial. Several methods of surgical stabilization, although with uncertain assistance on neurologic recovery, provide better anatomic reduction, result in more stability and decrease the rate of long term disability. (1,2) The internal fixation system selected must provide distraction for anterior injuries, compression for posterior injuries, resist bending in unstable injuries and restore normal anatomical spinal configuration. Prompt and complete reduction of the deformity with restoration of the spinal canal integrity and rigid fixation can be expected to assist neurologic recovery.

The spine surgeon, dealing with thoracic, thoracolumbar and lumbar spine fractures is faced with several methods of internal fixation. Prior to 1960's surgical stabilization of the spine was technically limited. The development of Harrington distraction and compression rods has opened a new horizon in the spinal surgery, satisfactorily reducing the angular deformity and restoring vertebral body height.(2) More securely grasping rod and locking hook system provide more stability .(3) Use of Harrington rod with supplemental wire fixation significantly increases stability and strength.(4) Several recently developed pedicle screw systems, in which the flexion bending moment is

transferred to either a plate or rod by the pedicle screws, offer the advantage of internal fixation to a shorter portion of the spine than with hook systems and provide better stabilization. The plate screw system of Roy-Camille involves two vertebra above and two vertebra below. However, the screws are fixed in position along the plate and the angle between the screws and the rod is relatively constrained (5). Wolter states that good seating of the screw heads is accomplished by providing the plates with slotted screw holes having wave-like indentations (20).

In this article, we review our institution's experience with the plate-screw system of St.George in twelve patients with thoracic, thoracolumbar and lumbar fractures.

### MATERIALS AND METHODS

During the period between May 1988 and Feb 1990, twelve patients with thoracic, thoracolumbar and lumbar fractures treated with St.George plates were included in this article. There were nine male and three female patients. Their mean age was twenty nine years (range, eight to thirty-eight years). The mean follow-up was fifteen months (range, five to twenty four months).

Ten patients were injured in an automobile accident and two were in a fall. Five patients had injuries associated with the spinal lesion. These injuries were one hemopneumothorax, two pelvic fractures, one diaphragm rupture requiring laparotomy, one diaphyseal humerus fracture with radial nerve lesion which resolved completely by the postoperative six month, one diaphyseal tibia fracture and an ipsilateral talus fracture, and few other assorted injuries.

---

\* Professor of Orthopaedic Surgery, Department of Orthopaedic Surgery and Traumatology, Hacettepe University Medical School.

\*\* Research Assistant, Department of Orthopaedic Surgery and Traumatology, Hacettepe University, Medical School

\*\*\* Assistant Professor, Department of Radiology, Hacettepe University Medical School.

In one patient a laminotomy and in three patients laminectomies were performed by the neurosurgeons in conjunction with spinal plating.

Eight of the patients were admitted directly to our hospital following injuries and four following their first medical aid at another health centre. Meantime from injury to spinal instrumentation were eleven days (range zero to thirty-two days). All of the operations were performed by the orthopaedic surgeons at our institution. Second lumbar vertebra was the most frequently injured followed by L3 and T8. (Fig 1)

We classified cases treated with St. George spinal plates according to Denis. There were six unstable burst fractures, one flexion distraction injury and five translational injuries.

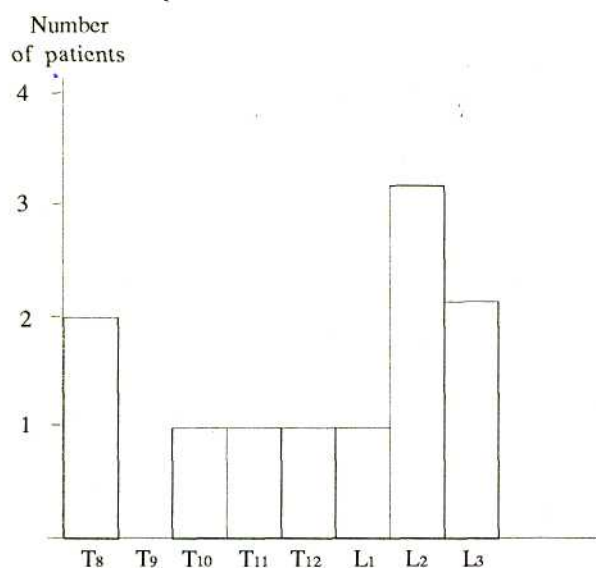


Fig 1 Fracture Levels in the study group of twelve patients.

### Operative Technique

Under general anesthesia, the patients are log-rolled onto the operating table. The chest and pelvis are supported by the rolls. The incision over the spinous processes is made so that the vertebrae bordering two interspaces above and two below the fractured interspace can be exposed. This exposition is made with great care at the injured level. Then the pedicle markers described elsewhere (7) are looked for. At the crossing of the vertical line in the prolongation of the facet joint and the horizontal line passes through the middle of the insertion of the transverse process, the drilling is done perpendicular to the tangential plane of the verte-

bra, straight forward with a 3.2 mm drill. This drilling is done under fluoroscopic monitoring. Then the plates are positioned with the pins through the slotted screw holes to ensure good seating and the pins are replaced by the screws. No facet screws were used. We generally fused the entire area in this group of patients. Closed reductions were performed in this group of patients and we did not use Harrington distraction rods to ensure reduction contrary to Wolters original description (6).

The patient is cared for postoperatively on a regular hospital bed and is allowed to log-rolled every two hours. Wearing a plastic body cast the patient can begin walking and if paralysed, can begin sitting for progressively increasing periods with the assistance of the physiotherapists.

The measurement technique developed by Dickson and Harrington (2) was used to quantify the deformity of the spine. The mean preoperative angle of deformity, which is determined by drawing a line along the posterior surfaces of the vertebral bodies above and below the fracture and measuring the angle of the intersected lines was 22° and the mean displacement percentage, which is the ratio of the distance that the displaced vertebra has moved forward relative to the posterior surface of the fractured vertebra, to the width of the normal vertebra immediately below the fractured one was 21%. Postoperatively corresponding mean measurements were 0° and 0%. At follow-up the measurements did not change.

The classification of neural function developed by Frankel and associates was used to grade recovery of spinal cord function.

Grade A- Complete loss: Complete loss at both motor and sensory function below the segmental level of the cord lesion.

Grade B- Sensory only: Some sensation present below the segmental level of the lesion, but motor paralysis complete.

Grade C- Motor Useless: Some motor power present below the lesion, but not sufficient to be of practical use.

Grade D- Motor Useful: motor power below the level of the lesion.

Grade E- Intact: No neural deficits or symptoms.

### RESULTS

Each patient was assigned a preoperative and postoperative grade based on the neurological examination at the time of the initial hospital admission and again

at the time of follow-up. Neural functions of the three patients with complete neural function loss (Grade A) and two patients with intact cord function (Grade E) remained unchanged following the surgical intervention. Of the three patients with complete cord or cauda equina lesions (Grades B,C and D), two improved from D to E, and one from B to C. Of the remaining four patients with complete neural function loss, three improved from A to B, and one (2.0) made a dramatic improvement from A to D, who had L2 burst fracture and complete cauda equina lesion following an automobile accident, regained useful motor power below the level of the lesion and became continent after the operation. (Fig 2)

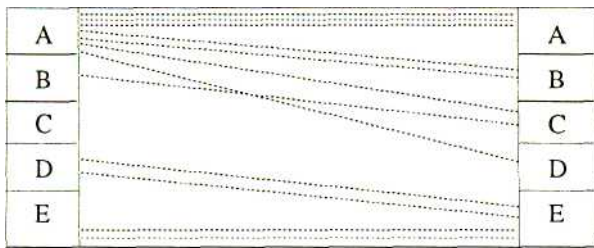


Fig 2- Neural function of the patients after injury and at followup (mean fourteen months) using Frankel grading system.

The mean interval from the day of injury to the day of admission was two and a half day (range zero to nine days). The mean hospital stay was fifty two days (range twenty three hundred seventy two days). Sagittal CT scannings of the patient, who were thought to be able to withstand the bizarre position of this mode of CT scanning, were performed to avoid the artifacts of the metal implants. The artifacts of the pedicle screws were negligible and it was possible to track the course of the pedicle screws in the pedicle and in the body of the vertebrae. One of the screws was observed in the thoracic aorta with no clinical evidence and one in the intervertebral disc space with no observable sign.

### Complications

There were only one patient with complication possibly related to incorrect placement of one of the screws into the pedicle. Following the operation, the patient described decreased cutaneous sensation of the

distribution of left L2 root and on X Rays, the corresponding pedicle screw was observed directed inferiorly and medially, possibly compressing the L2 root.

We did not observe any complication related to the implant failure. No sign of mechanical loosening and loss of the reduction demonstrated during the mean follow-up period of fourteen months.

Since only four St.George spinal plates removed from two patients as yet, it is early to evaluate the spinal mobility following the operations. However, in these two patients preoperative flexibility of the spine was regained. Some plates were bent and rotated in situ, especially at the thoracolumbar junction.

No case of infection, pulmonary embolism, meningitis or death was observed.

### DISCUSSION

Pedicle screw fixation of the spine is enjoying increasing world-wide popularity. There are several fixation systems available attached through pedicles, utilizing plates and screws, (5,6,7,9,10,11,12,13) wires and screws, (14) rods and screws, (15,16) and spinal external fixation devices using intrapedicular threaded pins. (17,18) All these systems depend upon the ability of a screw to obtain and maintain purchase in the vertebral body through the pedicle until solid fusion occurs.

In an experimental investigation, Schlipf et al demonstrated that the plate fixations provide the highest rigidity in comparison with ESSF device with or without screw fixation of the Facet joints, Jacob distraction rods and Harrington distraction rods. (19)

The integrity of the vertebral body and the posterior structures, and the alignment of the spine were regarded as the three major factors on which the stability of a fractured spine depends and if any two of these factors are lost, the spine is unstable. (2)

Preoperative and postoperative clinical and roentgenographical analysis in our small group of patients clearly shows that spinal plating with pedicle screw fixation is quite effectively accomplishes reduction and stabilization of the fractured thoracic and lumbar spine. St. George spinal plating has an advantage over Roy-Camille spinal plates having slotted screw holes with wave-like indentations to ensure proper seating of the screw heads. However, the necessity to bend St.George spinal plates during the operation to provide the anatomic lordosis and kyphosis of the spine overshadows this advantage.

## REFERENCES

1. Bryant, C.E., and Sullivan, J.A.: Management of Thoracic and Lumbar Spine Fractures with Harrington Distraction Rods Supplemented with Segmental Wiring. *Spine*, 8: 532 1983.
2. Denis, F.: The Three Column Spine and Its Significance in the Classification of Acute Thoracolumbar Spinal Injuries. *Spine*, 8: 817, 1983.
3. Dickson, J.H., Harrington, P.R., and Erwin, W.D.: Results of Reduction and Stabilisation of the Severely Fractured Thoracic and Lumbar Spine. *J. Bone Joint Surg.* 60A: 799, 1978.
4. Frankel, H.L., Hancock, D.O., Hyslop, G., Melzak, J., Michaelis, L.S., Ungar, G.H., Vernon, J.D.S., and Walsh, J.J.: The Value of Postural Reduction in the Initial Management of Closed Injuries of the Spine With Paraplegia and Tetraplegia. Part I. Paraplegia, 7: 179-192, 1969.
5. Jacobs, R.R., Schlaepfer, F., Mathys, R., Jr., Nachemson, A., and Perren, S.M.: A Locking Hook Spinal Rod System for Stabilization of Fracture-Dislocations and Correction of Deformities of the Dorsolumbar Spine: A Biomechanic Evaluation. *Clin.Orthop.* 189: 168, 1984.
6. Kostuik, J.P., Errico, T.J., and Gicason, T.F.: Techniques of Internal Fixation for Degenerative Conditions of the Spine. *Clin. Orthop.* 203: pp 219, 1986
7. Kiag.M.H., Beynnon, B.D., Pope, M.H., Frymoyer, J.W., and Haugh, L.D.: An Internal Fixator for Posterior Application to Short Segments for the Thoracic, Lumbar or Lumbosacral Spine: Design and Testing. *Clin. Orthop.* 203: pp 75, 1986
8. Luque, E.: Interpedicular Segmental Fixation. *Clin. Orthop.* 203: pp 54, 1986
9. Lewis, J., and McKibbin, B.: The Treatment of Unstable Fracture Dislocations of the Thoraco-Lumbar Spine Accompanied by Paraplegia. *J. Bone Joint Surg.* 56B: 603, 1974
10. Magerl, F.P.: Stabilization of the Lower Thoracic and Lumbar Spine with External Skeletal Fixation. *Clin. Orthop.* 189: pp 125, 1984.
11. Magerl, F.P.: External Spinal Skeletal Fixation In Weber, B.G., and Magerl, F.P. (eds). *The External Fixator*, New York, Springer Verlag, 1985.
12. Roy-Camille, R., Saillant, G., Berteaux, P., and Marrie-Anne, S.: Early Treatment of Spinal Injuries In MacKibbin, B. (ed.): *Recent Advances in Orthopaedics Number Three*. Dublin, Churchill Livingstone, 1979, pp 57-87.
13. Roy-Camille, R., Barcat, E., Demeulenaere, C., and Saillant, G.: Chirurole par abord posterieur du rachis dorsal et Lombar. *Techniques Chirurgicales*, 44 178-6, 1982.
14. Roy-Camille, R., Saillant, G., Mazel, Ch: Plating of Thracic, Thoracolumbar, and Lumbar Injuries with Pedicle Screw Plates. *Orthop. Clin. North Am.* 17: 1 pp 147-159 (1986)
15. Roy-Camille, R., Saillant, G., Mazel, Ch., Gagna, G., Caubel, P., Ciniglio, M.: The Surgical Treatment of Post Traumatic Vertebral Deformities. *Ital Journ. Orth. Traumatol.* XII, 4: 419-426 (1986)
16. Roy-Camille, R., Saillant, kG., Mazel, Ch.: Internal Fixation of the Lumbar Spine with Pedicle Screw Plating. *Clin. Orthop.* 203: pp 7-17 1986
17. 'Schlapfer, F., Worsdorfer, D., Magerl, F., and Perren, S.M.: 1982 Stabilization of the Lower Thoracic and Lumbar Spine: Comparative in Vitro Investigation of an External Skeletal and Various Internal Fixation Devices: In: Uthoff, H.K. (ed) *Current Concepts of External Fixation of Fractures*, Springer, Berlin Heidelberg, New Yorky pp 367
18. Stefee, A., Biscup, R., and Sitkowski, D.: Segmental Spine Plates with Pedicle Screw Fixation: A New Internal Fixation Device for Disorders of the Lumbar and Thoracic Spine. *Clin. orthop.* 203 pp 45 1986
19. Stefee, A., Silkowski, D., and Topham, L.: Total Vertebral Body and Pedicle Replacement. *Clin. Orthop*, 23 pp 203 1986
20. Wolter, D., Eggers Ch., Hoser, H., und Krumbiegel, A.: Wirbelsaulen und Beckenfrakturen im Rahmen der Mehrfachverletzung. *Chirurg*: 59, pp 648-655 (1987)