

OSTEOTOMY OF THE SPINE IN THE TREATMENT OF ANKYLOSING SPONDYLITIS

M. S. Filipovic, Z. B. Milinkovic, V. Basara, V. Basic

From 1982 to 1987 we operated 14 patients with severe lumbar kyphosis which has been associated with Bechterew's disease. Of these 7 were females and 7 males of the average age of 36 years (30-45). The mean follow-up was 6 years (ranging from 3 to 8 years) All patients were submitted to a functional surgery which consisted of osteotomy of the lumbar spine and reestablishment of lumbar lordosis. Indications for and osteotomy of the lumbar spine were cases of : hudge lumbar kyphosis that were exposed to permanent osification changes of the spine and without signs of the evolution of the disease. Corrective osteotomy of the spine was done in a one stage surgical procedure. The level of osteotomy was L3-L4 in 9 patients. In the remaining 5 patients osteotomy was done at the level of L2 - L3. Size of the osteotomy ranged from 2.5 to 3 cm. The obtained correction was fixed by means of transpedicular plate, Zielke's system or ordinary wire in 10 cases. Infour cases osteotomy remained unfixed. Posto-peratively, patients were immobilized in plaster jackets which they had to wear at least one year. All the patients were submitted to a weak-up test. In all the cases and excellent deformity correction has been achieved. In three cases the following complications occured : partial neurological deficit which completely recovered after six months, paraplegia which partially recurred and one case with recurrence of the deformity.

Key Words : osteotomy, lumbar kyphosis, ankylosing spondylitis.

Surgery of the kypholic deformity in ankylosing spondylitis consists of corrective osteotomy of the lumbar, cervical or thoracic spine. Main characteristics of ankylosing spondylitis arc : loss of lumbar lordosis, increased thoracic kyphosis, increased cervical kyphosis and flexion deformities of the hip.

Indications for the surgical treatment arc hudge kypholic deformity and patients who demand surgery. For establishing definite indications, basic disease should not be evolutive i.e. there should be no signs of inflammation and the spine should be fully fixed i.e. anterior longitudinal ligament should be completely ossified. Spinal osteotomy is performed in the cervical or lumbar part of the spine. If a patient has large flexional hip contractures, corrective spinal osteotomy should be followed by total hip replacemet.

MATERIAL AND METHODS

We operated 14 patients with large lumbar spine deformity, 7 females and 7 males. Preopcrative functional invctigations revealed considerable visual deficit (directly proportional to the spine deformity), slight nutritional disorders in 3 palincts and severe pain in 5 patincls. The average age of our patients was 36 years (30-40). In 3 patients after osteotomy of the.spine we performed total hip replaccmct.

Surgical Technique and Results

All the patients were submitted to general anesthesia. In two cases a special fiberoptic laringoscopc has been used for intubation.

On the operating table the patients were in the ventral position.

Those being fixed by transpedicular plate or Zielke's system were submitted to a double weak-up test (after osteotomy of the spine and after metal - transpedicular fixation).

Osteotomy of the spine was done at the L3-L4 level in 9 cases and at the L2-L3 level in the remaining 5 cases. Size of the osteotomy ranged from 2.5 to 3 cm.

Closing of the osteotomy was done by lifting up the patients' legs. Dura and the roots were under direct visual control.

The authors evaluation criteria are based on: (1) correction of the deformity, (2) improvement of visceral functions, (3) better psychological attitude and (4) radiographic correction. In all the cases an excellent deformity correction has been achieved. The patients can look ahead and walk normally. The mean angular correction was 35°. All patients were immobilized in plaster jackets which they had to wear at least one year after operation. This is a very important point.

We had three complications. Patients number 3 had a neurological deficit in the area of the rood of L4 which complotcty recovered after six months. In patient number 4 occured recurrence of the deformity after excellent deformity correction. Patient number 8 had severe postoperative respiratory complications, stress

ulcers and hypertension. In this case osteotomy has not been fixed and was soon followed by neurological deficit which partially recovered after one year. In 5 cases who complained of pain it disappeared in the postoperative period.

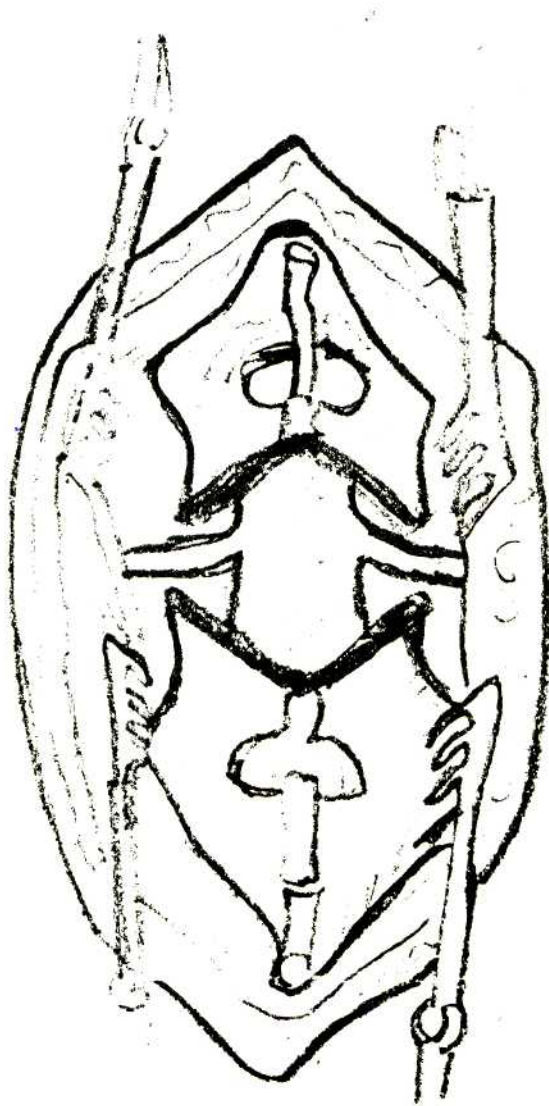


Fig. 1 : Surgical technique of lumbar osteotomy :
 A. Removal of processus spinosus of L2, L3, L4. B. Resection of both lamina. C. Excision of lower part of processus articularis from both side of L3. Roots of L3 are well visulised and have to be completaly free. D. Resection of lower half of pedicules of L3. The shape of a osteotomy is Figure - of - inverse V and size of the osteotomy have to be 2,5 to 3 sm.

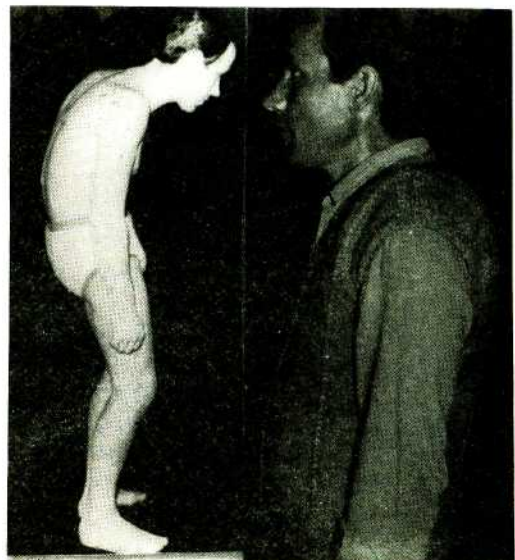


Fig. 2. :
 A. 35-years old patient before operation.
 B. Five years after surgery.

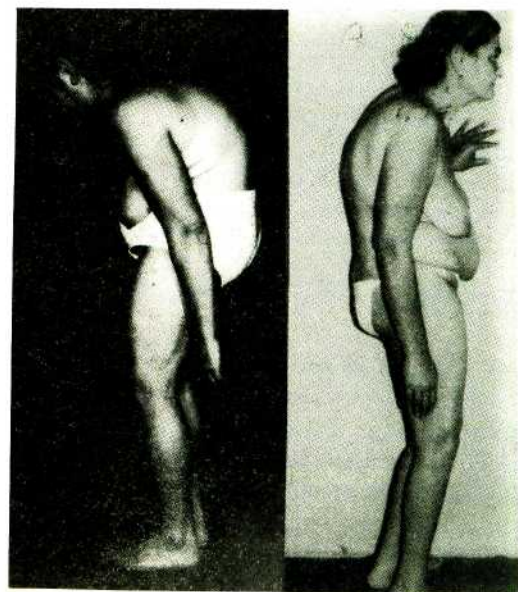


Fig. 3. :
 A. Middle - aged woman before operation and
 B. after the operation

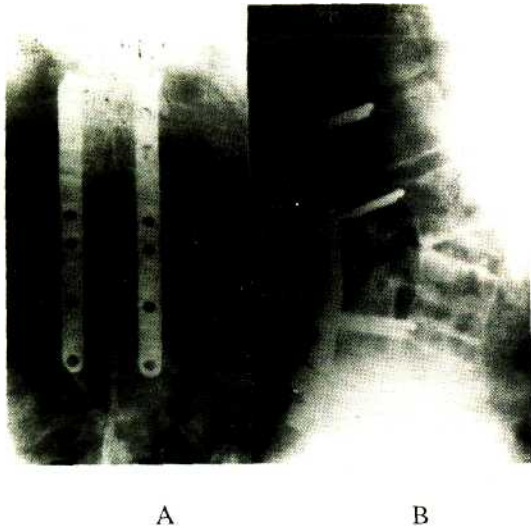


Fig. 4. :

A. and B. Metallic fixation after osteotomy is still controversial. Transpedicular fixation enabled us fast mobilisation of patients and it was prevention of neurological lesion.

DISCUSSION

In order to achieve correction of spine deformity in the lumbar region we have been using one stage surgical procedure. No osteotomy has been performed on the cervical and thoracic spine. Vertebral osteotomy correcting the spinal deformity improves respiratory function. It is due to the enlargement of the abdominal cavity, permitting a greater excursion of the diaphragm. Abdominal viscerae are decompressed and it improves gastro intestinal function. Also, there is a great improvement in the mental attitude. We would like to stress three points : 1. Complete osteotomy has to be done. The difficulties lie in obtaining the desired degree of correction. Performing osteotomy the size of which is about 2.5-3 cm. we are able to correct any deformity. 2. Metal fixation enabled fast mobilisation of patients as well as their easier and safer turning in the bed and prevention of eventual neurological complications. 3. Wearing of plaster jacket for one year after operation in order to prevent possible recurrence.

REFERENCES

- 1 . Bradford, S. David, Schumacher, L. Walter, Lonstein, E. John, and Winter, B. Robert : Ankylosing Spondylitis : Experience in Surgical Management of 21 Patients, *Spine*, 12 : 238, 1987.
- 2 . Camargo, P.F., Carderio, N.E., and Napoli, M.M. : Corrective Osteotomy of the Spine in Ankylosing Spondylitis, Experience with 66 cases. *Clin. Orthop.* 206, : 157, 1986.
- 3 . Herbert, J.J. : Vertebral osteotomy for kyphosis especially in Marie-Strumpell arthritis, *J. Bone Joint Surg.* 41A : 291-320, 1969.
- 4 . Law, WA : Osteotomy of the spine, *Clin. Orthop.* 66 : 70, 1969.
- 5 . Piishcl, J., Zielke, K. : Transpedicular vertebral instrumentation using VDS - instruments in ankylosing spondylitis, *Orthop. Trans.* 9:130, 1985.
- 6 . Simmons, E. : Kyphotic deformity of the spine in ankylosing spondylitis. *Clin. Orthop.* 128 : 65, 1977.
- 7 . Smith-Petersen M.N., Larson CB, Aufranc OE : Osteotomy of the spine for correction of flexion deformity in rheumatoid arthritis. *J. Bone Joint Surg.* 27 : 1, 1945.