



NEW CONCEPTS IN THE TREATMENT OF POTT'S DISEASE

İ. Teoman BENLİ⁽¹⁾, Alper KAYA⁽²⁾

SUMMARY:

Tuberculosis is a chronic infectious disease caused by mycobacteria of the "tuberculosis complex", mainly mycobacterium tuberculosis. The most frequent site for extra pulmonary involvement of tuberculosis infection is the vertebral column. In undeveloped countries, the disease is a significant source of morbidity and mortality, and in these regions it still remains the most common cause of non-traumatic paraplegia. Spinal instability and progressive kyphosis deformity are the main problems associated with the disease. Chemotherapy appears to be the mainstay treatment for tuberculosis. Medical Research Council Working Party on Tuberculosis of the Spine recommends ambulant chemotherapy consisting of a 6 or 9-month regimen of isoniazid and rifampin as the treatment of choice for developing countries. Surgery for tuberculous spondylitis is generally considered to be an adjunct to the effective chemotherapy. Indications for surgical treatment include neurological involvement, kyphotic deformity and the presence of a large tuberculosis abscess and/or abundant necrotic tissue. Currently the gold standard practice is probably radical debridement via anterior approach and anterior fusion with anterior strut grafts. As spinal cord compression is usually located anteriorly, anterior approach and decompression is the preferred route for neural decompression.

Satisfactory fusion rates have been reported with both either posterior or anterior approach. However, albeit in low rates, graft resorption can be observed in patients undergoing either anterior or posterior fusion alone, and kyphotic deformity due to asymmetric growth is likely in children. Recently, posterolateral or transpedicular drainage without anterior drainage or posterior instrumentation following anterior drainage during the same session has been offered as an alternative in an attempt to avoid kyphotic deformity. Posterior instrumentation in addition to anterior fusion, either sequential or staged, is associated with increased morbidity. Use of anterior instrumentation has been reported in a limited number of series. Based on the results of our recent studies on the treatment of active tuberculous spondylitis with anterior instrumentation along with anterior debridement and fusion, it can be concluded that this procedure is effective and provides a very high deformity correction and maintenance rates. Furthermore, as demonstrated by several other studies, the use of metallic implants in the presence of active tuberculosis infection appears to be a safe procedure associated with a very low rate of complications.

Key Words: Pott's disease, tuberculous spondylitis, instrumentation, surgical treatment.

⁽¹⁾ Assoc. Prof. Dr., Surgeon of Orthopaedics and Traumatology, 1st Department of Orthopedics and Traumatology, Ankara Social Security Hospital, Ankara, Turkey.

⁽²⁾ Surgeon of Orthopaedics and Traumatology, Etimesgut Hospital, Ankara, Turkey.

INTRODUCTION

Tuberculosis is a granulomatous infection that involves all tissue systems with caseation, tissue necrosis and cold abscess⁽⁷²⁾. The spine is the most common site of skeletal tuberculosis, accounting for 50 percent of cases. Any level of the spine may be involved, the lower thoracic region being the most commonly involved segment; next in decreasing order of frequency are the lumbar, upper dorsal, cervical, and sacral regions⁽⁶⁵⁾.

Historically, the earliest recorded description of spinal infection was associated with tuberculosis disease. The infection caused by *Mycobacterium Tuberculosis* is probably dates back to the beginnings of human history⁽⁷²⁾. In 1979, Zimmerman reported his observations providing evidence for the presence of lung and osseous tuberculosis in an Egyptian Mummy⁽⁷⁶⁾. (Figure 1) In 1998, Crubezy has isolated the DNA of mycobacterium tuberculosis from the skeleton of a 5400-year-old Egyptian Mummy, which also had marked kyphotic deformity⁽¹⁵⁾. The Hippocratic texts on tuberculous spondylitis are dated between the 4th century B.C. and 1st century A.D⁽⁷²⁾.

Percival Pott described tuberculosis of the vertebral column in 1877 as a kyphotic deformity of the spine associated with paraplegia⁽⁶⁵⁾. (Figure 2) Since then, the condition has often been referred to as Pott's disease. Menard in 1894 described a series of patients with Pott's paraplegia successfully treated with decompression via costotransversectomy^(48,65).

The great physicians and scientist who were involved in landmark discoveries in tuberculosis include Laennec, who disclosed the physical signs and morbid anatomy of the disease and suggested the concept of one disease with involvement of many organ systems early in the nineteenth century; Villemin, who in 1868 demonstrated that the infection was caused by a transmis-

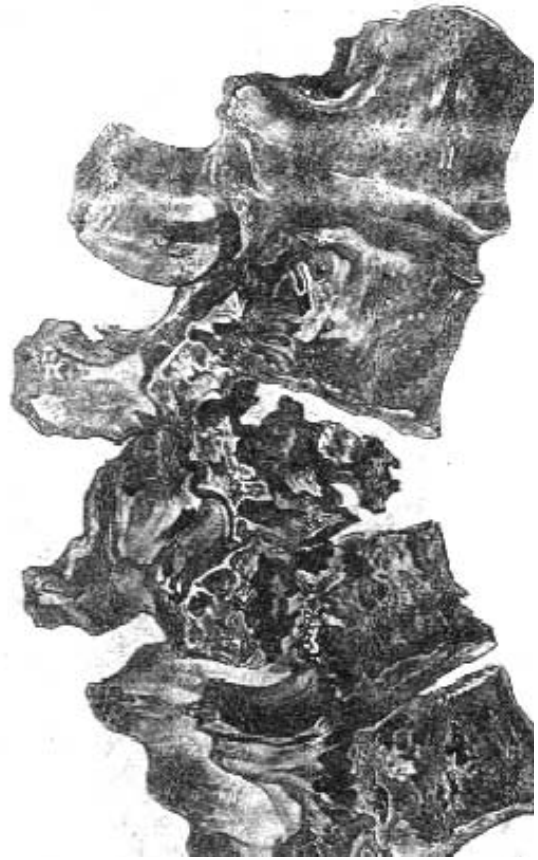

Figure 1: Vertebral spondylitis in an Egyptian Mummy.



Figure 2: Percival Pott

sible agent; Koch, who demonstrated the tubercle bacillus in 1882; Roentgen, whose discovery of x-rays in 1895 was the beginning of diagnostic radiology and allowed recognition of cavity formation; and Waksman, whose discovery of streptomycin in 1944 provided the first agent that could be used successfully in the chemotherapy of the disease⁽⁷²⁾.

Prior to the era of antibiotics and improvements in general health, multisegmental involvement was thought to be the norm (usually diagnosed at the autopsies), but today involvement of more than one noncontiguous region of the spine is very rare⁽⁶⁵⁾. The true incidence of primary posterior involvement is virtually unknown; however, the introduction of computerized tomography (CT) and magnetic resonance imaging (MRI) have probably increased the rate of identified cases to up to 10 % of the cases with extensive disease^(3,67).

Chemotherapy appears to be the mainstay in the treatment of tuberculosis. Only by the introduction of effective chemotherapy regimens the mortality associated with the disease could be controlled, and morbidity has been substantially decreased.

Surgery in tuberculous spondylitis is generally considered to be an adjuvant to the effective chemotherapy. Indications for surgical treatment include 1) neurological involvement, 2) deformity

and/or impending increase in deformity, and 3) the presence of large tuberculous abscess and/or abundant necrotic tissue^(51,65).

Drainage and debridement of cold abscess has become popular after Hodgson and Stock since 1960⁽²⁴⁾. Currently the gold standard practice is probably radical debridement via anterior approach and anterior fusion with anterior strut grafts⁽⁶⁵⁾. As spinal cord compression is usually located anteriorly, anterior approach and decompression is the preferred route for neural decompression^(30,65).

Oga and coworkers evaluated the adherence capacity of mycobacterium tuberculosis to stainless steel and demonstrated that adherence was negligible, and the use of implants in regions with active tuberculosis infection may be safe⁽⁵⁵⁾. Kostuik reported his experience on cases with healed or inactive disease⁽³⁶⁾. Anterior plate fixation along with debridement and fusion has been reported for a limited number of patients with active disease by the present author^(7,8).

Our prospective series of 63 patients with tuberculous spondylitis were treated with anterior instrumentation along with anterior debridement and fusion and results were reported in 2002⁽⁹⁾. Analysis of the clinical and radiological results of these patients revealed a very satisfactory rate of deformity correction as well as a high rate of correction maintenance (Table - 1). A very high rate

Table - 1. The average preoperative (PR) and postoperative (PO) local kyphosis (LK), loss of correction values (CL) and postoperative (CP) and final correction percentages (FP) of the patients according to vertebral regions. (n : number of patient)

	PRLK	CPLK (%)	t	P	FPLK (%)	CLLK
Thoracic (n : 25)	22.6° ± 7.5°	75.1° ± 22.4°	13.5	<0.05	69.8 ± 25.6	1.2° ± 1.8°
Thoracolumbar (n : 21)	24.0° ± 16.4°	85.8° ± 18.9°	7.8	<0.05	81.2 ± 24.7	0.9° ± 1.5°
Lumbar (n : 17)	23.5° ± 6.6°	78.9° ± 12.7°	19.3	<0.05	72.4 ± 16.3	1.4° ± 1.9°
Total (n : 63)	23.4° ± 10.9°	79.7° ± 20.2°	18	<0.05	74.2 ± 23.3	1.1° ± 1.7°

of fusion could be achieved, with a negligible number of complications.

EPIDEMIOLOGY

During the Industrial Revolution in the 18th and 19th centuries, the disease was known as the white plague. It was the leading cause of death in young people all over the world. Today, despite great progress in its treatment and control, it is still an important medical problem in many developing countries. A report from the World Health Organization in 1982 indicated that there were still 7 to 10 million new cases and about 3 million deaths each year from tuberculosis^(39,51,72).

Mortality rate reduced dramatically after Bosworth began using Streptomycin for bone and joint tuberculosis in 1950⁽¹²⁾. In the United States the tuberculosis mortality had decreased from a rate of 202 per 100.000 in 1950 to 11 in 1982, but the rate has tended to level off during the past few years, resulting in a decline of approximately 5 per cent per year⁽⁷²⁾. Korkusuz and colleagues reported 7 deaths in a series of 42 patients⁽³⁵⁾.

Nemir and Krasinski found that 57 % of the 211 tuberculosis cases reported in the United States of America between 1980 and 1986 were immigrants⁽⁵⁴⁾. Recent reports from the developed countries show that the majority of the patient population has come from the countries where the disease is endemic or socioeconomic conditions are poor, or the patients are either cocaine-like drug abusers or HIV porters (20,35,37,51). It is most common in undeveloped regions with problems of malnutrition and overcrowding, and affects all age groups, including children^(11,23,51). In the United States, it is a disease primarily affecting elderly adults and chronic alcoholics^(11,31).

In undeveloped areas, the disease is a significant source of morbidity and mortality, and in

these regions it remains the most common cause of non-traumatic paraplegia. Approximately 10 % to 40 % of the cases will develop neurological deficit⁽⁶⁵⁾. With the exception of the first decade of life, the age specific incidence of paraplegia is parallel with the age specific incidence of tuberculous spondylitis^(11,23).

Unfortunately, the number of cases reported from Türkiye is still as high as those from West and Middle Africa and Asia. Pott's disease is now infrequent in developed countries, but still constitutes a public health problem in undeveloped regions^(2,4,7-9,35,74). Every year, Turkish spinal surgeons treat a few hundred new patients with neurological deficit and deformities due to spinal tuberculosis medically and surgically.

In the past, tuberculosis spondylitis was a disease of early childhood, usually affecting children between 3 to 5 years old. Recently however, with improved public health measures, this age prevalence has changed, and adults are more frequently affected than children⁽⁶⁵⁾.

ETIOLOGY

The microorganism causing tuberculosis belongs to the genus *Mycobacterium*, which is classified in the family *Mycobacteriaceae* of the order *Actinomycetales*. Other families in this order are the *Actinomycetaceae*, with genera *Actinomyces* and *Nocardia*, and the *Streptomycetaceae*, which includes the genus *Streptomyces*. Taxonomists do not agree on the further classification of the genus *Mycobacterium*, but a useful concept is to include *M. tuberculosis*, *M. bovis*, and probably *M. africanum* in the tuberculosis complex. Some taxonomist would subdivide *M. bovis* into European, Afro-Asian, and African variants. A few suggest that there should be just one species, *M. tuberculosis*, with sub-classifications of bovine type, African type, and so forth⁽⁷²⁾.

M. tuberculosis is an obligate intracellular parasite that shares characteristic staining quality with other mycobacteria. The popular abbreviation AFB for acid-fast bacilli is based on this quality. Acid-fastness is the results of retention of carbol fuchsin (or certain fluorochrome dyes) after washing with acid, alcohol, or both. It is not unique to mycobacteria, since *Nocardia* and certain *Corynebacterium* strains may also be acid fast. Mycobacterial cell walls are rich in lipids, existing mainly as complexes with peptides and polysaccharides. Certain dyes can form a stable complex with one these lipid compounds, mycolic acid, provided the letter is contained within an intact cell wall structure ^(51,72).

PATHOLOGY AND PATHOGENESIS

Tuberculosis is derived from the word tubercle, meaning a small lump or nodule. Histopathologically, the tubercle is a less discrete focus of granulomatous inflammation consisting of lymphocytes, epithelioid cells, macrophages, and giant cells. The granulomas seen in tuberculosis are characterized by a form of tissue necrosis known as caseation, so called because the caseum has the consistency of soft cheese. Before the development of necrosis the lesion may heal completely by resolution, once necrosis and caseation have occurred it heals by fibrosis, encapsulation, calcification, and scar formation ^(26,72).

The *Mycobacterium* species are causative organisms, and *M. tuberculosis* is the most common pathogen. The primary route of infection is presumed to be hematogenous spread from established foci outside the spine. Pulmonary and genitourinary foci are the most common sources, although spinal lesions have been reported to arise from other skeletal lesions; additionally, direct inoculation can occur from adjacent visceral lesions ^(51,65). Some authors were unable to produce spinal tuberculosis by arterial inoculation, sug-

gesting a possible venous or lymphatic route of spread ^(37,65).

The initial focus of infection usually begins in the cancellous bone of the vertebral body and only occasionally in the posterior neural arch, transverse process, or subperiosteally deep to the anterior longitudinal ligament in front of the vertebral body. The area of infection gradually enlarges and spreads to involve two or more adjacent vertebrae by extension beneath the anterior longitudinal ligament or directly across the intervertebral disc. Occasionally, there may be multiple foci or involvement separated by normal vertebrae or the infection may be disseminated to distant vertebrae via the paravertebral abscess ⁽⁶⁵⁾.

The vertebral bodies lose their mechanical strength resulting in progressive destruction under the force of body weight and eventually they collapse. However, intervertebral joints and the posterior neural arch are intact; thus, an angular kyphotic deformity is produced, the severity of which depends on the extent of destruction, the level of lesion, and the number of vertebrae involved. In the thoracic region the kyphosis is most marked because of the normal dorsal curvature; in the lumbar area it is less pronounced because of the normal lumbar lordosis in which most of the body weight is transmitted posteriorly and collapse is partial; and in the cervical spine, collapse is minimal, if present at all, because most of the bony weight is borne through the articular processes ⁽²³⁾.

Healing takes place by gradual fibrosis and calcification of the granulomatous tuberculous tissue. Eventually the fibrosis tissue is ossified, with resulting body ankylosis of the collapsed vertebrae.

Paravertebral abscess formation occurs in almost every case. With the collapse of the body, tuberculous granulation tissue, caseous matter,

necrotic bone and bone marrow are extruded through the bony cortex and accumulated beneath the anterior longitudinal ligament. These cold abscesses gravitate along the facial planes and present externally at some distance from the site of the original lesion. In the lumbar region the abscess gravitates along the psoas fascial sheath and usually points into the groin just below the inguinal ligament. In the thoracic region the longitudinal ligaments limit the abscess, which is seen on the radiograph as a fusiform radiopaque shadow at or just below the level of the involved vertebra; if under great tension, it may rupture into the mediastinum, where it may be walled off to form the "bird's nest" type of paravertebral abscess. Occasionally, a thoracic abscess may reach the anterior chest wall at the parasternal area by tracking via the intercostal vessels. The prevertebral fascia limits the cervical abscess, which may burst into the retropharyngeal area or gravitate laterally on each side of the neck ⁽²³⁾.

When identification is possible, vertebral involvement typically presents as one of the following three forms: peridiscal, central, or anterior ⁽⁶⁵⁾. (Figure-3) In a series of 914 cases, Dobson reported peridiscal involvement in 33 %, central involvement in 12 %, and anterior involvement in 2 % of cases. In 53 % of the cases the disease was too extensive to determine the foci of origin. The incidence of primary posterior element involvement is unknown due to the typically extensive destruction at presentation, but is estimated to occur in up to 10 % of cases ⁽¹⁷⁾.

Peridiscal disease involvement begins in the anterior portion of the vertebral metaphysis with subsequent destruction of the adjacent end plate. Insidious spread to adjacent vertebrae occurs by extension beneath the anterior longitudinal ligament. The disc remains relatively preserved, even in cases of extensive bone loss, in

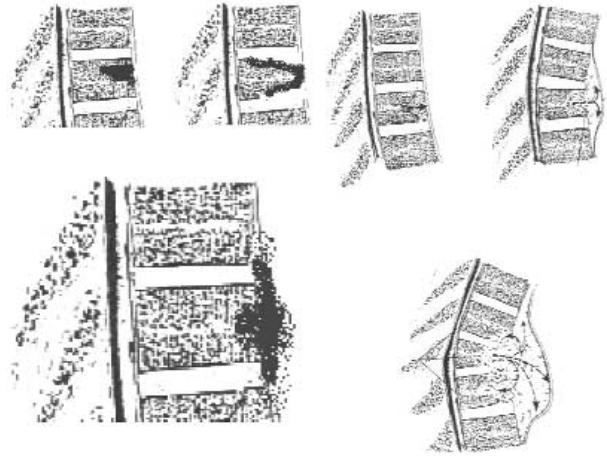


Figure 3: Vertebral involvement of tuberculous spondylitis typically.

distinct contrast to the prolific discal destruction noted in pyogenic infection ⁽⁶⁵⁾.

In central involvement, the disease remains within the vertebral body and is confined to one vertebrae. Vertebral weakening results in central collapse and significant spinal deformity. These lesions frequently are misdiagnosed as a tumor ⁽⁶⁵⁾.

Cases of anterior involvement begin beneath the anterior longitudinal ligament and demonstrate an anterior vertebral scalloping, typically over several vertebral levels ⁽⁶⁵⁾.

Compared with pyogenic vertebral infections, tuberculous infections typically spare the intervertebral disc, which at time of operation often can be found intact within an area of necrotic bone. The pathologic changes occur insidiously over a prolonged period with resultant greater deformity. Large paraspinal abscesses are more common with tuberculous versus pyogenic infections ^(23,51,65).

Several mechanisms are believed to be responsible for neurological deficit in tuberculosis spondylitis. Direct compression of the thecal sac can occur due to abscess formation, displaced bone or disc, or the development of kyphotic deformity.

Neurological deficit can develop secondary to epidural granuloma extension from adjacent bony infection or, in rare cases, from epidural or intradural granuloma formation without spinal structure involvement. Seddon classified neurological deficit with respect to the tuberculous disease condition. The paraplegia of active disease was noted in the acute condition and was recognized as being due to external pressure on or invasion of the dura and its contents. Neurological deficit in the chronic disease state (i.e., after healing of the disease) was believed to be due to dural sac pressure from chronic epidural granulomas, fibrosis, or the dorsal bony ridge of a progressive kyphotic deformity ^(23,25-26,30,38,52,65).

CLINICAL PRESENTATION

Vertebral column is one of the most common sites of involvement for tuberculosis, which is still a problem of high morbidity and mortality in the developing countries⁽³⁹⁾. Microabscess formation may then progress, causing bony destruction and clinical symptoms. Primary involvement of the posterior arches is uncommon, occurring in less than 0.45 % of the cases. The thoracic spine is most frequently involved, followed by the lumbar spine⁽⁵¹⁾. In our series, the site of involvement was thoracic in 39.7 % and lumbar in 33.1% of cases, which is in parallel with previous reports. (Figure 4) However, the most frequently involved vertebrae was L3 and 13.6 % of the 136 infected vertebrae were at this level⁽⁸⁾. (Figure 5)

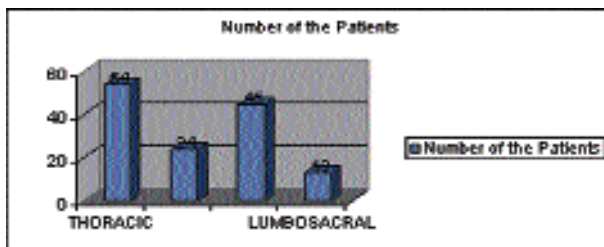


Figure 4: Distribution of the patients according to spinal region.

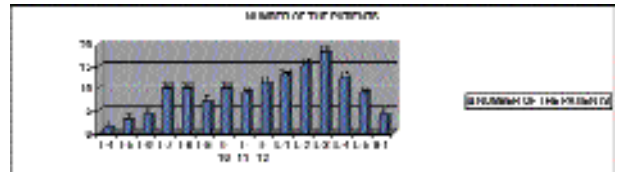


Figure 5: Distribution of the patients according to level vertebral.

The frequency of involvement decreased up to the cervical and down to the sacral region⁽⁶⁵⁾.

For spinal tuberculosis, an even distribution has been reported among all age groups. Still, spinal involvement is less in infants and children^(23,65). There are four children in our series with an average age of 10.3 years. (Figure 6) The remaining 72 patients were 19 years old or older, with an average age of 42.5 years. The most severely affected age was the 5th decade with a rate of 26.4 %, and the incidence fell down over 49 and under 40 years of age⁽⁸⁾.

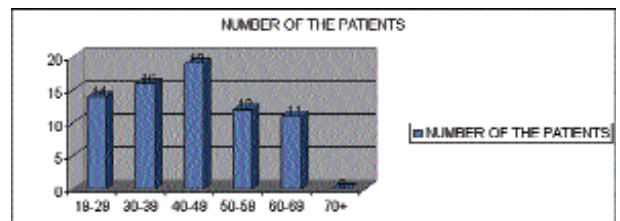


Figure 6: Distribution of the patients according to patients age.

Classic, constitutional symptoms such as fever, chills and weight loss may not be present, but the vast majority of patients complain of slowly progressive back pain. There may be an afternoon or evening fever. Backache is usually minimal; it may be referred segmentally ^(8,11,23,37,51,65).

Muscle spasm in the affected region of the spine is a constant finding. The spine is held rigid. When picking an object up from the floor, the child flexes the hips and knees, keeping the spine in extension. Motion of the spine is limited in

all directions. Spasm of the paravertebral muscles in the lumbar region is also elicited by passive hyperextension of the hips with the patient prone; this also puts stretch on the iliopsoas muscle, which is in spasm and contracture owing to psoas abscess⁽²³⁾.

On gentle percussion or pressure over the spinous process of the affected vertebrae, tenderness is often present. The abscesses may be palpated as fluctuant swellings in the groin, iliac fossa, retropharynx, or on the side of the neck, depending on the level of the lesion⁽²³⁾.

A kyphosis in the thoracic region may be the first noticeable sign. As the kyphosis increases, the ribs crowd together and a barrel chest deformity develops. When the lesion is situated in the cervical or lumbar spine, a flattening of the normal lordosis is the initial finding^(23,37,59,65).

The gait of the child with Pott's disease is peculiar, reflecting the protective rigidity of the spine. The child takes short steps, as he or she is trying to avoid any jarring of the back. In tuberculosis of the cervical spine, the child holds the neck in extension and supports the head with one hand under the chin and the other over the occiput. If the level is thoracolumbar and a psoas abscess is present, the child walks the knees and hips in flexion and supports the spine by placing the hands over the thighs. If paraplegia develops, lower limbs will be spastic with hyperactive deep tendon reflexes, a spastic gait, a varying degree of motor weakness, and disturbances of bladder and anorectal function⁽²³⁾.

Neurologic deficits develop in up to 40 % of patients. The incidence of paraplegia is higher in the disease affecting the thoracic and lumbar spine. Paraplegia presenting as the first sign of disease is most common in adults compared to children, who typically first present with kyphosis^(11,23,37,51). A unique condition occurs in heroin

addicts in whom a toxic presentation is observed with pain, fever, night sweats, weakness, and a rapidly evolving neurological deficit. The current incidence is much lower, owing to better diagnosis and early treatment. Younger children are more likely to become paraplegic^(41,53).

Hodgson classified paraplegia into four types⁽²⁵⁻²⁶⁾. The first is paraplegia of active disease resulting from external compression of the cord and dura. The compression is due to caseating pus, sequestra of bone and disk, dislocation of vertebrae, and granulation tissue within the spinal canal.

Clinically, these patients have varying degrees of spasticity of the lower limbs but do not have involuntary muscle spasms and withdrawal reflex. This type of paraplegia carries a good prognosis for full recovery after decompression and stabilization^(23,26).

The second type is paraplegia due to direct tuberculosis involvement of the spinal cord. In these cases tuberculosis meningitis and myelitis are present. These patients have more severe spasticity with involuntary muscle spasm and withdrawal reflex. This type of paraplegia is associated with a poor prognosis for recovery^(23,26).

The third type of paraplegia occurs after healing and is due to fibrosis of the meninges and granulation tissue causing cord compression. The fourth type is due to rare causes such as thrombosis of vessels supplying the cord^(23,26,60).

When paraplegia occurs, radiography, MRI, and myelography determine the level and type of lesion⁽⁵⁷⁾. Spinal fluid cell count and total protein determination will ascertain the extent of intradural infection. Early anterior decompression is strongly recommended, followed by spinal stabilization. Delay in the treatment may result in permanent paraplegia^(50,65).

DIAGNOSIS

- Laboratory studies:

The majority of available laboratory tests for tuberculosis spondylitis are sensitive but not specific. The ESR is generally elevated; Paus believed that an ESR greater than 50 mm/h contradicted a diagnosis of spinal tuberculosis unless there were complications of concomitant infectious disease^(65,72).

The Mantoux test, or the tuberculin purified protein derivative (PPD) skin test, is usually positive and indicates exposure to *M. tuberculosis* in addition to other less common atypical mycobacterial infections. False-negative reactions are seen with anergy that is typically associated with malnutrition, immunologic compromise, renal failure, overwhelming tuberculosis, and advanced age. Recommendations for a skin test include the addition of an anergy panel consisting of common agents that should cause a skin reaction^(11,65,72).

Polymerase chain reaction (PCR) has become a useful diagnostic tool for pulmonary tuberculosis. Most authors mention the limited success of this method in extrapulmonary involvement^(14, 58). In 1966, Berk et al. reported 94.7% sensitivity and 83.3% specificity for PCR in their series of 19 patients⁽¹⁰⁾.

- Radiographic Studies:

As with cases of pyogenic infections, the earliest X-ray findings are bone rarefaction followed by bone destruction. Unlike pyogenic infections, the initial radiographs in patients with tuberculosis spine infections often show far advanced bony changes with vertebral destruction due to the insidious nature of the disease. With peridiscal involvement, disc space narrowing is followed by adjacent vertebral destruction similar to pyogenic infections. With anterior multilevel involvement,

scalloped erosions occur at the anterior aspect of several adjacent vertebral bodies. Central body involvement results in central rarefaction and bony collapse, often resembling a tumor. The central type is more common in the thoracic area, and the peridiscal variant is more common in the lumbar region. The central type causes greater and earlier bone collapse than the peridiscal type. Primary posterior element involvement is rare, occurring in less than 10% of cases, and it is difficult to detect on plain radiograph⁽⁶⁵⁾.

Chest radiographs can be useful in demonstrating pulmonary involvement and may show a paraspinal abscess. Cold abscesses may present as a density increase in paravertebral region. Fusiform abscesses at cervical region and abscesses extending to the mediastinum at upper thoracic region appear as a 'bird nest'. Lower thoracic and lumbar abscesses appear as a density increase, particularly at psoas region, which can be recognized by experienced eyes in high quality radiographs⁽³⁷⁾. CT scans are helpful in delineating soft-tissue changes around the spine and in the spinal canal. However, radiographic evidence of soft-tissue changes in the paraspinal region does not allow differentiation of abscess formation from granulation tissue unless obvious tissue density differences are present in the suspected mass^(52,65).

Sclerotic reactive bone formation is seen much later (at 6 months to 2 years) and to a lesser degree in the healing phase of tuberculosis spine infection compared to pyogenic infections⁽⁶⁵⁾.

- Radionuclide Studies:

In the majority of cases, radionuclide studies are not needed for the diagnosis, as the vertebral changes are obvious at the time of clinical presentation. In some instances, radionuclide scanning may be helpful in defining the extent of dise-

ase involvement. Gallium scanning has been recommended for diagnosing extra-pulmonary tuberculosis in addition to monitoring treatment response. Unfortunately, radionuclide scans are not sensitive for tuberculosis infections with Technetium bone scans have been reported to be negative in 35% of cases and Gallium scans were negative in 70 % of cases in one series ^(39,65).

- Magnetic Resonance Imaging:

MR imaging is the imaging modality of choice due to its ability to demonstrate both soft-tissue and bony involvement ⁽⁶⁵⁾. MR imaging findings characteristic of tuberculosis spinal infections include demonstration of normal intervertebral disc signal, reflecting the resistance of the disc to tuberculous infection; this not the case in pyogenic infections. Additional findings include single vertebral body involvement in cases of central infection in contrast with the disc and adjacent vertebral body erosion characteristic of pyogenic vertebral osteomyelitis ^(23,65).

In the study of Srivastava and Sanghai, MRI of 40 patients with paraparesis revealed spinal tuberculosis as the etiological cause in 30% of the cases; and the authors suggested that MRI study should be performed particularly in patients with neurological deficits ⁽⁶⁶⁾.

Differential Diagnosis:

Pott's disease has been called the "great mimicker." Even with improved imaging modalities, vertebral biopsy and bacteriologic confirmation is necessary in all cases. Vertebral central body tuberculosis very closely resembles neoplasm. In cases of epidural involvement, tuberculosis granulomas without osseous involvement cannot be differentiated from an epidural neoplastic lesion except at the time of operation ⁽⁶⁵⁾.

For the differential diagnosis, primary and metastatic spinal neoplasms should be definitely excluded. Occasionally, clinical and laboratory findings may not be sufficient to exclude, thus diagnosis may only be established by pathological examination. Atypical bacteria, particularly actinomyces, nocardia and brucella may result in a similar clinical presentation and radiological appearance. However, these atypical diseases do not lead to severe vertebral destruction and collapse, and laboratory and immunochemical tests help in the diagnosis. Although rare, spinal involvement of coccidiomycosis, blastomycosis, cryptococcosis, candidiasis and aspergillosis should also be considered in the differential diagnosis, particularly in endemic regions ^(23,37,65).

It may be argued that in those patients with suspected tuberculosis spondylitis, the diagnosis, as well as the absence of secondary non-specific infection needs to be confirmed before the process of surgical decision-making. However, in areas where tuberculosis is an endemic problem, the rate of correct pre-operative diagnosis may be very high.

In addition to classical radiograms and laboratory tests, MRI is the most important method for diagnosing tuberculosis ⁽⁶⁵⁾. Radionuclide imaging is not very helpful in these cases. There are high false - negative rates with technetium (33 %) and gallium (70 %) scans. CT imaging reveals the extent of bony destruction better than MRI ⁽⁶⁵⁾. An and coworkers have reported a diagnostic accuracy of 97 % with MRI in a series of patients with spinal tumors or infectious diseases ⁽¹⁾. In his series of 24 patients, Desai reported that diagnosis of the disease was possible in the very early stages with MRI ⁽¹⁶⁾. Hoffmann et al. reported that MRI was necessary and very useful for surgical planning and diagnosing the canal compromise ⁽²⁸⁾. In the present study, our pre-operative diag-

nosis rate was 96.8 % (61 out of 63 patients) when a combination of MRI, CT and laboratory studies were used. The 2 patients pre-operatively diagnosed with having solid tumors constitute the false negative cases of this series. It should be noted however, that these figures might be misleading. The probable false positive cases who turned out not to be cases of tuberculosis spondylitis at surgery were not included in this database, hence; it can not be claimed that the diagnostic accuracy of these methods combined is as high as 96.8%. Schmitz and coworkers have demonstrated that Fluorine - 18 fluoro - 2 - deoxy - D -glucose positron emission tomography (PET) is more sensitive and accurate in the diagnosis of tuberculosis spondylitis compared to MRI, especially in the presence of metallic implants⁽⁶³⁾. This technique may be used so as to achieve a higher rate of diagnostic accuracy in the future.

TREATMENT

Treatment goals of spinal tuberculosis are as follows: eradication of the infection, prevention of spinal deformity, and prevention of paralysis. Recent advances of the modern antibiotic era have significantly lowered patient morbidity and mortality and have allowed for chemotherapeutic treatment of uncomplicated cases, in addition to clarifying the role of operative intervention⁽²³⁾.

The introduction of streptomycin in 1943 provided the first effective means of chemotherapeutic control of tuberculous disease. Later additions of isoniazid, rifampin, and other agents into the treatment regimen eliminated the risk of disease dissemination and reduced the development of chronic sinuses after surgical debridement.

- Conservative Treatment:

Many years ago, only conservative treatment modality, in addition to medical treatment, was

bed rest. Inevitability of progressive spinal deformities in these patients gave rise to the idea of keeping these patients in 'cast beds'. Afterwards, the concept of ambulatory treatment in addition to trunk casts and orthosis became more popular. In the study of MRC comparing ambulatory and non-ambulatory conservative treatments, similar results were obtained with ambulatory treatment without bed rest^(37,51,65).

Conservative treatment may be used in mild to moderate cases in the absence of significant abscess formation and spinal deformity, collapse, neural or vertebral instability. On the other hand, the chance of conservative treatment is usually missed and patients initially present with severe vertebral involvement and neural deficit to the orthopedist. In cases with mild to moderate involvement and without vertebral destruction, drainage of the abscess with the aid of radiological methods together with ambulatory chemotherapy is among currently used conservative treatment methods⁽⁶⁵⁾.

- Chemotherapy:

Chemotherapy remains integral to the treatment of spinal tuberculosis, whether as a primary therapy or a surgical adjuvant. First line drugs include isoniazid, rifampin, ethambutol, pyrazinamide, and streptomycin. Occasionally used second-line agents include paraaminosalicylic acid, ethionamide, cycloserine, amikacin, and capreomycin^(23,51,65,72).

The treatment of choice for tuberculosis infection is short-course chemotherapy for 6 months. The recommended regimen for newly diagnosed patients is 2 months of oral isoniazid (10mg/kg/d in adults and 5mg/kg/d in children; maximum 300mg/d), rifampin (10mg/kg/d; maximum 600 mg/d), and pyrazinamide (25mg/kg/d; maximum 2g/d) daily, followed by 4 months of isoniazid and

rifampin given daily. Patients of recent immigration from tuberculosis endemic regions or areas of increased drug resistance should receive the standard regimen plus oral ethambutol (25 mg/kg/d; maximum 2.5 g/d) for the first 2 months. In cases of suspected multiple drug resistance, an injectable drug (e.g., amikacin, capreomycin) and a fluoroquinolone should be added^(23,37,72).

Potential toxic drug side effects include increased risk of hepatitis with isoniazid and rifampin (four times more common in patients receiving both agents than in those receiving isoniazid alone), peripheral neuropathy with rifampin, optic neuritis with ethambutol, and vestibular dysfunction and eighth cranial nerve damage with streptomycin^(62,72).

Multiple drug therapy is used owing to potential for resistance to a single agent. Areas with a high prevalence of isoniazid-resistance include Korea and other Southeast Asian countries⁽⁶⁵⁾. Up to 8 % of reported cases in the United States are primarily resistant to combined isoniazid and rifampin treatment, primarily in the urban areas of the northeastern United States⁽⁶²⁾. As of 1996, several small clusters of multiple drug-resistant tuberculosis were reported, primarily in people infected with human immunodeficiency virus (HIV), with some organisms resistant to as many as seven drugs⁽¹⁹⁾.

- The Results of British Medical Research Council (BMRC) Subcommittee of the Working Party on Tuberculosis of the Spine:

In an effort to consolidate divergent treatment schemes, the BMRC subcommittee, the Working Party on Tuberculosis of the Spine, was formed in 1963 to perform a number of large-scale, controlled, prospective treatment trials. The design of each study was based on the resources available in areas of endemic tuberculosis and com-

pared the efficacy of different treatment regimes based on the percentages of patients achieving favorable status after 3-, 5-, and 10-year follow-up. Favorable status was defined as full physical activity with clinically and radiographically quiescent disease, no sinuses or clinically evident abscesses, no myelopathy with functional impairment, and no modification of the treatment regimen. Favorable status did not take into account symptomatic relief, fusion rate, or angle of kyphosis⁽⁶⁵⁾. The first series established that chemotherapy alone is highly effective in ambulant patients, with no advantage gained by an initial period of hospital bed rest, plaster jacket immobilization for 9 months, or addition of streptomycin to the chemotherapy regimen. Results were maintained at 5- and 10-year follow up^(42,65).

Another series compared efficacy of short-course chemotherapy (6- and 9-month) versus the standard 18-month regimen of previous studies in both surgical and ambulant treated patients. In Hong Kong, patients underwent radical operation and either 6- or 9-month therapies were equally effective and as successful as the standard 18-month therapy course. In South India, ambulant chemotherapy alone of 6- and 9-month duration was compared with radical surgical debridement plus 6 months of chemotherapy. In ambulant patients, 97 % of the patients treated for 9 months achieved favorable status, versus 93 % in the 6-month treated group and 85 % in the combined surgery-chemotherapy group^(45-46,51,65).

The recommendation of the Medical Research Council was to use ambulant chemotherapy with 6- or 9- month regimens of isoniazid and rifampin as treatment of choice in developing countries. Recommended use of surgery was for biopsy or in cases of myelopathy, abscesses, or draining sinuses. When surgery was indicated, the Hong Kong operation of radical debridement and anterior bony fusion was recommended ver-

sus debridement alone due to earlier fusion and less progression of the kyphotic deformity at 10-year follow up. An additional advantage of the anterior debridement and fusion has been the reported higher rate of recovery in patients with neurological deficit ⁽⁴²⁻⁴⁷⁾.

- Surgical Treatment:

The objectives of the surgical treatment in patients with tuberculosis spondylitis are provision of vertebral stability and ameliorating neurological disorders in addition to the eradication of the infection. Pathological fractures and dislocations due to significant vertebral destruction lead to vertebral instability and compression by bony fragments and the abscess give rise to neurological instability. Under these conditions, surgery is inevitable. Surgical methods include drainage of the abscess alone, debridement of the destroyed vertebra from anterior, posterior or postero-lateral, anterior and posterior grafting with the correction of kyphosis, and instrumentation techniques combined with above methods in order to protect fusion area and prevent late kyphosis ^(37,51,65).

Reported indications for surgery in spinal tuberculosis are as follows: the presence of a large paraspinal abscess, the presence of severe bone destruction and kyphotic deformity, neurological deficit with spinal cord compression, and lack of response to conservative treatment ^(51,61). Posterior fusion had been the standard surgical procedure for the limited correction and prevention of progression of deformity in many centers before the safe and liberal use of anterior spinal surgery became feasible. However, posterior fusion does not appear to alter the natural course of the disease process, pseudoarthrosis and bending of the fusion mass very frequently leads to substantial increase of the kyphotic deformity ^(2,23,59,70).

- Anterior radical debridement:

Anterior drainage was first used by Ito and colleagues for tuberculous spondylitis in 1934 ⁽³⁹⁾. After 1956, Hodgson and Stock popularized anterior intervention ⁽²⁴⁾. They reported the results of 100 cases for which they performed debridement of destroyed spine, abscess drainage and anterior grafting, after that the technique was further developed in Chorea ^(27,42-43). Also called Hong Kong procedure, this method includes the excision of the whole destroyed vertebra, abscess drainage and anterior support grafting ⁽⁴²⁻⁴³⁾.

Anterior debridement without fusion has been evaluated for the treatment of spinal tuberculosis in MRC studies conducted in Hong Kong and Bulawayo, demonstrating that the magnitude and the rate of progression of the kyphotic deformity was similar in patients who had no surgery, and were significantly inferior compared to anterior debridement and fusion ⁽⁴²⁾. Longitudinal follow-up of the same group of patients revealed that bony fusion occurred later in those who had anterior grafting compared to only debridement, but the rates of fusion were similar at five years ⁽⁴³⁾. Over ten years, debridement group exhibited a mean increase of 9.8 degrees in kyphosis for thoracic and thoracolumbar lesions and 7.6 degrees for lumbar lesions, compared to minor changes in the fusion group ⁽⁴⁴⁾. Upadhyay and coworkers reported the latest follow-up of the same group of patients, concluding that the debridement group demonstrated increases in kyphotic deformity for up to six months. Therefore, adult patients demonstrated an arrest in progression, while some spontaneous correction of the deformity occurred in the pediatric patients ⁽⁶⁸⁻⁷¹⁾. Aksoy et al. reported a series of 100 patients either with posterior or anterior fusion only and demonstrated that kyphotic deformity developed less frequently after anterior fusion ⁽²⁾. Rajasekaran and Soundarapendian reported 59 % kyphotic deformity with anterior fusion ⁽⁵⁹⁾.

With anterior debridement and fusion, the MRC trials demonstrated that an increase in kyphotic deformity occurred in only 17 % of patients compared to 39 % of patients treated with chemotherapy. In contrast to patients treated with only anterior debridement, the progression of the kyphotic deformity was considerably less, especially during the first six months of the treatment⁽⁴²⁻⁴⁷⁾. Kyphotic deformity did not significantly increase in these patients after six months regardless of the treatment method. In another study 59 % of patients had favorable results (excellent or good), 19 % were rated as fair, and 22 % as poor⁽³²⁾.

- Anterior Strut Grafting :

The anterior approach facilitates stabilization through strut grafting using autogenous bone graft, fibula or rib. Tricortical iliac crest is preferred because it includes cortical as well as cancellous bone with great structural strength⁽⁵¹⁾. Stabilization with autogenous iliac crest graft is a reliable procedure with bony fusion rate greater than 95 % at 10-year follow-up^(24,27,33,65). Long-term follow-up of postoperative kyphotic deformity notes excellent maintenance of angular correction compared to other forms of treatment⁽³³⁾. Current recommendations are for autogenous iliac crest grafting, especially in patients with large defects spanning greater than two disc spaces^(51,65).

Kempf and colleagues noted poor results with autogenous rib grafting, particularly in adults, reporting a 62 % fusion rate, 32 % incidence of graft fracture, and a mean kyphotic increase of 20° in a series of 63 patients⁽³³⁾. Partial collapse occurred in some cases due to rib graft penetration of the vertebral end plate. Other investigators report similar difficulties with rib grafting spanning significant defects⁽⁵⁾. Recommendations for rib grafting are for use as a local material in cases of minimal defect less than two disc spaces, prefe-

rably in children^(51,65). Use of rib or fibula requires availability of solid endplates into which the graft can be embedded. If the rib graft is to be used, at least two or more rib grafts must be placed for adult patients⁽⁸⁾. Govender reported that allografts incorporated later than autologous rib grafts in patients treated with anterior fusion and anterior instrumentation⁽²¹⁾. In our study, we used at least 3 autologous costa grafts in the thoracic and thoracolumbar region and iliac grafts in the lumbar region and we did not encounter any problems such as graft resorption. Implant failure and pseudoarthrosis were not noted and a solid fusion mass was obtained in all patients. Tuberculosis reactivation was not observed⁽⁹⁾.

Several investigators have described the successful use of vascularized rib grafts for the stabilization of kyphosis⁽⁴⁰⁾. Bradford and Daher, in a series of 25 grafting patients (with a mean of four vertebral levels) reported a mean graft incorporation occurring at 8.5 weeks with no cases of graft fracture, including 3 patients in whom the graft placed greater than 4 cm anterior to apical vertebrae for mechanical advantage. Twenty percent of the patients lost 5° or more correction at 2 years of follow-up⁽¹³⁾.

- Pediatric patients:

An increase in kyphosis may be observed in children despite surgical treatment. Multicenter studies of BMRC also support the increase in kyphosis with asymmetric growth following anterior radical debridement and strut grafting⁽⁴⁷⁾. Moola and colleagues reported in their series of 220 patients an increase in local kyphosis angle from 53° to an average of 140° with conservative treatment and they obtained 68% correction in cases treated surgically⁽⁵²⁾. Mallet and colleagues found that kyphosis was inevitable in the growing child despite surgical treatment⁽⁴¹⁾. Schulitz and colleagues reported the 5-20 years follow-up re-

sults of 117 children between the ages of 2-6 years. They found a 15° increase in kyphosis by the growth of the child even if the solid anterior fusion mass was formed, however relatively less kyphosis developed in patients who underwent anterior and posterior combined fusion⁽⁶⁴⁾. Pathasarathy and colleagues suggested that a severe increase in kyphosis may be observed in patients younger than 15 years old with conservative treatment if the initial degree of kyphosis is above 30°⁽⁵⁶⁾. In our series, 100% correction was obtained in children with instrumentation; however in cases with anterior fusion alone 12.2% correction could be obtained with a 23.3° correction loss after 2 years of follow-up⁽⁸⁾. As a result, conservative treatment is not effective on the increase in kyphosis by the growth of the child. An increase in kyphosis may be observed despite anterior fusion alone, thus combined anterior and posterior fusion is more successful⁽³²⁾. Significant correction losses may be seen in children despite instrumentation^(39,51,65).

- Neurological Recovery:

The compression of the cold abscess or bony fragments, acute local kyphosis, vascular collapse and ischemic necrosis due to edema or direct meningeal involvement may cause neurological deficit^(32,50). Cases of neurological deficit merit special attention. Results with anterior decompression and fusion have been slightly superior to the results of non-operative treatment of the cases⁽⁶⁵⁾. Pattison and colleagues reported 79 % neurological improvement with conservative therapy in their series of 89 patients but 46 % of these patients deteriorated neurologically in two months⁽²¹⁾.

According to Moon, neurological deficits develop in up to 40 % of patients⁽⁵¹⁾. Bailey et al. reported a 70 % rate of neurological deficits in children⁽⁵⁾. Tuli noted 78.5 % success rate when

patients were operated only if they failed to respond to an initial course of antibiotics⁽⁶⁷⁾. In general, patients with less severe neurological deficit or patients treated early after the onset of the deficit have a better outcome. Hodgson and Stock have described a direct correlation between the preoperative duration of neurological symptoms and postoperative time needed for the recovery of paraplegia⁽²⁷⁾. Aydin and his colleagues reported a neurological improvement in 100 % of patients (71.4 % complete, 28.6 % partial); corresponding figures for other series were as follows: Loembe et al., 82 %; Moon et al., 89.6 %, and Rezai et al., 100 %^(4,38,49,61). We obtained a 92.6 % neurological improvement rate (74.1 % complete, 18.5 % partial) in our series, and the patients who did not benefit from surgery were the patient who had referred late⁽⁷⁾. Hsue et al. reported complete or almost complete neurological recovery in 15 of the 18 patients, although all had referred late⁽³⁰⁾. Slucky recommends early decompression in cases of spinal cord compression instead of delaying it to see if drug therapy alone will be effective. Patients with paraplegia of long duration should be treated aggressively. Conversely, lumbar lesions with root deficit respond adequately to non-operative versus operative treatment⁽⁶⁵⁾.

- Posterior Instrumentation:

The need for prolonged immobilization following anterior procedures and relatively high rates of kyphosis progression -frequently related to the problems with strut grafts- prompted the idea that tuberculosis spondylitis may be stabilized by posterior instrumentation^(27,61). Oga and coworkers obtained good clinical results, but the instrumentation was extended to an alarming average of 8.5 levels, although average 3.5 levels were involved by the disease⁽⁵⁵⁾. Moon et al. reported very good rates of correction and sustained cor-

rection for both children and adults, fusion occurred in four months in single level spondylodesis cases and in six months in two-level cases ⁽⁴⁹⁾.

Several studies have demonstrated satisfactory results using posterior instrumentation along with anterior debridement and fusion ^(46,48,67). Güven et al. reported a series of 10 cases with posterior instrumentation, in which there was a 3.4° loss in the correction of local kyphosis ⁽²²⁾. Domaniç et al. reported their results for anterior debridement; correction of the kyphosis was more successful in patients who had additional posterior CD instrumentation ⁽¹⁸⁾. Yau et al. reported higher success rates with anterior fusion and posterior instrumentation performed during the same session ⁽⁷³⁾. In our recent series, 72 adult patients with varying surgical procedures were assessed (Figure 7). Eight patients had only anterior debridement and fusion, with 8.6 % correction rate and average 23.6° correction loss during follow-up compared to 76.8 % average correction and 2.5° correction loss in 11 patients who had posterior instrumentation following anterior radical surgery. ⁽⁸⁾. (Figure 8)

- Anterior Instrumentation:

Anterior instrumentation in active tuberculosis infection is a relatively new concept, and the results of this method should probably be compared to those achieved with other modalities of surgical treatment as well as other reports on anterior instrumentation ^(8,9,29,75).

Kostuik reported a series of 79 patients with anterior decompression and anterior internal fixation in 1983, among whom 51 had neurological deficits. He reported two patients developing deformity due to spinal tuberculosis ⁽³⁶⁾. There has been very limited experience with anterior instrumentation following anterior radical debridement and fusion, especially on the early ca-

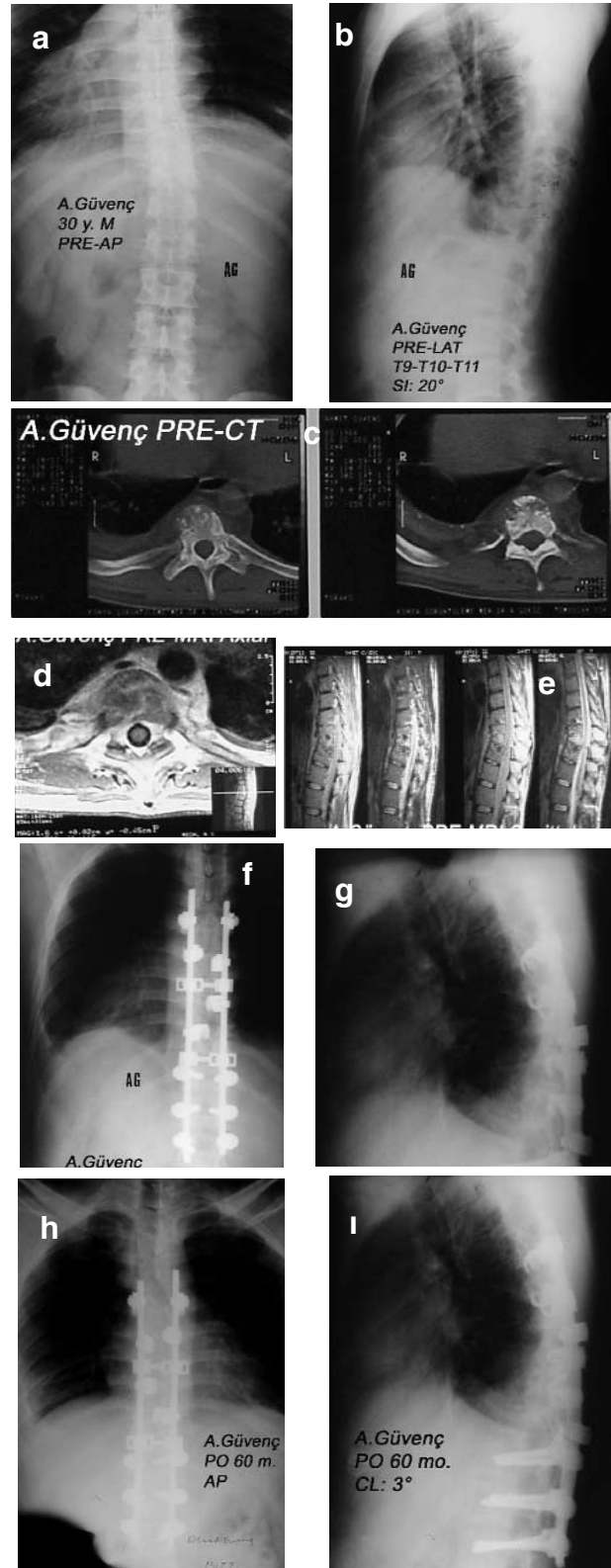


Figure 7: Preoperative posterior-anterior (a), lateral (b) graphics, CT images (c), axial MR (d) and sagittal MR (e) images of the patient (AG) treated with posterior instrumentation.

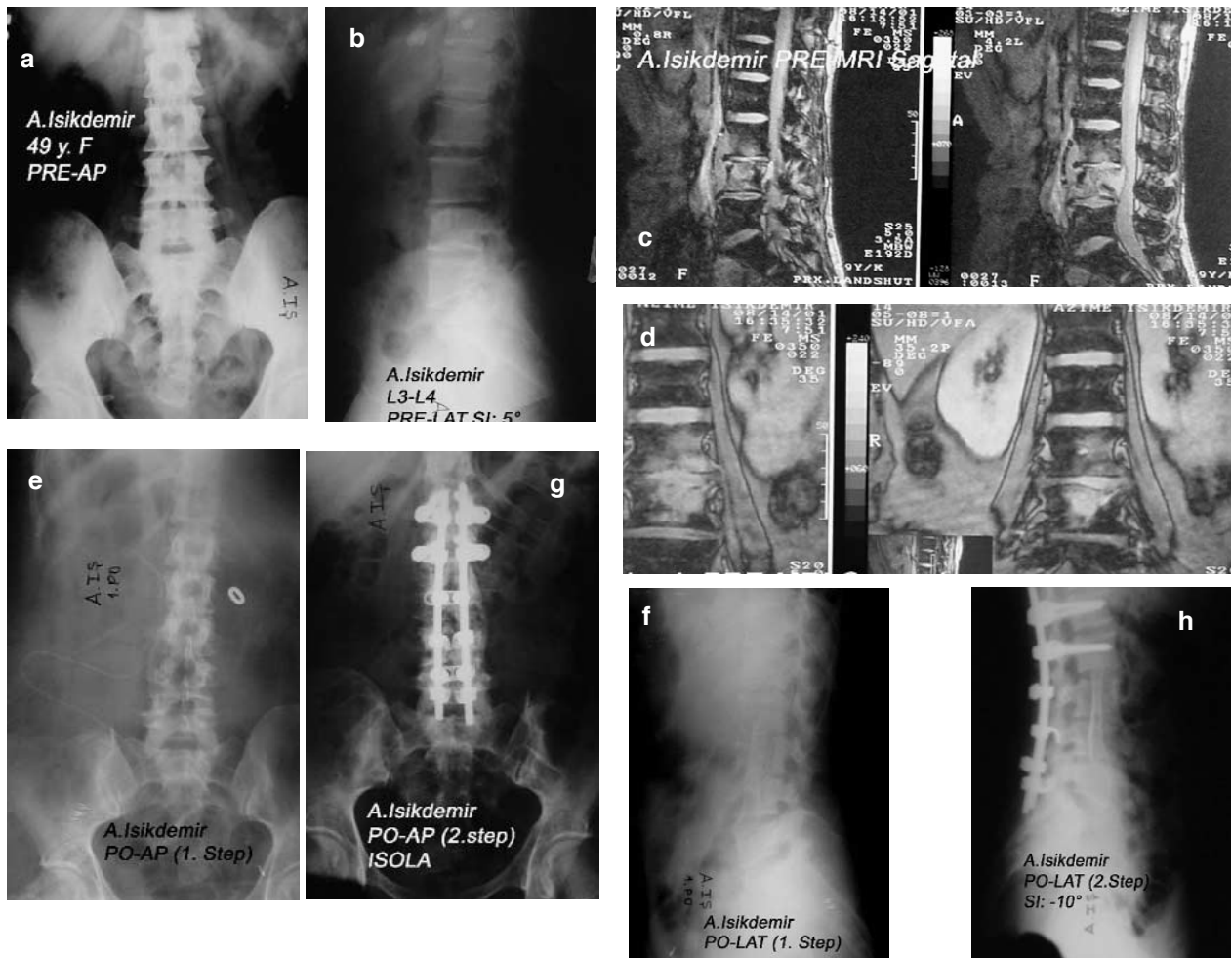


Figure 8: Preoperative A-P (a), letaral (b) graphies, sagittal and frontal (c) MR images of the patient treated with combined surgery and posterior isola instrumentation. After first step operation AP (e) and lateral (f) and after second step operation AP (g) and lateral (h) graphies of the patient.

ses with active disease⁽⁶⁾. This reluctance so far probably arises from the presumption that placing the instrumentation in an area with active infection would be prone to complications like disease reactivation or secondary infection⁽³⁴⁾. The results of our last study demonstrated that anterior instrumentation in the presence of active infection does not cause any major complications, probably because of the poor adherence capacity of the tuberculosis bacilli to metals.

We have reported our first nine cases in 1996⁽⁷⁾. Yilmaz and coworkers reported on 22 patients with single or double level and 16 patients with

multilevel involvement, and treated with anterior instrumentation. Their rates of correction were 64 % and 81 % for short and long fusion, respectively; an overall average of 3° of correction loss was encountered without any major complications⁽⁷⁴⁾. In another study of 45 cases, we compared the results anterior radical debridement with anterior instrumentation versus posterior instrumentation. We obtained statistically similar correction rates with anterior instrumentation; however this procedure required fewer mobile segments to be instrumented. Also we suggested that posterior instrumentation could be preferred

in the following conditions: if multiple regions are involved, if more than 2 vertebrae are involved, or if involvement is at the lumbosacral junction⁽⁸⁾. In our last study, the results of 63 patients with 50.9 months of follow-up were evaluated and our correction rates in local kyphosis angle were ($79.7 \pm 20.2\%$), our correction loss at the last control visit ($1.1^\circ \pm 1.7^\circ$) and our final correction rate ($74.3 \pm 23.3\%$) were parallel with previously reported results⁽⁹⁾. Evaluation of the effect on sagittal global contours showed a statistically significant correction rate in thoracic, thoracolumbar and lumbar regions, in addition, correction losses at the last follow-up visit were very small. The normal physiological sagittal contours were ma-

intained in the thoracic and thoracolumbar regions of 88 % and 71.4 % of patients, respectively, but physiological normal lumbar lordosis was restored in five patients. It is noted that application of a distraction for the correction of the local kyphosis deformity in thoracic region resulted in a decrease in the global kyphosis angle. In spite of this effect, neither hypokyphosis nor lordosis was noted in the thoracic region. It played a positive role in the lumbar region by increasing lordosis. Implant failure and pseudoarthrosis were not noted and a solid fusion mass was obtained in all patients. Tuberculosis reactivation was not seen (Figure-9, 10).

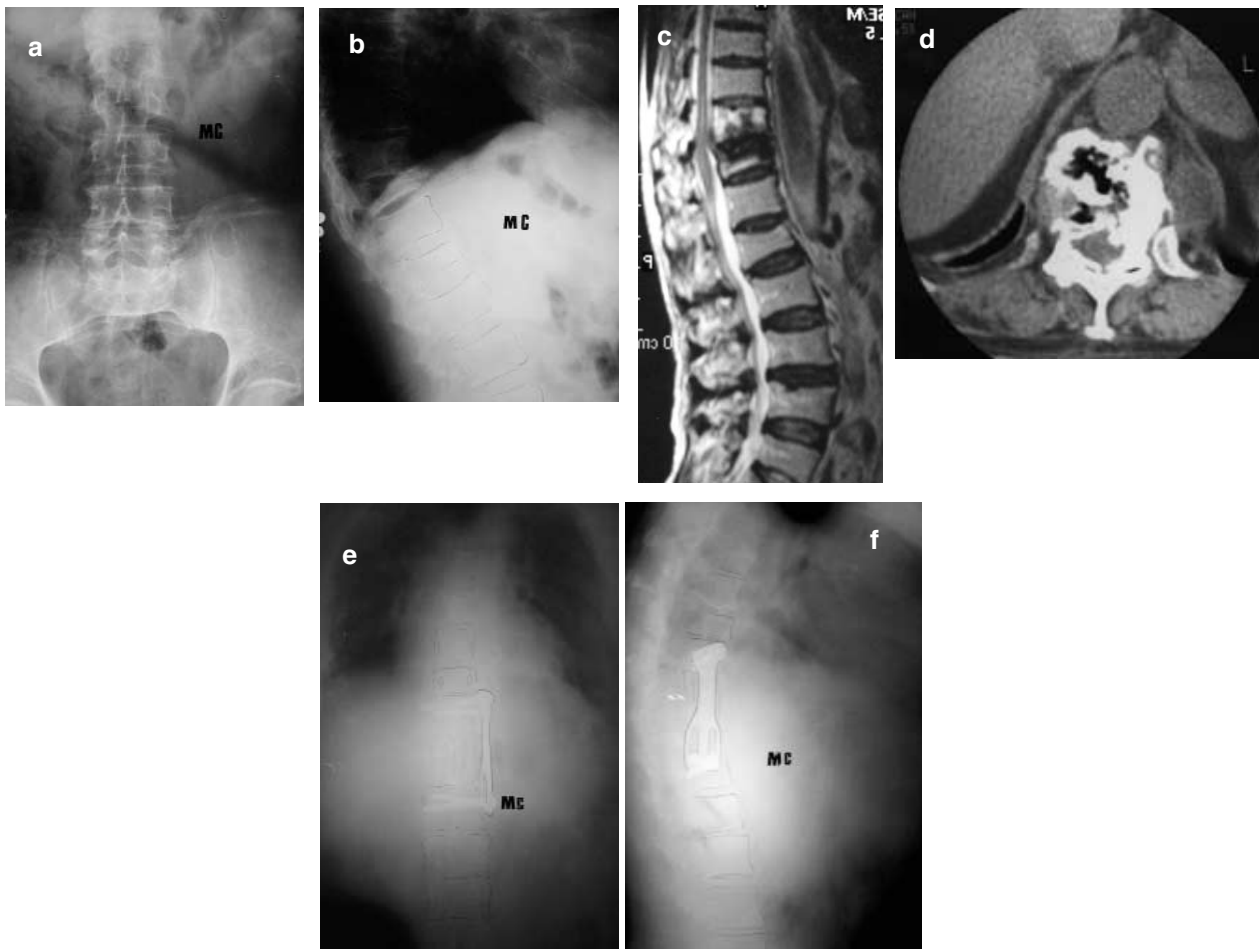


Figure 9: Preoperative AP (a) and lateral (b) graphies and sagittal (c), axial (d) MR images of the patient (MG) treated with anterior radical debridement, anterior strut grafting and anterior Z-plate instrumentation. Postoperative A-P (e) and lateral (f) of the patient is seen in the figure.

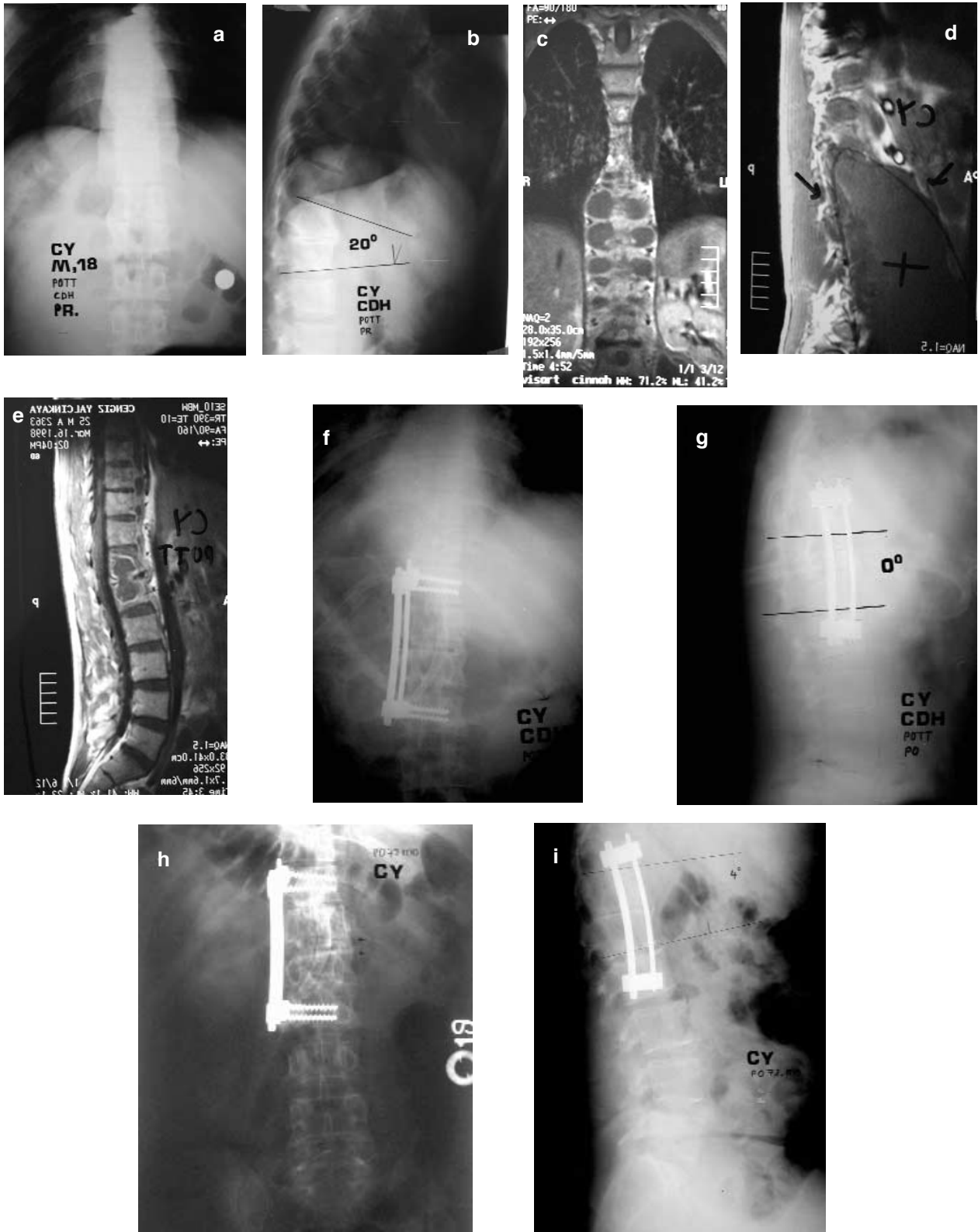

Figure 10: 18 years old male patient (CY) had multilevel affection. Preoperative AP (a) and lateral (b) graphies, coronal (c) and sagittal (d-e) MR images of the patient treated with anterior debridement, anterior start grafting and anterior CDH instrumentation. Postoperative AP (f), lateral (g) and final AP (h) and lateral (i) graphies of the patient.

Therefore, based on our results and those previously reported for the use of anterior instrumentation, it can be stated that anterior instrumentation in active tuberculosis spondylitis can be performed safely with few complications, and is effective in obtaining and maintaining the correction of the deformity as well as obviating the need for external support. The two major advantages of anterior instrumentation over posterior are the ability to perform the operation with a single approach, and to prevent the inclusion of unnecessarily large number of levels into fusion.

- Complications of surgical treatment:

Acute complications of surgical treatment include wound sepsis, pulmonary insufficiency, embolism, vascular injury, neural injury and deficit progression. In rare cases of tuberculosis, involvement of the adjacent aorta is discovered intraoperatively; in such cases segmental aorta replacement may be necessary under cardiopulmonary bypass^(30,65). Operative risk increases in elderly patients with extensive involvement. Tuberculous pulmonary or adrenal involvement may result in respiratory or adrenal insufficiency. Late complications include progressive kyphosis with or without graft resorption, failure and nonunion^(33,65).

- Prognosis:

With modern antibiotic regimens, early detection, and close follow-up, patient mortality has fallen to less than 5 %. Under similar condition, the relapse rate should approach zero^(37,39). Mortality with operative procedures is directly proportional to the severity of the neurological deficit: 2 % of those without neurological deficit, 6 % of those with moderate neurological deficit, and 11 % of those with a severe deficit, as reported in one series⁽⁶⁵⁾.

Neurological deficit may improve with combination with chemotherapy; however, the prognosis is improved with early surgery⁽⁶⁾. Postoperative neurological recovery is proportional to the duration and severity of preoperative paraplegia⁽²⁷⁾. In cases of prolonged paraplegia, documented recovery has occurred in neurological deficits present for as long as 5 years⁽²⁶⁾.

In patients with late-onset paraplegia, postoperative recovery of neurological deficit is more complete in cases with active disease versus those with healed disease and subsequent neurological deficit resulting from a hard, osseous defect⁽⁶⁵⁾.

Risk of progressive kyphosis is highest in cases with a large anterior defect requiring a graft spanning more than two disc spaces, lesions within the thoracic region, use of long rib strut grafts, and in patients with marked preoperative kyphosis⁽⁵⁹⁾. In cases of graft length exceeding two disc spaces, some authors recommend augmentation of anterior surgical treatment by prolonged bed rest, bracing, or posterior arthrodesis^(59,65). Children have a better prognosis than adults⁽⁶⁵⁾.

CONCLUSION

For patients without vertebral instability and deformity we prefer conservative management, and for those with additional abscess formation we use invasive radiological techniques in addition to abscess drainage and chemotherapy. It is our contention that, in patients with vertebral destruction and collapse, moderate-severe kyphotic deformity and large abscess formation, vertebral instability, neurological deficits and instability, anterior radical debridement, anterior strut grafting and anterior instrumentation is an optimal method. In patients with the involvement of different vertebral regions and multiple levels and in those global sagittal contours are mar-

edly deformed owing to local kyphosis, and in patients who have difficulty in undergoing anterior instrumentation due to lumbosacral junction involvement, posterior instrumentation may be preferred, after anterior radical debridement and anterior strut grafting at the same or subsequent session.

REFERENCES:

1. An HS, Vaccaro AR, Dolinkas CA, Cotler JM, Balderston RA, Bauerle WB. Differentiation between spinal tumors and infections with magnetic resonance imaging. *Spine* 1991; 16 (8 Suppl.): S333-S338.
2. Aksoy MC, Acaroglu RE, Tokgozoglu AM, Ozdemir N, Surat A. Retrospective evaluation of treatment methods in tuberculosis spondylitis. *Hacettepe J Orthop Surg* 1995; 5: 207-209.
3. Arthornthurasook A, Chongpieboonpatana A. Spinal tuberculosis with posterior element involvement. *Spine* 1990; 15: 191-194.
4. Aydın E, Kış M, Benli İT, Solak Ş, Gider M, Yücesoy C: Pott's disease. Retrospective evaluation of the results. *J Turkish Spine Surg* 1994; 5(4): 166-9.
5. Bailey HL, Gabriel M, Hodgson AR. Tuberculosis of the spine in children. Operative findings and results in one hundred consecutive patients treated by removal of lesions and anterior grafting. *J Bone Joint Surg*, 1972; 54-A (8): 1633-57.
6. Benhardt, M. Normal spinal anatomy: normal sagittal plane alignment. In: *The Text Book of Spinal Surgery*, Eds.: Bridwell, K.H., DeWald, R.L., Lippincott - Raven Publishers, Philadelphia, 1997, pp: 188-189.
7. Benli İT, Aydın E, Kis M, Akalin S, Tüzüner M, Baz AB. The results of anterior instrumentation in vertebral tuberculosis. *J Turkish Spine Surg* 1996; 7(3): 98-101.
8. Benli İT, Kis M, Akalin S, Çitak M, Kanevetci S, Duman E. The results of anterior radical debridement and anterior instrumentation in Pott's disease and comparison with other surgical techniques. *Kobe J Med Sci* 2000; 46: 39 – 68.
9. Benli İT, Acaroglu E, Akalin S, Kış M, Duman E, Un A. Anterior radical debridement and anterior instrumentation in tuberculous spondylitis. *Eur Spine J* 2002 (in press).
10. Berk RH, Yazıcı, Atabey M, Ozdamar OS, Pabuccuoglu U, Alıcı E. Detection of mycobacterium tuberculosis in formaldehyde solution – fixed, paraffin – embedded tissue by polymerase chain reaction in Pott's disease. *Spine* 1996; 21(17): 1991-5.
11. Boachie – Adjei O, Squillante RG: Tuberculosis of the spine. *Orthop Clin North Am*, 1996; 27 (1): 95-103.
12. Bosworth DM, Pietra AD, Farrel RF. Streptomycin in tuberculosis bone and joint lesions with mixed infection and sinuses. *J Bone Joint Surg* 1950; 132- A (1): 103-7.
13. Bradford DS, Daher YH. Vascular rib graft for stabilization of kyphosis. *J Bone Joint Surg* 1986; 68- B (3): 357-61.
14. Chan CM, Yuen KY, Chan KS, Yam WM, Yim KHM, Ng WF, Ng MH: Single tube nested PCR in the diagnosis of tuberculosis. *J Clin Pathol* 1996; 49 (4): 290-4.
15. Crubezy E, Ludes B, Poveda JD, Clayton J, Cro-uau-Roy B, Montagnon D: Identification of mycobacterium DNA in an Egyptian Pott's disease of 5400 years old. *C R Acad Sci III*, 1998; 321(11): 941-51.
16. Desai SS. Early diagnosis of spinal tuberculosis by MRI. *J Bone Joint Surg* 1994; 76-B (6): 863-869.
17. Dobson J. Tuberculosis of the spine. An analysis of the results of conservative treatment and of the factors influencing the prognosis. *J Bone Joint Surg* 1951; 33- B: 517.
18. Dominic U, Hamzaoglu A, Sar C, Yavuzer Y. Posterior fusion and instrumentation after anterior radical debridement and fusion in the surgical treatment of Pott's disease. *J Turkish Spine Surg* 1993; 4 (1): 16-19.
19. Eldin BR, Valway SE, Onorato IM. Cluster of multidrug-resistant tuberculosis. *Ann Int Med* 1993; 118: 77.

20. Ellinas PA, Rosner F. Pott's disease in urban populations. A report of five cases and review of the literature. *NY State J Med*, 1990; 90 (12): 588-91.
21. Govender S, Parbhoo AH. Support of the anterior column with allograft in tuberculosis of the spine. *J Bone Joint Surg* 1999; 81-B (1): 106-9.
22. Guven O, Kumano K, Yasin S, Karahan M, Tsuji S. A single stage posterior approach and rigid fixation for preventing kyphosis in the treatment of spinal tuberculosis. *Spine* 1994; 19: 1039-1043.
23. Herring JA (Ed.) Tachdjian's Pediatric Orthopedics from the Texas Scottish Rite Hospital for Children. 3rd Edition, W.B. Saunders Company, Philadelphia, 2002, pp: 1831-1836.
24. Hodgson AR, Stock FE, Forg HSY, Ong GB. Anterior spinal fusion: the operative approach and pathological findings in 412 patients with Pott's disease of the spine. *Br J Surg* 1960; 48: 172-178.
25. Hodgson AR, Yau A. Pott's paraplegia: a classification based upon the living pathology. *Paraplegia* 1967; 5 (1): 1-16.
26. Hodgson AR, Skinsnes OK, Leong CY. The pathogenesis of Pott's paraplegia. *J Bone Joint Surg*, 1967; 49-A (6): 1147-56.
27. Hodgson AR, Stock FE. Anterior spinal fusion. A preliminary communication on the radical treatment of Pott's disease and Pott paraplegia. *Clin Orthop* 1994; 300: 16-23.
28. Hoffman EB, Cruiser JH, Cremin BJ. Imaging in children with spinal tuberculosis. A comparison of radiography, computed tomography and magnetic resonance imaging. *J Bone Joint Surg* 1993; 75-B (2): 233 - 239.
29. Hopf C, Eysel P, Dubousset J. CDH: Preliminary report on new anterior spinal instrumentation. *Eur Spine J* 1995; 4: 194-199.
30. Hsu LC, Cheng CL, Leong JC. Pott's paraplegia of late onset: The cause of compression and results after anterior decompression. *J Bone Joint Surg* 1988; 70-B: 534-538.
31. Janssens JP, de Haler R. Spinal tuberculosis in a developed country. A review of 26 cases with special emphasis on abscess and neurologic complications. *Clin Orthop*, 1990; 257:67-75.
32. Journeau P, Koura A, Mary P, Padovani JP, Touzet P: Pott's disease paraplegia in children. Mechanics and therapeutics strategies. *Rev Chir Orthop Reparatrice Appar Mot* , 1999; 85 (2): 117-24.
33. Kempf HBS, Jackson JW, Jeremiah JD, Cook J. Anterior fusion of the spine for infective lesions in adults. *J Bone Joint Surg* 1973; 55-B: 715-734.
34. Kim NH, Lee DHM, Choi CH, Park SJ. The comparison of the fusion rate in anterior interbody fusion between noninfectious and infectious disease of the spine. *J Turkish Spine Surg* 1994; 5(2): 49-58.
35. Korkusuz F, Islam C, Korkusuz Z. Prevention of postoperative late kyphosis in Pott's disease by anterior decompression and intervertebral grafting. *World J Surg* 1997; 21(5): 524-528.
36. Kostuik JP. Anterior spinal cord decompression for lesions of the thoracic and lumbar spine: Techniques, new methods of internal fixation. *Spine* 1983; 8: 512-531.
37. Levine MJ, Heller JG. Spinal infection. In: Orthopedics Knowledge Update. Spine. Garfin SR, Vaccaro AR (eds.), American Academy of Orthopaedic Surgeon, Rosemont, 1997, s: 261-3.
38. Loembe PM. Medical - surgical treatment of progressive tuberculous (Pott's) paraplegia in Gabon. *Paraplegia* 1995; 33 (10): 579-584.
39. Luk KDK: Tuberculosis of the spine in the new millennium. *Eur Spine J*, 1999; 8(5): 338-45.
40. Louw JA. Spinal tuberculosis with neurologic deficit. Treatment with anterior vascularized rib graft posterior osteotomies and fusion. *J Bone Joint Surg* 1990; 72-B (4): 686-93.
41. Mallet JF, Rigault P, Padovani JP, Pouliquen JC, Finidori G, Touzzet P, Tanguy D. Kyphosis caused by severe spondylodiscitis in newborn infants and young children. *Rev Chir Orthop Reparatrice Appar Mot* 1984; 70 (1): 63-73.
42. Medical Research Council Working Party on Tuberculosis of the Spine. A controlled trial of anterior spinal fusion and debridement in the surgical management of tuberculosis of the spine in patients on standard chemotherapy. A study in Hong Kong. *British J Surg* 1974; 61: 853-866.

43. Medical Research Council Working Party on Tuberculosis of the Spine. Five-year assessments of controlled trials of ambulatory treatment, debridement and anterior spinal fusion in the management of tuberculosis of the spine: Studies in Bulawayo (Rhodesia) and in Hong Kong. *J Bone Joint Surg* 1978; 60-B: 163-177.
44. Medical Research Council Working Party on Tuberculosis of the Spine. A ten-year assessment of a controlled trial comparing debridement and anterior spinal fusion in the management of tuberculosis of the spine in patients on standard chemotherapy in Hong Kong. *J Bone Joint Surg* 1982; 64-B : 393-398.
45. Medical Research Council Working Party on Tuberculosis of the Spine. A ten-year assessment of a controlled trial of plaster - of - paris jackets for tuberculosis of the spine in children on standard chemotherapy in Hong Kong. *J Bone Joint Surg* 1985; 67-B (1): 103-10.
46. Medical Research Council Working Party on Tuberculosis of the Spine. A 15 - year assessment of controlled trials of the management of tuberculosis of the spine in Korea and Hong Kong. Thirteenth Report of the Medical Research Council Working Party on Tuberculosis of the Spine. *J Bone Joint Surg* 1998; 80-B (3): 456 - 462.
47. Medical Research Council Working Party on Tuberculosis of the Spine. Five-year assessment of controlled trials of short - course chemotherapy regimens of 6, 9 or 18 months' duration for spinal tuberculosis in patients ambulatory from the start or undergoing radical surgery. Fourteenth report of the Medical Research Council Working Party on Tuberculosis of the Spine. *Int Orthop* 1999; 23(2):73-81.
48. Menard V. Causes de paraplegia dans le mal de Pott. Son traitement chirurgical par l'ouverture directe du foyer tuberculeux des vertèbres. *Revue d'Orthopedie* 1894; 5 : 47.
49. Moon MS, Woo YK, Lee KS, Ha KY, Kim SS, Sun DH. Posterior instrumentation and anterior interbody fusion for tuberculosis kyphosis of dorsal and lumbar spines. *Spine* 1995; 20: 1910-1916.
50. Moon MS, Ha KY, Sun DH, Moon JL, Moon YW, Chung JH. Pott's paraplegia-cases. *Clin Orthop*, 1996; 323:122 –8.
51. Moon M S. Spine update: tuberculosis of the spine. *Spine* 1997; 22 (15): 1791-1797.
52. Moula T, Fowles JV, Kassab MT, Sliman N. Pott's paraplegia: a clinical review of operative and conservative treatment in 63 adults and children. *Int Orthop* 1981; 5 (1): 23-29.
53. Mushkin AY, Kovalenko KN. Neurologic complications of spinal tuberculosis in children. *Int Orthop* 1999; 23(4): 210-2.
54. Nemir RL, Krasinski K. Tuberculosis in children and adolescents in the 1980s. *Pediatr Infect Dis J* 1988; 7 (6): 375-379.
55. Oga M, Arizono T, Takasita M, Sugioka Y. Evaluation of the risk of instrumentation as a foreign body in spinal tuberculosis: Clinical and biologic study. *Spine* 1993; 18: 1890-1894.
56. Pathasarathy R, Siririm K, Santha T, Poranbkar R, Somasundaram PR, Sivasubramanian S. Short – course chemotherapy for tuberculosis of the spine. A comparison between ambulant and radical surgery: ten years report. *J Bone Joint Surg* 1999; 81-B (3): 464-71.
57. Pattison PR. Pott paraplegia: an account of the treatment of 89 consecutive patients. *Paraplegia* 1986; 24 (2): 77- 91.
58. Pierre C, Lecossier D, Bousougant Y, Bocart D, Joly V, Yeni P, et al. Use of a reamplification protocol improves sensitivity of detection of mycobacterium tuberculosis in clinical samples by amplification of DNA. *J Clin Microbiol* 1991; 29 (4): 712-7.
59. Rajasekaran S, Soundarapandian S. Progression of kyphosis in tuberculosis of the spine treated by anterior arthrodesis. *J Bone Joint Surg* 1989; 71-A: 1314-1323.
60. Rajeswari R, Ranjani R, Santha T, Sriiam K, Prabhakar R. Late onset paraplegia: a sequel to Pott's disease. A report on imaging, prevention and management. *Int J Tuberc Lung Dis* 1997; 1(5): 468-73.

61. Rezai AR, Lee M, Cooper PR, Errico TJ, Koslow M. Modern management of spinal tuberculosis. *Neurosurgery* 1995; 36 (1): 87-97.
62. Sapico FL, Montgomerie JZ. Vertebral Osteomyelitis. *Inf Dis Clin North Am* 1990; 4: 539.
63. Schimitz A, Kalicke T, Willkomm P, Grunwald F, Kandyba J, Schimitt. Use fluorine - 18 flouro - 2 - deoxy - D - glucose positron emission tomography in assessing the process of tuberculous spondylitis. *J Spinal Disord* 2000; 13(6): 541-544.
64. Schulitz KP, Kothe R, Leong JCY, Wehling P. Growth changes of solid fusion kyphotic bloc after surgery for tuberculosis. *Spine* 1997; 22 (10): 1150-1155.
65. Slucky AV, Eismont FJ. Spinal infections. In: Bridwell KH, DeWald RL, Eds., *The Textbook of Spinal Surgery*, Lippincott - Raven Publishers, Philadelphia, 1997, pp : 2141-2183.
66. Srivastava S, Sanghavi NG: Non-traumatic paraparesis: aetiological, clinical and radiological profile. *J Assoc Physicians India* 2000; 48 (10): 988-90.
67. Tuli SM. Current concepts. Severe kyphotic deformity in tuberculosis of the spine. *Int Orthop* 1995; 19: 327-331.
68. Upadhyay SS, Saji MJ, Sell P, Sell B, Hsu LCS. Spinal deformity after childhood surgery for tuberculosis of the spine. A comparison of radical surgery and debridement. *J Bone Joint Surg* 1994; 76-B: 91-98.
69. Upadhyay SS, Sell P, Saji MJ, Sell B, Hsu LC. Surgical management of spinal tuberculosis in adults: Hong Kong operation compared with debridement surgery for short and long term outcome of deformity. *Clin Orthop Rel Res* 1994; 302: 173-182.
70. Upadhyay SS, Saji MJ, Sell P, Yau ACMC. The effect of age on the change in deformity after radical resection and anterior arthrodesis for tuberculosis of the spine. *J Bone Joint Surg* 1994;76-A:701-708.
71. Upadhyay SS, Saji MJ, Yau ACMC. Duration of Anti tuberculous chemotherapy in conjunction with radical surgery in the management of spinal tuberculosis. *Spine* 1996; 21: 1898-1903.
72. Wolinsky E. Tuberculosis. In: *Cecil's Textbook of Medicine*. Goldman L., Bennett JC (Eds.). 21st Edition, WB Saunders Company, Philadelphia, 2001, pp: 1620-1630.
73. Yau ACMC, Hsu LCS, O'Brien JP, Hodgson AR. Tuberculosis kyphosis: correction with spinal osteotomy halo pelvis distraction and anterior and posterior fusion. *J Bone Joint Surg* 1974; 56-A: 1419-1434.
74. Yilmaz C, Selek HY, Gurkan I, Erdemli B, Korkusuz Z. Anterior instrumentation for the treatment of spinal tuberculosis. *J Bone Joint Surg* 1999; 81-A (9): 1261-1267.
75. Zdeblick TA (1996). Thoracolumbar fractures. New anterior instrumentation. *American Academy of Orthopaedic Surgeons Annual Meeting*, February 22 - 26, Atlanta, Georgia.
76. Zimmerman MR: Pulmonary and osseous tuberculosis in an Egyptian mummy. *Bull N Y Acad Med*, 1979; 55(5): 604-8.

Address for correspondence and reprint requests:

İ. Teoman Benli
Mithatpaşa Cad., 59 / 2,
Kızılay / Ankara
Tel.: 0312 435 09 14
e-mail: cutku@ada.net.tr