

DIAGNOSIS AND MANAGEMENT OF COMMON PRIMARY BENIGN SPINAL TUMORS

Önder OFLUOĞLU¹, Ender SARIOĞLU¹

ABSTRACT

Primary tumors of the spine are uncommon and comprise less than 10% of all bone tumors. Patients with primary benign tumors of the spine usually present longstanding history of symptoms. Most consistent complaint is pain. If tumor mass encroaches to medullary canal or spinal roots neurological symptoms may occur. Complete imaging studies including conventional x-rays, computerized tomography, magnetic resonance imaging and bone scan are obtained for diagnosis, staging and accurate surgical planning. Biopsy is necessary in case of any suspected malignancy or unknown nature of the lesion except for certain tumors such as osteoid osteoma, osteochondroma or hemangioma when diagnosis can be based on typical radiographic appearance. Most lesions of the vertebral column are sampled by using core-needle or tru-cut biopsy techniques under CAT control. Treatment of benign spinal tumors is based on histological type, size and location of the tumor and accompanying symptoms which varies from intralesional curettage to wide resection. Preoperative selective arterial embolisation is very helpful to decrease intraoperative bleeding in hypervascular tumors such as giant cell tumor or aneurysmal bone cyst. Role of radiotherapy is limited only to surgically inaccessible lesions.

Key words: Spinal neoplasm, spinal tumors, bone tumors, spinal mass

ÖZET

Omurganın primer tümörleri nadir görülürler ve tüm kemik tümörlerinin yüzde onundan azını oluştururlar. Benign primer omurga tümörü olan hastalarda yakınmalar uzun sürelidir, en belirgin semptom ağrıdır. Tümör kitlesi spinal kanala yada köklere doğru gelişirse nörolojik semptomlar da ortaya çıkabilir. Tanı, evreleme ve cerrahi planlama için konvansiyonel radyografiler, bilgisayarlı tomografi, manyetik rezonans görüntüleme ve kemik sintigrafisini içeren tam bir görüntüleme çalışması yapılmalıdır. Osteoid osteoma, osteokondrom veya hemanjiom gibi radyolojisi tipik olan tümörler dışında, herhangi bir malignite şüphesi varsa yada tümörün tipi bilinmiyorsa biyopsi gereklidir. Omurganın bir çok lezyonu bilgisayarlı tomografi altında trokar yada "tru-cut" biyopsi yöntemiyle örneklenebilir. Tedavi tümörün tipi, türü boyutları ve eşlik eden semptomlara göre intralezyonel küretajdan geniş rezeksiyona kadar değişen bir yaklaşımı içerir. Özellikle dev hücreli tümör, anevrizmal kemik kisti gibi aşırı vasküler lezyonlarda ameliyat öncesi selektif arteriyel embolizasyon, ameliyat sırasındaki kanamayı ciddi olarak azaltabilir. Cerrahi olan ulaşılması güç bölgelerde veya aşırı cerrahi morbidite oluşacak hastalarda bazı tümörlerde radyoterapi tümör kontrolünü sağlayabilir.

Anahtar Kelimeler: Omurga tümörleri, kemik tümörleri, omurga kitlesi.

¹ Vice Chair, Department of Orthopedics and Traumatology Lutfi Kırdar Training and Research Hospital, Istanbul, Turkey.

Introduction

In contrast to metastatic lesions, primary tumors of the spine are uncommon and comprise less than 10% of all bone tumors. Primary benign spinal tumors frequently affect children and young adults. Unlike the patients with malign spinal tumors who are about 50 years of age or older, patients with primary benign tumors are usually younger than 20 years of age^(4, 8). Symptoms of benign spinal tumors are insidious and longstanding. Most consistent complaint is pain which is found approximately in 85% of patients^(8, 13). The pain associated with tumors tends to be progressive and persistent rather than self-limited character. Causes of the pain are expansion of tumor mass into vertebral body cortex, or pathological fracture or invasion of the Para vertebral soft tissues by tumor. As the cortex expands, the periosteum is stretched and stimulates pain receptors. Every patient must be asked individually and carefully about pain to differentiate the mechanical spinal conditions. Night pain or pain unrelated to activity may suggest that tumoral condition rather than mechanical in nature. However, activity related pain may be result of the development of spinal instability secondary to collapse of the vertebral body by tumor⁽³¹⁾. Radicular symptoms are less common, but may be seen in patients with cervical or lumbar involvement. It may indicate the pathologic fracture or local invasion of tumor tissue into adjacent nerve roots. Although a neurologic deficit is frequently associated with rapidly expanding malignant tumors, any benign neoplasm may produce neurologic deficits if it has enough time to grow.

Every patient with a suspected spinal column tumor must have a complete set of high quality x-ray. In almost all primary tumors, lesions could be visible on routine spine x-rays^(8, 18). Routine roentgenograms can provide considerable information about the nature of the lesion and is still best met-

hod in differential diagnosis in spite of more sophisticated imaging methods has been developed. Localization of the tumor in spinal elements is also important. Most of the tumors affecting the posterior elements of the vertebra are benign, while the lesions involves the vertebral body can be benign or malignant. Although destruction of vertebral bodies and pedicle commonly occurs in malign conditions, it may also be resulted from locally aggressive benign tumors. Destructive lesions not commonly visible on x-rays until 30% to 50% trabecular bone has been destroyed^(12, 31).

Bone scan have proven feasible and useful in locating the small but symptomatic benign neoplasm in spine which are not always radiologically apparent, and can significantly improve the efficacy of treatment by providing earlier diagnosis. The bone scan is highly sensitive to identify osteoblastic benign lesions such as osteoid osteoma and osteoblastoma. Blood pool images are particularly important in neoplastic diseases. The scans including pinhole magnification images, is especially valuable in diagnosis of the primary bone tumors of the spine and pelvis which are poorly seen at the early stage of the disease in x-rays roentgenograms⁽¹¹⁾.

Computerized axial tomography (CAT) is also useful method especially to demonstrate the extent and amount of bony destruction. Comparing with MRI which may exaggerate the bony involvement and medullary changes in bone tumors, CAT is very helpful in surgical planning when determining the real margins of the bony lesion.

Magnetic resonance imaging (MRI) has several advantages as compared any other imaging techniques such as three-dimensional imaging, better differentiation between various tissues, useful in measuring the extent of the tumors extended to soft tissues. MRI is the primary imaging study for anatomic definition of spinal tumors. In most cases MRI provide to asses nerve root and

spinal cord compression as reliable, safe and non-invasive imaging modality. The use of contrast-enhanced magnetic resonance imaging scans and serial magnetic resonance imagings are helpful for additional differentiation between benign and malignant compression fractures. ⁽¹⁾

Similar to the extremities, carefully planned biopsy should follow the imaging studies in patients who have suspected spinal lesion. Biopsy is not necessary in certain tumors such as osteoid osteoma, osteochondroma or hemangioma when diagnosis can be based on typical radiographic appearance. Most lesions of the vertebral column are sampled by using core-needle or tract biopsy techniques under CAT control. If needle biopsy is not diagnostic, open biopsy are indicated. However the risk of contamination by tumor cells in biopsy tract may complicate definitive surgical treatment or result with significant morbidity. For tumors localized on vertebral body transpedicular approach and filling the empty pedicle with bone cement is the useful method to decrease tumor spread. ⁽³⁾

After complete preoperative evaluation including imaging techniques and pathological investigation, spinal tumors must be classified and staged for accurate management. Enneking developed the oncologic staging system based on clinical behavior and pathological observation of tumors⁽⁹⁾. This system divides the benign tumors into three stages S1, S2 and S3 and each stage describes latent, active and aggressive tumors, respectively. Stage 1 tumors are inactive and asymptomatic. These lesions are circumscribed by well-defined margin and show no or very slow growing. No treatment is necessary for S1 lesions. Stage 2 tumors are active and slowly growing lesions characterized by increased uptake on bone scan. These tumors are treated by intralesional excision with local adjuvants. S3 tumors describe rapidly growing lesions which may inva-

de surrounding structures. Aggressive character of these tumors are clearly seen at CAT and MRI studies and supported by prominent uptake on bone scan. S3 lesions are treated by wide excision, if possible, to decrease the rate of recurrence. ⁽³⁾

Primary Benign Tumors

The most frequently seen benign tumors in spine include hemangioma, osteochondroma, osteoid osteoma, osteoblastoma, giant cell tumor, aneurismal bone cyst and eosinophilic granuloma.

Hemangioma

Hemangiomas are common and usually incidental findings seen in up to 10% of normal people. Widespread use of MRI has increased the detection of the small, asymptomatic hemangiomas of the spine. Vertebral hemangioma is prevalent in the thoracic and lumbar spine, always involves the vertebral body but occasionally may extend into the posterior elements via the pedicles⁽⁴⁾. When sufficiently large, they are visible on plain x-rays and most common radiographic sign is a "striated vertebrae". These vertical striations within the vertebral body are due to rarefaction of bone trabeculae. The radiographic picture of the patient with neurological symptoms is the honeycomb aspect of vertebral body with vertebral expansion and/or collapse, which demonstrate the proliferation and expansion of tumor to the medullary canal or roots⁽⁵⁾. Signal characteristics of hemangiomas on MRI are diagnostic. These well-defined, often lobular lesions occur within vertebral bodies and are hyperintense in both T1 and T2 images ⁽¹²⁾. Reports of deformity or pain due to hemangioma are uncommon. However, in some cases extension of soft tissue with cord compression have been documented. The 12%

of hemangiomas lie at the epidural space and causing acute neurologic symptoms by enlargement or spontaneous bleeding^(12, 17). When symptomatic, these lesions frequently respond to low-dose radiation alone. When cord compression develops and surgical treatment is considered, preoperative angiography and selective embolisation of feeding vessels is highly recommended to minimize intraoperative blood loss. The management of such cases should also include surgical decompression with the approach determined by the degree of vertebral involvement and site of spinal cord compression. Post surgical radiotherapy has also been demonstrated beneficial as an adjuvant to the surgery by reducing tumor recurrence if there is incomplete tumor resection⁽¹⁰⁾.

Osteoid Osteoma

Osteoid osteoma is a small size, usually less than 2 cm in diameter, benign tumor, and characterized by osteoid tissue surrounded by marked reactive bone formation. It is almost always painful lesion. It has a peak incidence between the ages of 6 and 17 years. It represents 11% of all primary tumors and 10% to 25% of osteoid osteoma occur in the spine. It is most common cause of painful scoliosis in adolescent patients. In the vertebral column it is predominantly localized at lumbar region and frequently found in the pedicles as well as the posterior elements, facets joints and transverse processes. They occasionally arise in the vertebral body^(4, 15, 22).

The symptoms of patients with osteoid osteoma are constant back pain, marked spinal stiffness, muscular spasm and scoliotic deviation. A positive Laseque test with no sign of nerve root compression is also found^(2, 5, 15).

The pain is not related with activity and typically more intense during the night. It is often

exacerbated with consumption of alcoholic beverages, probably due to the vasodilatation⁽⁵⁾. Pain often regress dramatically with aspirin and other nonsteroidal antiinflammatory drugs, however, failure to relieve pain with this drugs does not exclude the diagnosis. Scoliosis in these patients is induced by muscle spasm due to an inflammatory reaction around the tumor^(22, 25). The tumor always located on the concave site of the deformity and usually at the apex of the curve. Scoliosis will spontaneously correct if surgical excision was performed in early period after onset of the symptoms. However, most of the patient with long duration of symptoms did not have improvement of the scoliosis due to damage of the growth plate on the concave site or degeneration and fibrosis of muscle by chronic inflammation^(24, 25). In cervical involvement, it is associated with torticollis rather than scoliosis.

Radiographic demonstration of nidus can be difficult in the spine because of the lesion is usually less than 2 cm in diameter and easily obscured among the overlapping shadows of the posterior elements of the vertebral column. The most sensitive test for location of nidus is technetium bone scan. CT scans can also demonstrate and localize the radiolucent nidus surrounded with dense sclerotic reactive bone.

Differential diagnosis of osteoid osteoma includes the lesions which cause focal sclerosis in spine. Pseudotumors such as bone island and Paget's disease, tuberculosis, metastatic lesions representing sclerosis such as prostate and breast carcinoma, hematologic malignancies like Hodgkin's disease and lymphoma, and primary tumors such as osteoblastoma, osteosarcoma, Ewing's tumor and chordoma are taken into consider in differential diagnosis⁽¹⁵⁾.

Of those, osteoblastoma is considered as giant osteoid osteoma and both tumors are bone-forming lesions producing osteoid and woven bo-

ne, and histologically similar in many regards⁽²⁰⁾. Unni described that the lesions greater than 1, 5 cm in diameter is osteoblastoma⁽²⁹⁾.

The management osteoid osteoma consists of complete excision of the nidus. Incomplete resection usually fails to resolve the patient's pain and may require repeating operative intervention⁽²²⁾. Intraoperative identification of the nidus is sometimes difficult even though x-ray amplifier is used. Radiotherapy is another treatment choice but should be reserved for patients in whom complete removal of the tumor is impossible. If radiotherapy is done, its potential risk, including post irradiation sarcomas must be considered especially in younger age group of patients. In recent years percutaneous ablation of osteoid osteoma became the popular treatment option. It has been reported that minimally invasive surgery by CT guided percutaneous radiofrequency ablation, thermo- and laser coagulation is effective method if the nidus is not adjacent to the neural structures⁽²⁷⁾.

Osteoblastoma

Osteoblastoma is also benign tumor, producing osteoid and bone. In most cases it is differentiated from osteoid osteoma by its history, size and clinical course. Peak incidence of osteoblastoma is between the ages of 10 and 15 years. Osteoblastoma account for 5% of all primary bone tumors shows evident predilection for the vertebral column and the sacrum. Forty percent of osteoblastomas occur in the spine, generally in the posterior elements but can also occur in the ribs and transverse process.⁽⁵⁾

The primary complaint of patient with osteoblastoma is pain which is characterized by various intensity and long duration. The pain is effectively relieved by aspirin as it happens in osteoid osteoma. Painful scoliosis is present in 2/3 of patients

in spinal cases. In comparison to the osteoid osteoma, osteoblastoma tend to be more aggressive. They show growth tendency to the point of encroaching on the spinal canal and causing neurologic deficits. As reported by Boriani et al 75% of patients with thoracic lesions may be complicated by paraparesis⁽²⁾. Thoracic lesions seem to causing more severe neurologic symptoms^(2, 22).

The radiographic picture varies from case to case, and depending on the progression of the tumor. The major finding is a generally single and roundish area of osteolysis which is surrounding by moderate reactive bone formation. Calcifications are present in about one third of patients⁽¹²⁾. Osteoblastoma often extends paraspinally, invading paravertebral soft tissues. In some cases extension into the vertebral body can be seen.

Treatment consists of complete surgical excision with fusion or stabilization if required after the tumor resection. Incomplete resection may lead to recurrence which rates approach 10%. In some cases, especially in locally aggressive osteoblastomas, may metastasis to the lung. As osteoblastoma is a hypervascular tumor, selective arterial embolisation may be useful prior to surgery to reduce intraoperative bleeding, and make a complete resection more feasible⁽²⁾.

Osteochondroma

Osteochondromas are common tumors of bone that may arise from any zone of enchondral bone formation. They represent 9.3 % of all bone tumors and 40 % of all benign tumors. They represents as solitary or multiple forms. Later may appears sporadically or as part of genetic disorder described as hereditary multiple exostosis. In most cases osteochondromas involves the long bones. Spinal involvement is unusual with an incidence of 1.3% to 4.1 % and at this site they represent only 3.9 % of the solitary tumors of the spi-

ne.^(19,25) Seven to nine percent of the patients with hereditary multiple exostosis have spinal involvement.⁽¹⁵⁾ Spinal cord involvement is rarely seen. Approximately in half of the cases it is localized to cervical spine. Dysphagia or compression of neurovascular structures may develop if there is anterior cervical involvement. They typically appear as a well corticated bone mass arising from the surface of the vertebra. Sclerotic changes of the adjacent bone may be seen. At MRI a thin cartilaginous cap with high signal in T2-weighted images may be present especially in children. Fig 3 Although sarcomatous transformation occurs in less than 1 % of cases, cartilaginous cap thicker than 1 cm in the adult should raise a suspicion for malignant degeneration. Symptomatic cases due to local compression of soft tissues or of course any sign or suspect regarding malignant transformation is addressed to surgical treatment.

Eosinophilic Granuloma

Eosinophilic Granuloma is a rare reticuloendothelial system disorder. There is no known cause in the etiology. It is a benign tumor-like condition with a variable clinical course. The characteristic of eosinophilic granuloma is the proliferation and accumulation of the specific histiocyte: the Langerhan's cell. The clinical syndromes range from isolated lesions to multiple lesions seen in Hand-Schuller-Christian disease or more fulminant Letterer-Siwe disease. It is most commonly seen in children younger than 10 years of age. Vertebral involvement occurs in approximately 7.8 % to 15 % of cases and vertebral body usually affected. Patients usually complain of pain and local muscular spasm, which may lead to torticollis in some cases^(12, 31). Vertebral collapse may lead to neurological symptoms that might be severe.

The radiographic appearance is determined by patient's age, and clinical course. In younger children the lesion is usually solitary and can in-

volve the whole vertebral body with massive destruction and vertebral collapse ('coin lesion') but this appearance is not pathognomonic. The vertebral body may be reduced to a lamina which is thinner than disc ("vertebra plana"). In older children with more mature and powerful vertebral elements, the destruction may be focal, mild to moderate kyphosis is observed. CT and MR imaging are very useful in providing detailed cross-sectional anatomic detail of the involved bone, including the bone marrow and the adjacent soft tissues. CT scan is more suitable for demonstrating bone detail and MR imaging for bone marrow and soft-tissue involvement (Fig -2).

The differential diagnosis includes osteomyelitis, leukemia, lymphoma, metastasis and Ewing's sarcoma. Preservation of the general condition of the patient and absence of paraspinous mass in most cases help in differential diagnosis from Ewing's sarcoma, lymphoma and other malignant conditions⁽¹⁵⁾. Diagnosis should be confirmed by biopsy. Total body scan is indicated to exclude multiple localizations.

Treatment is controversial, because complaints and clinical course of the disease change for every case. In many patients lesions heal spontaneously without any treatment. Especially for solitary lesions, spontaneous evolution is favorable and flattened vertebral bodies regain their height at least partially. Local corticosteroid injection after frozen section analysis may also be useful in some patients, whereas in the presence of neurologic deficit, surgical excision is indicated. Percutaneous vertebroplasty with acrylic cement in the treatment of eosinophilic granuloma also reported but this technique should be performed only on adult patients⁽⁷⁾.

Aneurismal Bone Cyst

Aneurismal bone cyst (ABC) is a pseudotumoral lesion of bone, which is expensive and

hyperemic, frequently initiating from the surface of the bone. Although it may be observed in any age, it distinctly predominates from 5 to 20 years of age with slight female predominance⁽⁵⁾. It is thought that ABC is the result of a trauma or tumor induced low circulatory disturbance. Later is supported by coexistence of ABC with other tumors like giant cell tumor or osteoblastoma in one third of the cases⁽¹⁵⁾. In spinal localization, it is found generally in a thoracolumbar spine and involving the posterior elements in approximately 60% of cases. These lesions have a tendency to involve the adjacent vertebrae, and may involve three or more vertebrae in sequence⁽³¹⁾.

Pain and swelling are the mains symptoms. Neurologic symptoms results of the myelo-radi-cular compression by tumor mass tend to be progressive. In some cases, neurologic deficit initiate suddenly due to the collapse of the vertebral body or acute bleeding of the tumor into the spinal canal may even be resulted with paraplegia.

Typical radiologic signs of the aneurismal bone cyst on the plain x-rays are the expansive cavity with an eggshell-thin cortex. As with osteoblastoma, lesions are osteolytic and surrounding with a reactive bone. However, aneurismal bone cysts typically have fine osseous septae which is filled by blood, giving them a soap bubble appearance⁽¹²⁾. MRI finding is typically shows fluid-fluid levels which is characteristic, but not pathognomonic, in appearance. (Fig 1- A- B)

The surgical excision is the optimal treatment choice. Aneurismal bone cysts are highly vascular tumor, which may lead a significant intraoperative bleeding. In recent years, selective arterial embolisation has become more preferable treatment method, capable of healing or at least involuting the cyst, or reducing intraoperative blood loss. Ozaki et al⁽²¹⁾ reported that radical resection of the aneurismal bone cyst of the spine with the

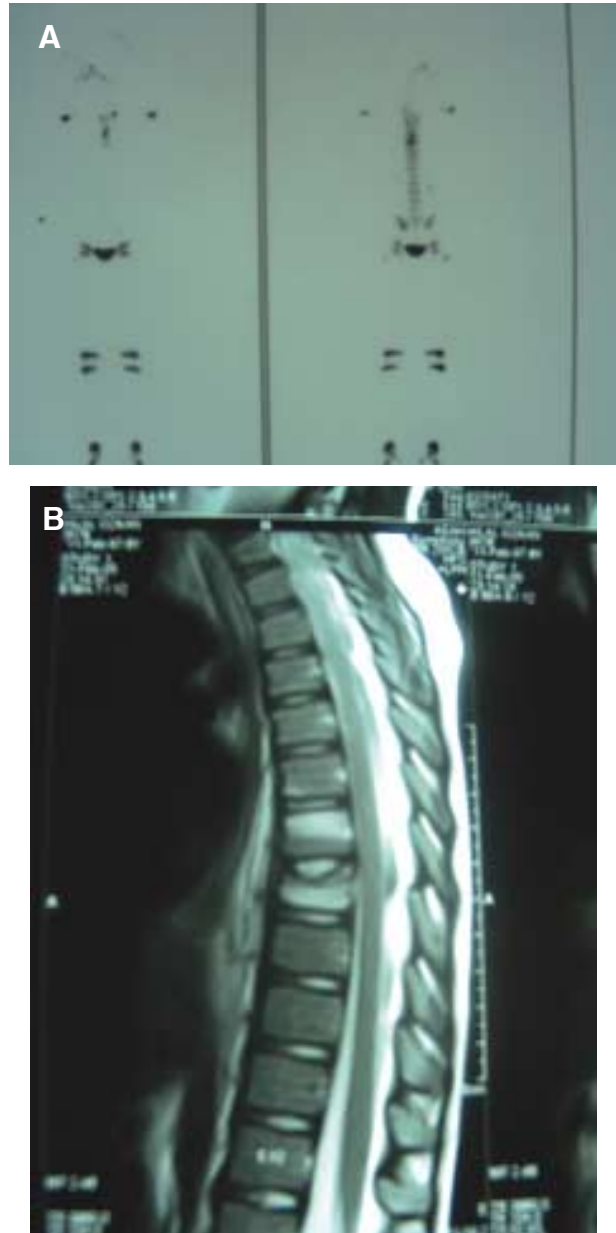


Fig 1 - Eosinophilic granuloma with multiple involvements in 9 year old girl.
A- Increased uptake at middle thoracal region as well as right medial end of the clavicle at bone scan
B-Sagittal MR image shows increased signal and vertebral collapse at involved vertebrae with some soft tissue extension into medullary canal.

instrumentation is the optimal method of acquiring a high degree of local control and preventing spinal deformity. Radiation therapy must be limited to inoperable patients even good results are

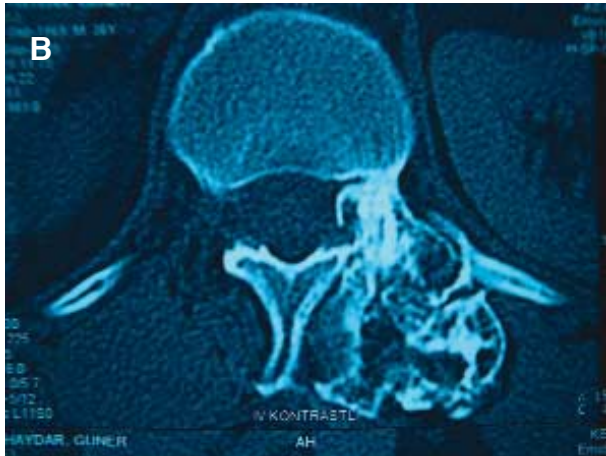
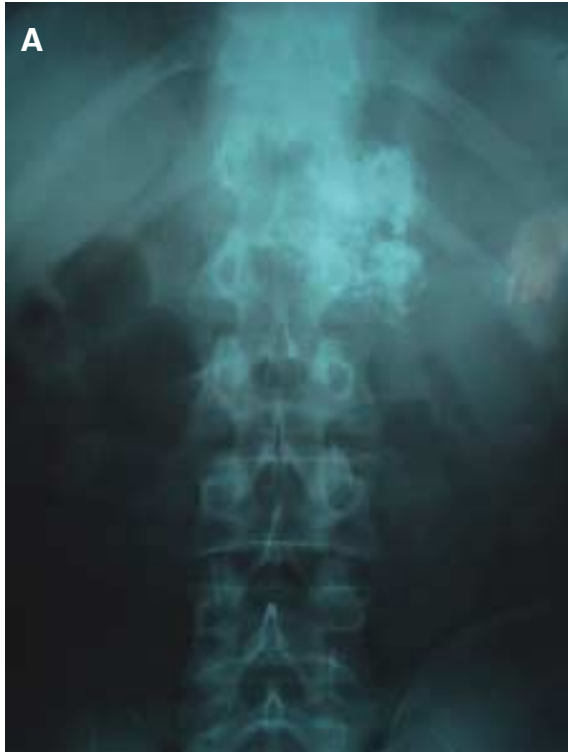
Fig 2- Osteochondroma of 12th thoracic vertebra in 30 y/o male.
A- AP and B-lateral X-rays showing large paravertebral calcified mass.
B- CAT scan showing that the lesion originated from pedicle and extending para spinal area. Well demarcated solid peripheral cortex is clearly seen.

obtained, because of significant risk of the radiation-induced sarcoma.

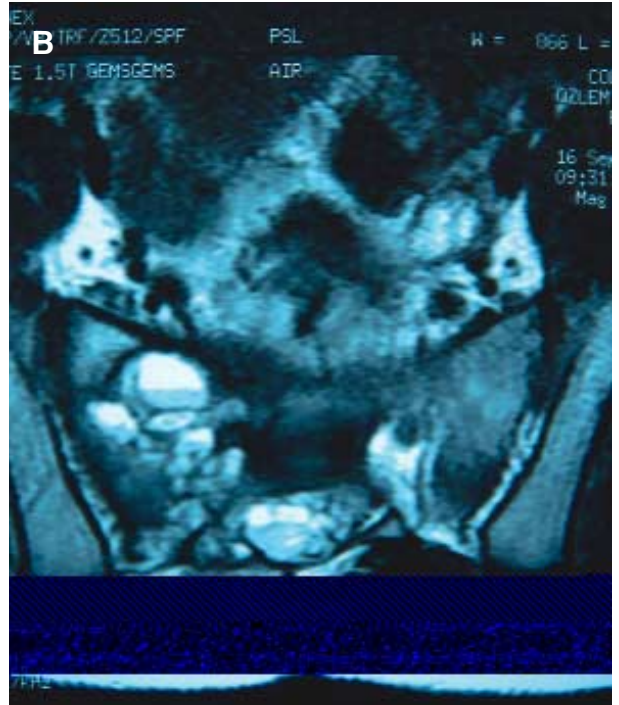
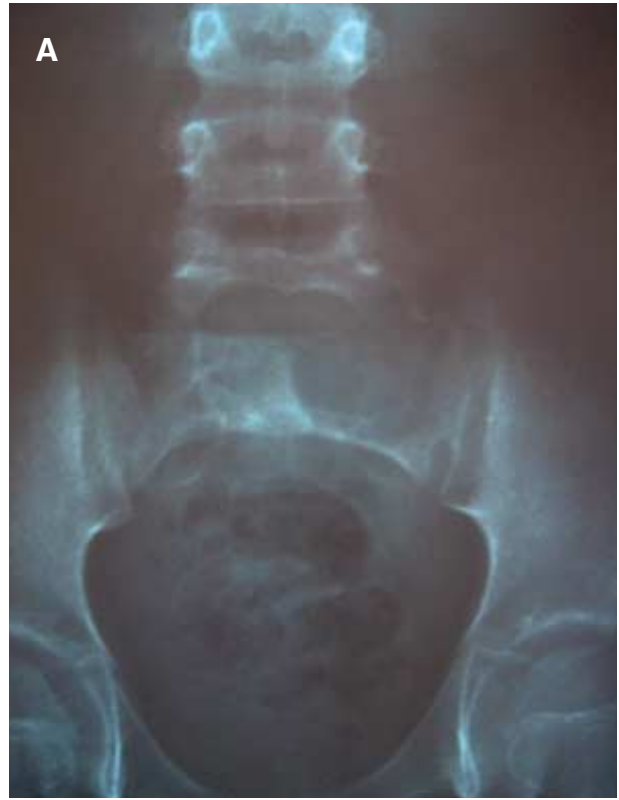

Fig 3- ABC of sacrum in 8 y/o girl.
A- AP radiograph demonstrates lytic and expansile lesion located left side of the sacrum extending sacral foramina. B- Axial MR image shows multiple fluid-filled cystic cavities separated thin septae. Typical fluid-fluid levels are also noted.

Giant Cell Tumor

Giant cell tumor is benign but locally aggressive lesion. It occurs generally in the long bones, about 3 to 7 % of cases involve the spine. It may be localized at all elements of the vertebrae^(15, 28). It is usually seen in young adults who are in their third or fourth decades. Women affected more than men. Lesions more frequently occur in the cervical, lumbar, and thoracic spine. Nonetheless, they are the one of the more common types of tumors involving the sacrum.

Pain and neurological disturbances were the most frequent symptoms in patients with giant cell tumors of the spine. Cord compression is seen in about 30% of cases⁽³¹⁾. Larsson et al⁽¹⁵⁾ noted that there is an increased risk of development of irreversible neurological lesions if the treatment is delayed more than three months after the onset of nerve root symptoms. Symptoms are often present for months to years before the initial clinical examination.

Plain radiographs often indicate a lytic, expansile mass surrounding with variable amounts of reactive bone. Unlike aneurysmal bone cyst, no septae are visible within the lesion. A CAT scan is essential in the preoperative evaluation of these tumors because of to prevent the recurrence of the tumor, complete resection is very important. At MR imaging giant cell tumors exhibit low to intermediate signal in both T1 and T2 weighted images, because of the relative collagen content of fibrous component and hemosiderin. The radiologic pictures of the tumor haven't important prognostic value but helpful for showing extent of the lesion, diagnosis should be confirmed by histological examination⁽¹⁴⁾

Successful treatment requires complete surgical resection. The proximity of neural structures in the spine may make complete resection difficult. Marginal en bloc excision is feasible only in patients in whom the tumor is well circumscribed

in the vertebral body⁽²⁸⁾. Recurrence is common, with rates reported between 16% and 40%^(15, 26, 28). Laffargue et al⁽¹⁴⁾ reported that the total spondylectomy is the recommended treatment for the giant cell tumors, when both vertebral body and neural arc involved. Preoperative internal iliac artery ligation may contribute to successful treatment in cases of sacral involvement⁽³⁰⁾. Although adjuvant therapy such as cryotherapy or phenol, have been used for prevention of local recurrence in the treatment of long bones tumors, their application in spinal tumors has been limited. Radiation therapy should be reserved for the patients with unresectable or incompletely resected tumors because of 5% to 15% of the risk of malign degeneration of the tumor^(12, 14).

REFERENCES:

1. An HS, Andreshak TG, Nguyen C, Williams A, Daniels D. Can we distinguish between benign versus malignant compression fractures of the spine by magnetic resonance imaging? *Spine* 1995; Aug 15; 20(16): 1776-82.
2. Boriani S, Capanna R, Donati D, Levine A, Picci P, Savini R. Osteoblastoma of the spine. *Clin Orthop Relat Res* 1992; (278): 37-45.
3. Boriani S, Weinstein JN, Biagini R. Primary bone tumors of the spine; terminology and surgical staging. *Spine* 1997; 22 (9): 1036-1044.
4. Bridwell KH, Ogilvie JW. Primary Tumors of the Spine (Benign and Malignant). In: Bridwell KH, Dewald RL, editors. *The Textbook of Spinal Surgery*. Vol 2. J.B Lippincott company Philadelphia 1991, pp: 1143-1146
5. Campanacci M. *Bone and Soft Tissue Tumors*. New York: Springer Verlag Wien; 1990.
6. Canadell J, Villas C, Martinez- denegri J, et al: Vertebral eosinophilic granuloma *Spine*, 1986; 11: 767.
7. Cardon T, Hachulla E, Flipo RM, Chastanet P, Rose C, Deprez X, Duquesnoy B, Delcambre B, Devulder B. Percutaneous vertebroplasty with acrylic cement in the treatment of a Langerhans cell vertebral histiocytosis. *Clin Rheumatol* 1994; 13(3): 518-21.

8. Delamarter RB, Sachs BL, Thompson GH, Bohman HH, Makley JT, Carter JR. Primary neoplasms of the thoracic and lumbar spine. An analysis of 29 consecutive cases. *Clin Orthop Relat Res* 1990; (256): 87-100.
9. Enneking WF. *Musculoskeletal tumor surgery*. Newyork: Churcill Livingstone 1983, pp: 69-122
10. Fox MW, Onofrio BM. The natural history and management of symptomatic and asymptomatic vertebral hemangiomas. *Neurosurg* 1993; 78(1): 36-45.
11. Gilday DL, Ash JM. Benign bone tumors. *Semin Nucl Med* 1976; 6(1): 33-46.
12. Heller JG, Pedlow, Jr FX. Tumors of the Spine. In: Garfin SR, Vaccaro AR, editors. *Orthopaedic Knowledge Update, Spine*. First ed. Rosemont, IL, American Academy of Orthopaedic Surgeons, 1997, pp: 235-256.
13. Kostas JP, Dailianna Z, Xenakis T, Beris AE, Kitsoulis P, Arnaoutoglou CM, Soucacos PN. Back pain caused by benign tumors and tumor-like lesions of the thoracolumbar spine. *Am J Orthop* 2001; 30(1): 50-6.
14. Laffargue P, Cotten A, Cortet B, Lecomte-Houcke M, Decoux J. Giant cell tumors of the spine. Report of a case, literature review. *Acta Orthop Belg* 1997; 63(1): 28-34.
15. Laredo JD, Quessar AE, Bossard P, Vuillemin-Bodaghi V. Vertebral tumors and pseudotumors *Rad Clin North Am* 2001; 39(1): 137-163.
16. Larsson SE, Lorentzon R, Boquist L. Giant-cell tumors of the spine and sacrum causing neurological symptoms. *Clin Orthop Relat Res* 1975; 111: 201-11.
17. Lee S, Hadlow AT. Extrasosseous extension of vertebral hemangioma, a rare cause of spinal cord compression. *Spine* 1999; 24(20): 2111-2114.
18. Levine AM, Boriani S, Donati D, Campanacci M. Benign tumors of the cervical spine. *Spine* 1992; 17(10 Suppl): 399-406.
19. Mexia MJA, Nunez EI, Garriga CS, Salinas RMS. Osteochondroma of the thoracic spine and scoliosis. *Spine* 2001; 26(9): 1082-1085.
20. Nemoto O, Moser RP Jr, Van Dam BE, Aoki J, Gilkey FW. Osteoblastoma of the spine. A review of 75 cases. *Spine* 1990; 15(12): 1272-1280.
21. Ozaki T, Halm H, Hillmann A, Blasius S, Winkelmann W. Aneurysmal bone cysts of the spine. *Arch Orthop Trauma Surg* 1999; 119(3-4): 159-162.
22. Ozaki T, Liljenqvist U, Hillmann A, Halm H, Lindner N, Gosheger G, Winkelmann W. Osteoid osteoma and osteoblastoma of the spine: experiences with 22 patients. *Clin Orthop Relat Res* 2002; 397: 394-402.
23. Pettine KA, Klassen RA. Osteoid-osteoma and osteoblastoma of the spine. *J Bone Joint Surg Am*. 1986; 68(3): 354-361.
24. Ransford AO, Pozo JL, Hutton PA, Kirwan EO. The behaviour pattern of the scoliosis associated with osteoid osteoma or osteoblastoma of the spine. *J Bone Joint Surg Br*. 1984; 66(1): 16-20.
25. Saifuddin A, White J, Sherazi Z, Shaikh MI, Natali C, Ransford AO. Osteoid osteoma and osteoblastoma of the spine. Factors associated with the presence of scoliosis. *Spin* 199; 23(1): 47-53.
26. Sanjay BK, Sim FH, Unni KK, McLeod RA, Klassen RA. Giant-cell tumours of the spine. *J Bone Joint Surg Br* 1993; 75(1): 148-154.
27. Sans N, Galy-Fourcade D, Assoun J, Jarlaud T, Chiavassa H, Bonneville P, Railhac N, Giron J, Morera-Maupome H, Railhac JJ. Osteoid osteoma: CT-guided percutaneous resection and follow-up in 38 patients. *Radiology* 1999; 212(3): 687-692.
28. Savini R, Gherlinzoni F, Morandi M, Neff JR, Picci P. Surgical treatment of giant-cell tumor of the spine. The experience at the Istituto Ortopedico Rizzoli. *J Bone Joint Surg Am* 1983 Dec; 65(9): 1283-1289.
29. Unni KK: *Dahlin's Bone Tumors. General Aspects and Data on 11,087 Cases. Benign Osteoblastoma*. Ed 5. Philadelphia, Lippincott-Raven, 1990, p: 131-142.
30. Wajanavisit W, Laohacharoensombat W, Lektarakul S, Sirikulchayanonta V. Treatment of giant-cell tumor of the spine: report of four cases. *J Med Assoc Thai* 1995; 78(10): 565-572.
31. Weinstein JN, Boriani S, Phillips FM, Wetzel T. Management of Benign Tumors of the Spine. In: Simon MA, Springfield D, editors. *Surgery for Bone and Soft Tissue Tumors*. Philadelphia, Lippincott-Raven, 1998, pp: 207-223.

Corresponding Author:

Dr. Onder Ofluoglu
 Hakkı Yeten Caddesi
 8/3 Fulya Şişli İstanbul
 Tel: 0 216 441 39 00
 Fax: 0 212 234 91 55
 oofluoglu@yahoo.com