

## COMPLICATIONS OF THE CERVICAL SPINE SURGERY

I. Teoman BENLİ, MD\*, Alper KAYA, MD\*\*

### SUMMARY

Close anatomical proximity to vital organs and technical difficulties pose an increased risk of complications in cervical spinal surgery. Certainly, spinal cord and spinal nerve injuries are the most important of these complications with potentially irreversible consequences. Carotid and vertebral arteries may be compressed or severed, particularly during anterior surgical interventions. Dysphagia, dysphonia and the obstruction of airways are among the systemic complications. Graft migration and compression on the canal, implant failure and pseudoarthrosis are not uncommon too. Appropriate preoperative preparation and meticulous surgical technique are of utmost importance in preventing complications of cervical spine surgery.

**Keywords:** Cervical spine surgery, complications, anterior intervention, posterior intervention, instrumentation.

### ÖZET

Servikal omurga cerrahisinde, yaşamsal organlara yakın komşuluk ve teknik güçlükler nedeniyle komplikasyon oluşma riski oldukça yüksektir. Spinal kord ve spinal sinirlerdeki yaralanmalar kalıcı hasara yol açabilme potansiyeli nedeniyle oldukça önemlidir. Karotid ve vertebral arterler anterior cerrahi yaklaşım sırasında bası altında kalabilir veya yırtılabilir. Disfaji, disfoni ve hava yolları obstrüksiyonları diğer sistemik komplikasyonlardır. Greft migrasyonu ve buna bağlı kanal basısı, implant yetmezliği ve psödoartroz daha nadir komplikasyonlardır. Uygun preoperatif hazırlık, cerrahi sırasında azami dikkat ve özen, servikal omurga cerrahi komplikasyonlarını önlenmesi için en önemli faktörlerdir.

**Anahtar kelimeler:** Servikal omurga cerrahi, komplikasyon, posterior ve anterior girişim, enstrümantasyon.

<sup>1</sup> Prof., M.D., Ufuk University Medical Faculty, Department of Orthopedics and Traumatology, Ankara

<sup>2</sup> Orthopedics and Traumatology Specialist, University Medical Faculty, Department of Orthopedics and Traumatology, Ankara

## INTRODUCTION :

Cervical spine surgery has a long history, and complication rates have been continuously declining for the last 3 to 4 decades. Careful attention to details is important for successful outcomes in all branches of surgery. This is more so for cervical spinal surgery as there are many potentially irreversible complications. Similarly, patient selection and preoperative planning are important determinants of success in spinal surgery in general, and cervical spinal surgery in particular. For example, cervical laminoplasty has a greater chance of success for an appropriately selected patient, whereas it may even worsen the condition in a patient with kyphosis <sup>(13)</sup>.

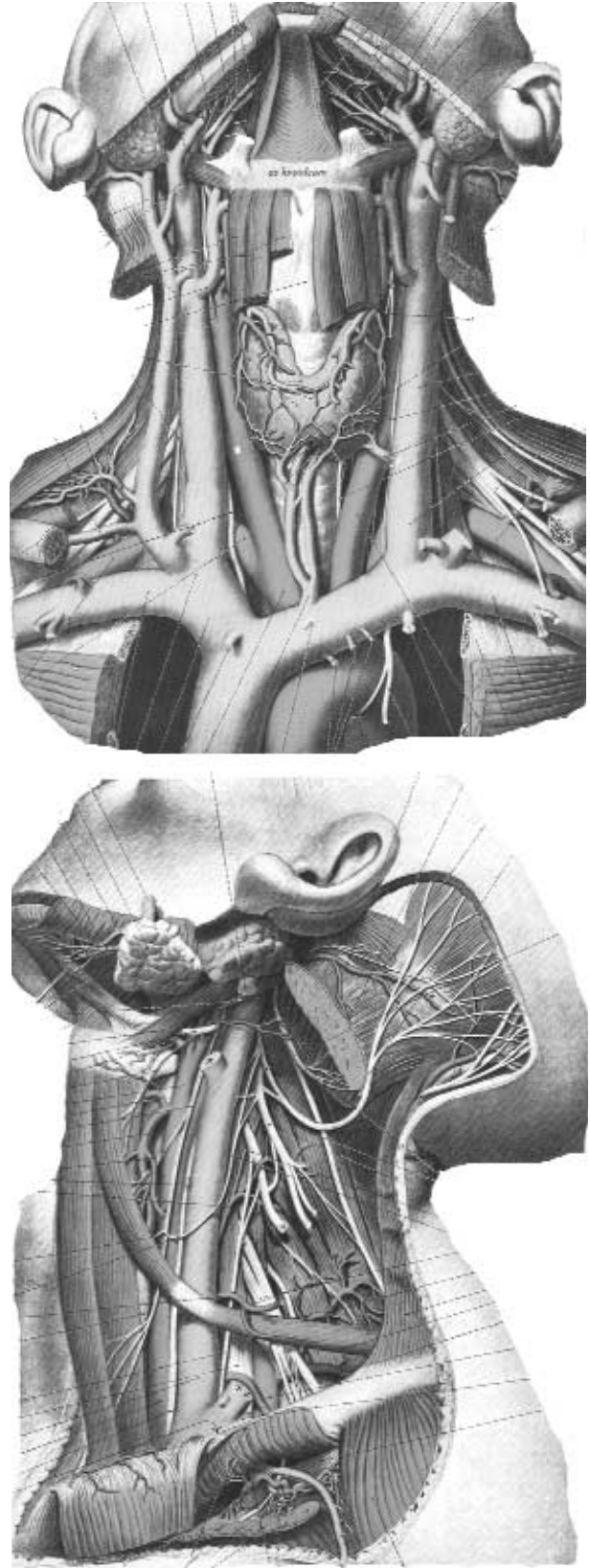
Risk of trauma and serious injury are more pronounced in cervical spinal surgery due to the fact that bony structures are weaker and smaller compared to other spinal segments and the volume of surrounding soft tissues is relatively lower. Again, close anatomical relationship with large vessels and nerves may cause various complications associated with compression or injury (Figure -1)<sup>(1,13)</sup>.

## A- INTRAOPERATIVE COMPLICATIONS

### I. PATIENT POSITION AND APPLICATION OF ANESTHESIA

Many cervical spine procedures are performed for stabilization, decompression or both in patients with neural dysfunction. This may be for an acute fracture with spinal cord injury or conditions associated with chronic compression such as spondylotic myelopathy. Patient positioning and induction of anesthesia should be closely monitored by the surgeon. In high risk patients, fiberoptic intubation is a quite safe and atraumatic method if performed with a skilled anesthesiology team <sup>(1)</sup>.

Sagi et al. reported that of the 311 patients with edema caused by intubation and compressi-



**Figure -1.** Anatomy of cervical region. a- Frontal view, b- lateral view.

on on airways, 1.9 % required re-intubation and one patient died<sup>(17)</sup>. Terao et al. found a higher incidence of airway problems in patients undergoing emergency surgery with anterior approach<sup>(23)</sup>.

Head-holders may stabilize the head with or without traction of the head and neck. Three point pin head holders exposing the whole facial area should be preferred. Pressure on eye and retinal artery thrombosis should particularly be avoided while using horseshoe like head supporters with head pronated. In patients with spinal cord compression, close attention is needed as hyperextension may cause extra narrowing in the spinal canal. Radiological confirmation of the alignment after positioning may be helpful especially in patients with instability. The degree of traction should be carefully judged in acute trauma or spinal cord compression<sup>(1)</sup>.

Extra attention should be paid by the anesthesiology team to intubation in patients with Down's syndrome or rheumatoid arthritis who have atlantoaxial instability. Excess traction and hyperextension of the head may even result in quadriplegia or death<sup>(13)</sup>. Acute instable cervical spine should not be overdistracted following the induction of anesthesia and cervical muscle relaxation. A traction weight between 5.5 and 7 kg in patients with spondylotic myelopathy and severe canal stenosis has been shown to cause minute changes in somatosensory evoked potentials that are difficult to detect and reversible<sup>(1)</sup>. Thus, a traction weight of 7 kg should never be exceeded.

Spinal cord monitoring is recommended in major decompression procedures or osteotomies in order to detect early neurological deficits. Whether evoked motor potentials are more feasible than somatosensory monitoring is yet to be seen<sup>(1)</sup>.

Shoulder traction in distal direction by band application may be needed for better x-ray visualization during positioning in cervical spine sur-

gery. Although generally unproblematic, long lasting or excessive traction may cause brachial plexus injury. Some surgeons prefer the patient in sitting position during posterior decompression procedures. However this approach carries a risk of venous air embolism and hypotension. Precordial doppler monitoring, oesophageal stethoscope and -if needed- a central catheter for air aspiration may be used to avoid this risk<sup>(1)</sup>.

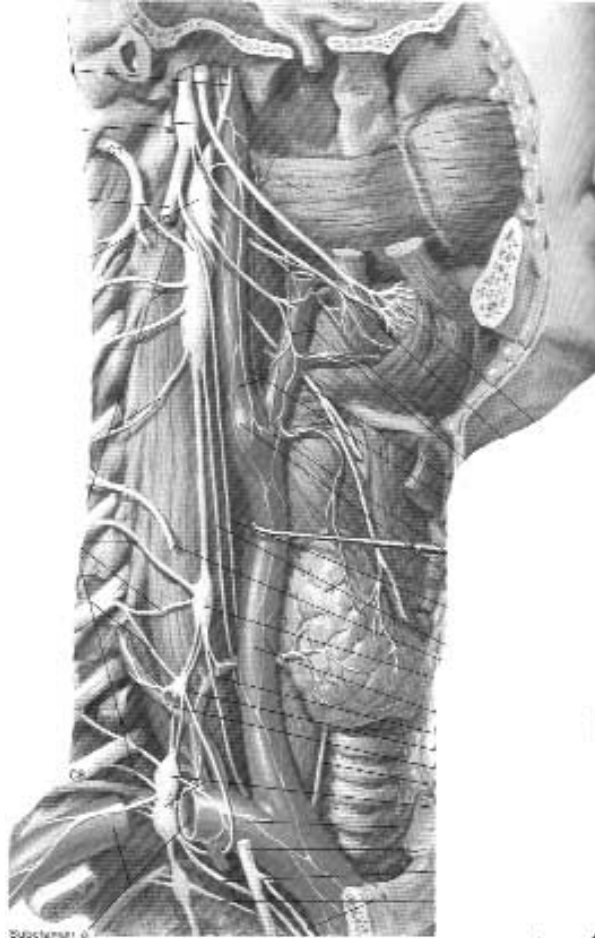
There are many potential complications associated with cervical spine surgery that may develop during or after the procedure. Although some of these complications are not directly related with the preferred surgical method (e.g. wound infection), potential surgical complications can be classified on the basis of the surgical approach (anterior or posterior)<sup>(16)</sup>.

## II. COMPLICATIONS ASSOCIATED WITH ANTERIOR INTERVENTIONS

Anterior interventions in cervical spine have been popularized by Robinson and Smith and have been clearly defined in several publications. This approach is very clearcut and practical provided that adequate attention is paid to surgical tissue planes; however, proximal location of carotid arteries, jugular vein and oesophagus leads to the possibility of direct injury (Figure-1)<sup>(1)</sup>. The most frequent complications following anterior cervical spine surgery are transient pain in the pharynx, dysphagia and hoarseness. These symptoms usually resolve spontaneously within a few weeks<sup>(5)</sup>.

In a study by Winslow and his colleagues, 60 % of the 497 patients who underwent anterior cervical spine surgery had dysphagia and dysphonia, and these were completely resolved in almost all patients within a few weeks (Figure-2)<sup>(29)</sup>. Esophageal injury may rarely cause permanent problems. On the other hand, Vanderveldt

and Young reported recurrent dysphagia requiring multiple dilatations in a 25 year old female patient who underwent an anterior intervention<sup>(25)</sup>.



**Figure -2.** Anatomy of cervical region : Esophagus

Oesophagus and particularly the body of the vertebrae should be protected against "burr"s, and if an injury occurred, indigo carmine or methylene blue should be administered into oesophagus via oral cavity by the anesthesiologist to confirm the injury. All type of tears require repair, and nasogastric tube and postoperative antibiotics should be given to these cases. Consultation from ENT specialist and general surgeon may be of value. During follow-up gastrograffin swallow test should be performed to demonstra-

te healing. Prolonged pharyngeoesophageal erosions as well as late infection or fistula formation have been described<sup>(1)</sup>.

Oesophageal perforation is a very serious complication that may lead to mediastinitis or spondylitis. It has also been reported in anterior cervical plate fixation. Primary repair necessitates an aggressive approach including drainage and antibiotherapy. Tracheal and esophageal injuries may be avoided by careful dissection and placement of retractors. Fortunately these are very rare. Tracheal perforations should be immediately repaired<sup>(16)</sup>.

Pedram et al. suggested that administration of methylprednisolone (1 mg/kg) during surgery may help to reduce pharyngolaryngeal complications<sup>(14)</sup>. Relaxation of the anterior margin of the sternocleidomastoid muscle at the beginning of dissection allows the common carotid artery to lie medial to neurovascular structures. Laryngeal recurrent nerve is under risk during the dissection of medial cervical layer. If dissection is performed immediately medial to the common carotid artery, then the intervention occurs in the tracheoesophageal space. Routine isolation and dissection of the nerve is not recommended, since this prolongs the duration of surgery and may cause inadvertent nerve injury. If possible, tracheoesophageal content can be protected by using retractors with a wide and even surface. Also, thyroid cartilage can be used to support the medial retractor. In order to reduce nerve injury, left side of the patient should be preferred, since this is anatomically safer<sup>(21)</sup>.

Neural structures vulnerable to injury during anterior interventions include recurrent laryngeal nerve, superior laryngeal nerve, sympathetic chain, and for interventions performed at a higher level, the 12th cranial nerve. Recurrent laryngeal nerve innervates all the laryngeal muscles, except for cricothyroid muscle. It runs through the

tracheo-esophageal sulcus and normally is not encountered during this approach. However, it may be subject to pressure exerted by retractors and may be associated with neuropraxis which usually resolves spontaneously<sup>(1)</sup>.

Jung et al., in their series including 112 patients, reported an early injury rate of 11.3 % for the recurrent laryngeal nerve<sup>(6)</sup>. Injury to the recurrent laryngeal nerve causes paralysis in the vocal cords and laryngeal muscles and may be associated with transient or permanent hoarseness. The risk of recurrent laryngeal nerve injury is higher in right-sided interventions (below C4-5). It can only be prevented by adequate knowledge of the surgical anatomy and correct placement of retractors<sup>(16)</sup>.

Left recurrent laryngeal nerve shows less anatomical variation, and a left-sided intervention is recommended, since injury occurs less frequently with left-sided approaches. Injury to this nerve causes hoarseness, therefore an evaluation by an ENT specialist is appropriate. Patients should be followed, since recovery takes place only after 2 to 4 months in many cases. Superior laryngeal nerve innervates mucosal membranes of the larynx, pharynx, and epiglottis and is responsible for the motor innervation of arythenoid, cricothyroid and inferior constrictor muscles. Injury to this nerve may lead to voice fatigue, which is important for singers<sup>(1)</sup>.

In superior laryngeal nerve injuries, in addition to hoarseness resulting from the paralysis of cricothyroid muscle, aspiration due to decreased laryngeal sensation may also occur. Vagal injury within the carotid sheath is quite infrequent and may cause voice changes<sup>(16)</sup>. Fujubayashi et al. have reported a case with bilateral phrenic nerve palsy<sup>(3)</sup>.

Sympathetic chain is lateral to the longus colli muscle and is not usually encountered in Robinson's approach. Laterally shifted dissections

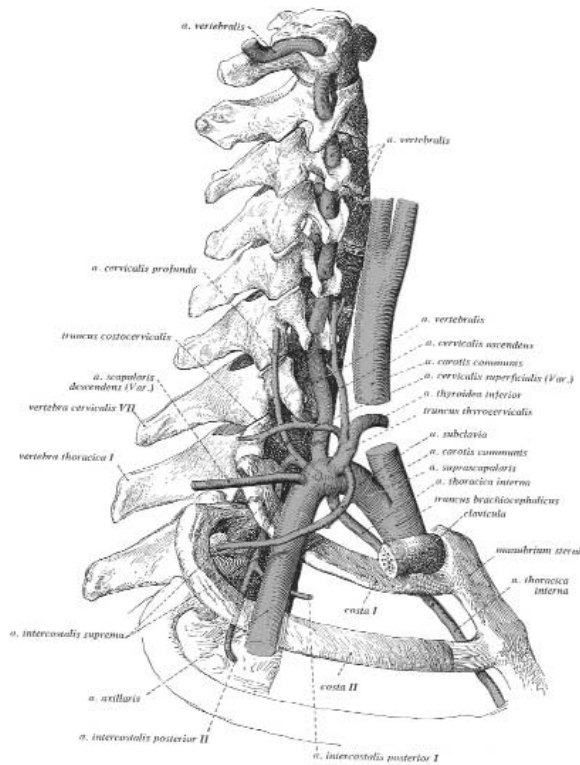
may increase the risk of injury during anterior tumor resections. Injury to the sympathetic chain may result in the classical Horner's triad which includes ptosis, miosis and anhidrosis. In higher retropharyngeal interventions, this area may be transversed by the hypoglossal nerve, which may resemble a large vessel. Thus, in this anatomical location extreme care is needed during the ligation of vessels or dissection of structures<sup>(1)</sup>.

Airway obstruction is always possible during wide corpectomies performed for myelopathy particularly at C4 or higher levels. Acute airway obstruction occurring immediately after surgery is not due to retropharyngeal hematomas, but due to lymphatic obstructions. Retropharyngeal hematoma formation is also possible, and secondary drainage is required if it is too large. A flexible closed drainage system should treat the problem<sup>(21)</sup>.

Following the operation, respiratory difficulty due to hematoma formation may be reduced by using drainage tubes during wound closure. Carotid artery injury is rare<sup>(16)</sup>. Yeh et al. reported one case of common carotid artery retraction, which led to stroke and death<sup>(31)</sup>. Polland and Little monitored the blood flow in carotid arteries by ultrasonography in 15 patients undergoing anterior cervical surgery and found a significant decrease in blood flow during surgery<sup>(15)</sup>. Careful dissection and placement of retractors may help to reduce this complication. Should carotid artery injury occur bleeding must be controlled, and urgent repair by vascular surgeon may be needed in some cases<sup>(16)</sup>.

The primary vascular structure at risk during anterior decompression and stabilization procedures is the vertebral artery (Figure-3)<sup>(1)</sup>. Although vertebral artery lacerations are uncommon, they are potentially dangerous. Most of the lacerations occur when the surgeon fails to keep the

orientation during corpectomy<sup>(21)</sup>. Uncovertebral joints are a good landmark to help keep surgeon's orientation at midline. Leaving a margin of a few millimeters from the outer layer of the bone may help to prevent vertebral artery injury in addition to providing good neural decompression. Also, the surgeon should avoid elevating longus colli muscle more than 3 mm in lateral direction between masses. In patients with tumors involving vertebral artery, this artery initially should be isolated and controlled at C6-7 disk space<sup>(1)</sup>. Anterior foraminotomy should be performed carefully and the opening of the neuroforamen should be evaluated with blunt probes<sup>(16)</sup>. One case of fatal injury to vertebral artery in a 60 year old patient with rheumatoid arthritis has been reported by Tomalian et al.<sup>(24)</sup>.



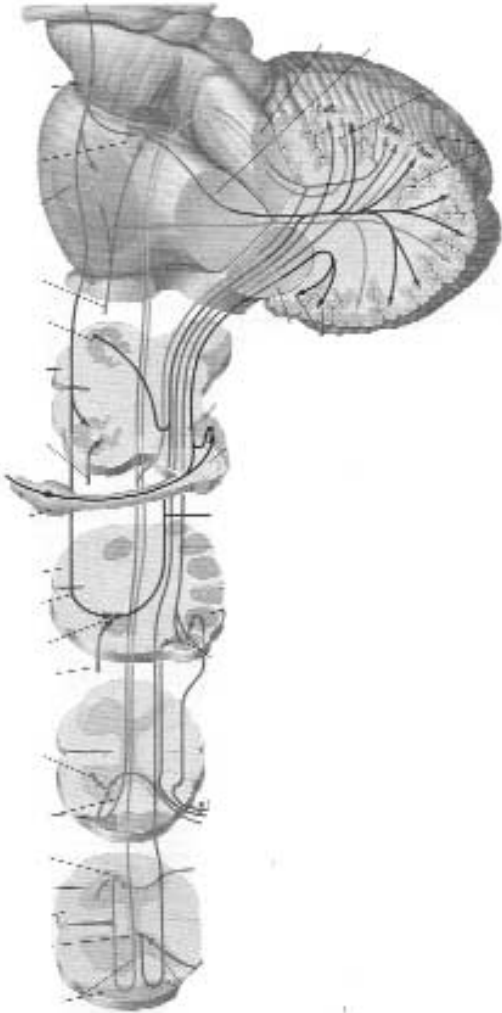
**Figure -3.** Anatomy of vertebral artery.

Other possible causes of injury to vertebral artery include excess dissection in lateral direction while trying to provide lateral decompression; absence of the vertebral artery in its normal anatomical location due to widening; or involvement of the lateral side of the vertebral body by tumor or infection. Preoperative axial imaging may be needed to determine the localization of vertebral artery in such high-risk procedures. In suspected cases, MR angiography or other vascular imaging studies may be required<sup>(21)</sup>.

Ideal treatment for injury to vertebral artery is primary repair. Proximal and distal control are needed not only for bleeding control but also for obtaining proper visualization of the field. Simple injuries may be controlled by pressure and gelfoam. Major injuries necessitate vertebral artery dissection, bleeding control, and repair (if possible) or ligation. Angiographic occlusion may also be needed. Rarely, internal or external jugular vein injury may occur during dissection and retraction. If adequate collateral circulation is present, sacrifice of one vertebral artery does not cause any functional deficit. Yet, there is a risk of brainstem or cerebellar infarction which may lead to Wallenberg syndrome. In these patients, symptoms such as difficult swallowing, movement disorders of the tongue, or symptoms indicative of other cranial nerve or cerebellar function loss may develop<sup>(1)</sup>.

Although rare, nerve root injury following decompression has been described. This usually results from direct or indirect manipulation and traction that occur during the removal of the disk above or the osteophyte. If uncovertebral spurs are wide, we recommend thinning with high speed burr and then cleansing with small, angled curettes. Improvement of the root lesion is associated with the extent of injury; it usually occurs in the form of neuropraxia and recovers quickly<sup>(1)</sup>.

Temporary or permanent cervical root injury may also occur during anterior disk surgery (Figure-4). Particular attention should be paid to avoid root injury during the excision of foraminal osteophytes and disk content<sup>(7,16,22)</sup>.

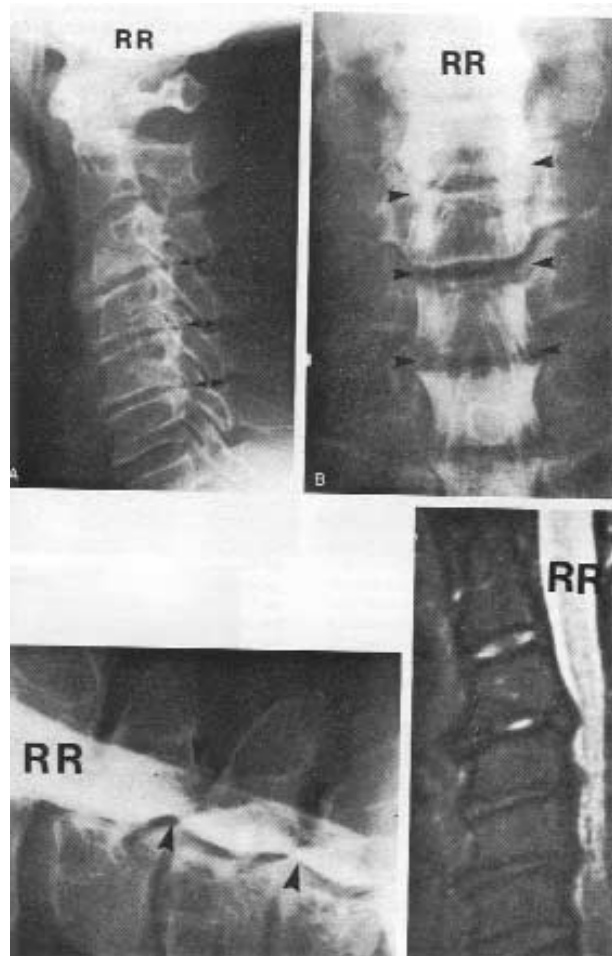


**Figure -4.** Neural pathways

In the study by Martin et al., 4.8 % of 167 patients had neurological deficit<sup>(10)</sup>. Wang and Green found one case of C5 root lesion and two cases of persistent neck pain among 15 patients who underwent anterior cervical intervention<sup>(27)</sup>. In a series with 258 patients, Wang et al. found an early postoperative myelopathy incidence of 74.4 %<sup>(28)</sup>.

Vascular problems were seen in 2 of 41 patients undergoing discectomy with Holmium laser, with nerve injury in one patient<sup>(5)</sup>.

Though rare, the most feared complication is spinal cord injury. Flynn found an incidence of 0.1 % for all myelopathic complications in a large series consisting of 82,000 patients. Most of the neurological deficits occur during early period, but some may occur later. Possible causes of myelopathy include excessive manipulation during surgery, formation of epidural hematoma, or migration, collapse or pseudoarthrosis of bone grafts (Figure-5)<sup>(16)</sup>.



**Figure -5.** Myelomalasia of cervical spinal cord.

Steroids are widely used in high risk patients preoperatively to protect against spinal cord in-

jury, although there have been no studies examining their use. Also, studies show that the etiology of the intraoperative or postoperative spinal cord injury cannot be always demonstrated<sup>(1)</sup>.

Taunt et al. found that the incidence of neural deficits overlooked by SEP is not small<sup>(22)</sup>. Jones et al. observed false negative results in 2 patients who developed quadriplegia despite SEP, and they suggested that ideal neural monitoring should combine SEP and MEP<sup>(7)</sup>. If spinal cord monitoring suggests the presence of problems during the operation, then blood pressure, the position of the neck and head, and the body temperature should be checked<sup>(1)</sup>.

Also the devices, their connections and cables should be controlled. Any kind of traction should be reduced. Our experience shows that a minimal traction of 7 kilograms is able to change the evoked potentials in patients with severe compression and that this condition persists even after decompression. If spinal cord monitoring shows abnormality after the graft is placed, then graft should immediately be removed. The graft may need to be replaced or its size should be reduced<sup>(1)</sup>.

If neural injury is suspected, an awakening test before the wound closure should be performed. If pathology is detected, then the patient should be re-opened. If no abnormality is seen then neuro-radiological imaging with CT, myelography and MRI should immediately be performed<sup>(1)</sup>.

Cerebrospinal fluid (CSF) leak due to dural injury is a rare but potential complication<sup>(16)</sup>. Injury to dura by curette or burr; absence of dura in some patients; or severe ossification of posterior longitudinal ligament leading to canal pressure by osteophytes and removal of these spurs are among possible causes of CSF leak.

If CSF leak is prolonged, a dural defect unnoticed due to intact arachnoid should be suspec-

ted. In many cases close follow-up of the patient is adequate, but if it persists, other treatment steps should be tried. Direct repair can be performed with 6-0 or 7-0 nylon or silk suture material, but the repair is technically very difficult when the tear is in the lateral "gutter". In wide defects, facial patch may be needed. To stop leakage, gel foam with or without suture may be used. Recently, fibrin adhesives are also recommended. A good pre-operative planning is needed in patients with severe ossification in the posterior longitudinal ligament<sup>(1)</sup>.

Temporal subarachnoid drainage with bed rest and prophylactic antibiotics may also be used if leakage does not stop. This should be continued for at least 3 to 4 days. After the drain was clamped, the wound should be checked for one to two days, and the drain can be removed if there is no drainage.

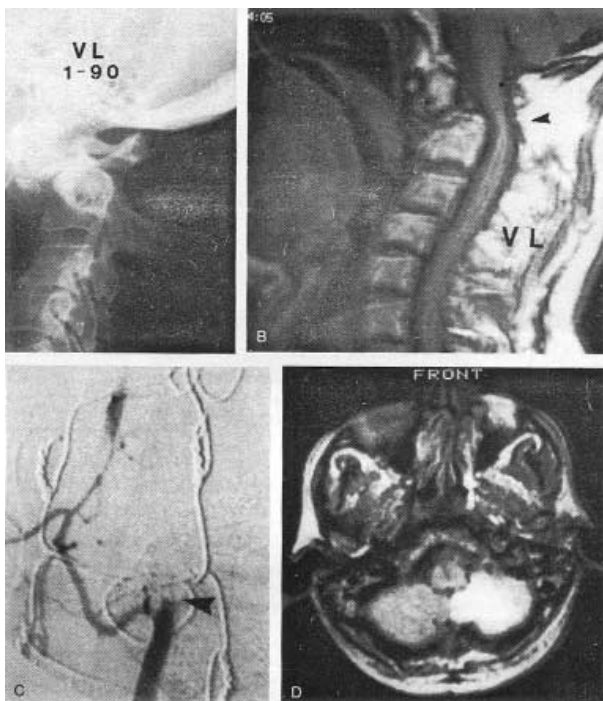
Deep infections causing osteomyelitis, disk space, or graft infection have been reported very rarely. Intravenous antibiotics combined with surgical debridement if needed can be used depending on the severity of infection<sup>(16)</sup>.

One of the unpleasant adverse consequences of anterior decompression procedures is inadequate decompression. A good pre-operative planning and preparation should be done and adequate illumination and sight should be provided. Using landmarks such as uncovertebral joints, sufficient bone and disc can be removed without injuring vertebral arteries. Sufficient decompression may be confirmed by postoperative CT. If, for example, the patient's problem is worsened or unaltered, residual compressive elements can be evaluated by repeat MRI or CT imaging<sup>(1)</sup>. Woodard et al. used intraoperative MRI in 12 patients undergoing anterior cervical surgery, and suggested that adequate decompression can be provided with this approach<sup>(30)</sup>.



### III. COMPLICATIONS ASSOCIATED WITH POSTERIOR INTERVENTIONS

In routine posterior interventions, neural or vascular injury is not possible, since this approach requires scraping of paraspinal muscles from the spinous processes and lamina. However, since vertebral arteries lie dorsal to C1, there is a risk of injury starting from 2 cm from the midline. Injuries should be repaired or ligation should be performed to control bleeding (Figure-6)<sup>(1)</sup>.



**Figure -6.** Vertebral artery injury.

If upper cervical vertebrae are approached by scraping of the spinous process of C2, late kyphosis may develop if ligamentum nuchae is not retied<sup>(1)</sup>.

In posterior decompression procedures, direct trauma to spinal canal or nerve root must be avoided. A good knowledge of anatomy, instrumentation, illumination, and homeostasis are important factors to consider. A specific injury during laminoplasty procedures is the 5th cervical root palsy. Spinal canal widens in posterior direction,

and the 5th nerve is stretched since it has the shortest distance to the foramen, resulting in neuropraxis. Reports suggest that the condition resolves in many cases though follow up is required<sup>(1)</sup>.

Heler et al. proposed that laminoplasty is safer than laminectomy<sup>(6)</sup>. Instability and kyphotic deformity may develop in case of extensive facetectomy (50 %), resection of facet capsule, or laminectomy together with bilateral facetectomy. In such cases, fusion may be needed to provide stability. Vertebral artery may be injured during aggressive dissection or foraminotomy. Although the exact frequency of paraspinal atrophy is unknown, it is a quite common condition. As in anterior interventions, potential complications include infection, CSF leakage, and epidural hematoma<sup>(16)</sup>.

CSF leak is infrequent during posterior interventions, and direct repair can be performed. Inadequate decompression problems may be related with patient selection (e.g. decompressive laminectomy in a patient with kyphosis) or the technique applied. Removal of adequate quantity of bone for decompression and excess removal of facet joints may cause postlaminectomy kyphosis. In children such complications are more frequent. Zdeblick et al. found a decreased stability of the spine if 50 % or more of the facet joints are removed. Anterior procedures must be used to halt the progression of the deformity in patients with preoperative kyphosis<sup>(1)</sup>.

Although nerve root injuries are rare, extra attention should be given during foraminotomy and the surgeon must avoid excessive retraction of the nerve root while cleansing the disc material. Spinal cord injuries are very uncommon and probably result from inappropriate patient positioning and excessive manipulation.

#### IV. EARLY POSTOPERATIVE COMPLICATIONS

##### - Airway Obstruction

Upper airway obstruction due to postoperative edema formation has been reported following anterior or posterior cervical spine surgery. Patients undergoing simple anterior discectomy and fusion are usually extubated immediately; however intubation may be prolonged until the resolution of edema in multi-level anterior corpectomies. If obstruction recurs following extubation, the patient must be re-intubated or a cricothyroidotomy must be performed. Some contributory complications include airway edema, laryngeal spasm, hematoma formation, CSF extravasation, and displacement of the bone graft <sup>(1)</sup>.

In the study by Sagi et al. 6.1% of the patients had early postoperative airway problems, with edema resolution within 36 hours and symptomatic improvement <sup>(17)</sup>. Terao et al. reported a higher frequency of airway problems in patients undergoing combined anterior and posterior interventions <sup>(23)</sup>.

##### - Temporary Dysphagia

Temporary dysphagia following anterior cervical spine surgery may result from the retraction of esophagus and postoperative edema. It usually resolves within 1 to 2 days, but may be prolonged in some cases. Dysphagia may also be caused by hematoma. Dysphagia due to hematoma usually improves upon the resorption of hematoma, though drainage may sometimes be needed. Esophageal diverticula formation due to adhesion of anterior graft may cause prolonged dysphagia <sup>(1)</sup>.

##### - Neurological Deficit

Prolonged neurological deficits following anterior or posterior procedures should raise the suspicion of hematoma formation. Early myelography,

MRI imaging or re-operation should be performed. A hematoma that can be easily observed by the naked eye is not the rule, and a deep-seated small hematoma may also cause dural compression. This complication may be avoided by discontinuation of aspirin or other non-steroidal anti-inflammatory drugs before the procedure and by the use of drainage.

Cybulski and D'Angelo, in their paper examining the prolonged neurological deficits during early postoperative period, reported that 4 patients had hypotension in combination with these symptoms, and improvement of hypotension resulted in a quick recovery of the neurological deficit in these cases none of whom had dural compression <sup>(1,13)</sup>.

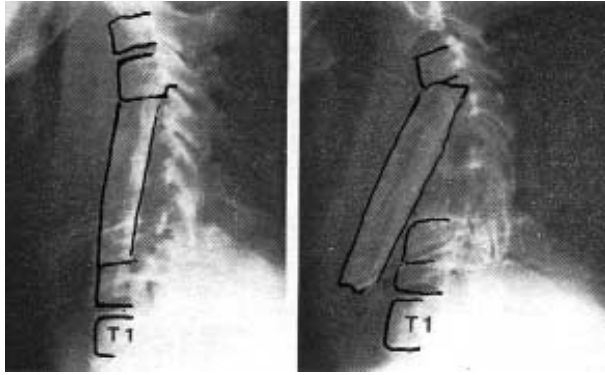
##### - Postoperative Infection

Postoperative infection following cervical spine surgery is unusual, probably due to good blood flow in the area. Perioperative prophylactic antibiotics are used without any data suggesting their efficacy. Dislodged grafts may cause infections or life threatening conditions such as mediastinitis by eroding esophagus. In such cases, open drainage and antibiotics are indicated. In serious chronic infections, another option is drainage and removal of the graft, antibiotherapy during the traction, and use of structural grafts for anterior column support <sup>(1)</sup>.

##### - Displacement of the Graft

Early graft-related complications include dislodgement, graft fracture, and problems related with the donor area. In discectomy and fusion procedures graft displacement is rare (Figure-7) <sup>(1,13)</sup>.

In multilevel cervical corpectomy destabilization, and displacement of iliac or fibular bone grafts pose an important problem. In such cases, keeping the graft in "halo" for 3 months for repositioning and protection may be required. Dislo-



**Figure -7.** Dislodgement of anterior strut graft.

cations may occur despite halo immobilization. Although it is possible to correct these conditions accompanied with postlaminectomy deformities by isolated anterior decompression and fusion, incidence of graft dislocation and correction loss is quite high and patients should be given information about possible consequences. An alternative approach is posterior facet fusion and posterior lateral mass plate following an anterior procedure<sup>(21)</sup>.

Özgen et al. reported a complication rate of 20.8 % among 72 patients undergoing cervical corpectomy, of these patients 5 had dislocated graft<sup>(12)</sup>.

Wang et al. found graft migration in 16 of 249 patients undergoing anterior corpectomy all of which occurred at the very mobile C5-6 junction<sup>(26)</sup>.

Graft intrusion may result from bad location of the graft, postoperative trauma, or inadequate postoperative immobilization. Although rare, graft intrusion necessitates urgent surgery due to the risk of spinal cord compression<sup>(16)</sup>.

Fractures are more common if the graft is removed by an osteotom instead of a saw. If the fracture involves a Robinson type graft, then this should be followed, since it readily recovers unless radiculopathy and kyphosis develop. Dowel type grafts are less resistant to compression; there-

fore we do not recommend their use due to the risk of kyphosis and neurological deficit resulting from collapse. Since long structural deficits can easily be displaced, vertebral body end-plates should be prepared with a careful technique, and if needed their tips can be smoothed by burrs.

Acute graft collapse is possible particularly in elderly osteoporotic patients with a graft height greater than 6 to 7 mm's. Particularly in osteoporotic patients, fractures of the vertebral body on which the graft was placed can be seen. In these cases, if the fracture is minimally displaced and the graft has a good position, then follow up with halo vest is possible. In cases with significant displacement, kyphosis, and loss of contact between graft and the vertebral body, then revision surgery is required. A longer graft necessitates extension to one extra level. If there is suspicion regarding the bone quality or stability, posterior immobilization with plates and wires in addition to halo vest is recommended<sup>(1)</sup>.

Shapiro et al. reported that migration can be prevented and the fusion rates are increased when graft is immobilized with AO-CSLP in patients for whom fibular allografts are used<sup>(20)</sup>. Samandouras et al. suggested that cages fixed to the anterior plate obviate the risk of graft migration as well as preventing associated neural deficit risk<sup>(18)</sup>.

Posterior bone graft complications are uncommon because corticocancellous blocks and cancellous strips do not change their location readily and they do not carry the weight carried by anterior grafts. In patients undergoing decompression laminectomy, bone grafts should be left in lateral masses to avoid neurological deficits and migration. Preferably, facet type fusion should be done in these patients<sup>(1)</sup>.

Some authors have reported on the rare occurrence of donor area morbidities following removal of graft in the iliac crest including persis-

tent pain, lateral femoral cutaneous nerve injury, cosmetic deformity, hematoma formation, infections, and fractures. Again a good knowledge of surgical anatomy and a careful surgical technique should help to prevent these complications. Donor area complications have also been reported following fibular graft use<sup>(16)</sup>.

The incidence of donor area complications is varied. Unexplained chronic pain may cause a problem. The pain may be caused by severed cutaneous nerves, sacroiliac joint injury, or soft tissue dissection. Ilium, as a source of graft both anteriorly and posteriorly, may be fractured. Use of an electric saw may prevent fractures. Wound hematoma is frequently seen and rarely causes a problem, but very large hematomas require drainage. Obese patients are particularly susceptible to wound infections. Lateral femoral cutaneous branch should be protected while obtaining anterior grafts; this nerve is vulnerable to retraction and neuropraxis may develop. Recovery may take months<sup>(1)</sup>.

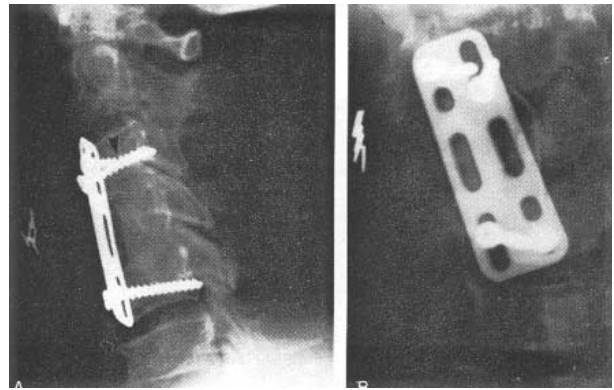
Chronic pain and soft tissue problems are the complications associated with autogenous fibular grafts. However they rarely cause problems in the long term. Tibia stress fractures may also occur after partial fibulectomy<sup>(1)</sup>.

## VI. THE COMPLICATIONS ASSOCIATED WITH STABILIZATION AND INSTRUMENTATION

Internal fixation of the cervical spine is increasingly used in traumatic, degenerative and neoplastic diseases. The main complications associated with instrumentation are the malpositioning, break, or migration of the instrumentation.

Implant failure is usually caused by patient related factors such as osteoporosis. There is a risk of spinal canal injury during the application of bicortical implants. Use of locked plates may help

to prevent complications such as dislodgement of screws and broken instrumentation (Figure-8). Esophagus erosions due to broken or displaced instrumentations have been reported<sup>(1)</sup>.



**Figure -8.** Screw brakeage.

Posterior cervical stabilization is accomplished by methods such as wiring and bone grafts. Possible complications of wire stabilization include fracture, malposition, and excision of the osteoporotic bone. Extreme care should be given when passing below the posterior ring of atlas, C1 or C2<sup>(1)</sup>.

Posterior cervical lateral mass plating is also a more commonly used method. Vertebral arteries and cervical roots are among the structures under risk. Radiographic control in two planes (AP and lateral) is needed while placing the screws. Tomography may be used in suspected cases<sup>(1)</sup>.

Mummaneni et al. found one case of screw malpositioning among 32 patients undergoing poliaxial screws, and achieved fusion in all patients<sup>(11)</sup>. Gerçek et al. reported one case of anterior cervical cage break<sup>(4)</sup>.

There are some immobilizers that are used following cervical spine surgery. Soft collars and Philadelphia may be inadequate after extensive procedures. More rigid, head-cervical-thoracic orthoses may cause temporomandibular joint complaints and skin erosions. Halo vest or plas-

ters may provide good stability, but they may sometimes fail to immobilize the spine rigidly (particularly in the lower cervical area)<sup>(1)</sup>.

## VI. LATE COMPLICATIONS

### - Pseudoarthrosis

The most frequent late complication of cervical spinal surgery is pseudoarthrosis. Lower cervical posterior fusion failure is rare. In upper cervical segments, although there is no fusion to provide arthrodesis, a stable fibrous fusion occurs. It is quite common in certain patient groups such as children with Down syndrome. If pain and instability are persistent, anterior posterior grafting and rigid immobilization are required<sup>(1,13)</sup>.

Pseudoarthrosis is an important problem in anterior cervical fusion procedures. Many authors do not believe that pseudoarthrosis is a major determinant of the final outcome. In three quarters of the patient population pseudoarthrosis is symptomatic and affects the pain outcome. In Robinson type grafting, the frequency of pseudoarthrosis increases as the level of operation increases, and there is a small correlation with cigarette smoking. Regarding multi-level grafts, autografts have been associated with more favorable outcomes than allografts. In short-segment grafts, the difference is insignificant and the incidence of pseudoarthrosis is lower since burring of the end-plates of vertebrae causes bleeding in subchondral bone. One year of radiological follow-up is required before a conclusive decision of non-union is made. In suspected cases, flexion-extension x-rays and tomography may be needed<sup>(1)</sup>.

The frequency of complications is much higher during solid arthrodesis procedures compared to abovementioned complications. The reported incidence of pseudoarthrosis is 2 % in non-smokers compared to 5-6 % in smokers.

Preoperative discontinuation of smoking and alcohol may help to reduce non-union rates postoperatively.

If the bone density of the patient is 2 standard deviations higher compared to age-matched individuals, the risk of graft collapse and non-union are higher. Typically these patients initially present with very good clinical results, but later graft collapse and persistent neck and shoulder pain develop. Non-union and shoulder-neck pain develop in one third to one fourth of patients with graft collapse. Pain projecting to arm is the most frequent complaint. Posterior intervention to provide arthrodesis is recommended for those patients with persistent pain for 9 to 12 months despite follow up and conservative treatment. This may be combined with foraminotomy for cases with radicular pain<sup>(21)</sup>.

Internal fixation obviates the need for external immobilization. Rarely, spontaneous anterior consolidation of the non-union tissue occurs. This approach is usually successful in preventing neck and shoulder pain. Alternatively, the anterior approach may be repeated together with the complete debridement of non-union tissue and structural grafting. This procedure may be preferred if there is residual spinal cord compression due to hypertrophied pseudoarthrosis material<sup>(21)</sup>.

Graft collapse may also cause deformities associated with recurrence of neurological dysfunction. The frequency of pseudoarthrosis is higher in fusions involving at least two levels. A review of the studies suggests that pseudoarthrosis is an obstacle to successful surgery. In such pseudoarthrosis cases with recurrent symptoms, posterior fusion -and if required- additional foraminotomy may be needed<sup>(16)</sup>.

If bone grafting fails to provide arthrodesis in 1 year, no solid union is expected. Typically these patients have neck pain and expansion of chondro-osseous spurs due to permanent movement

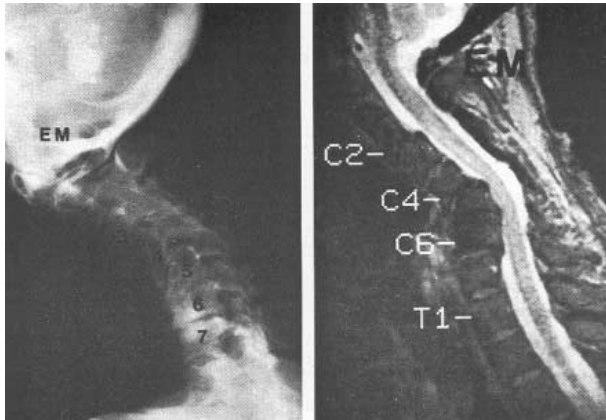
can cause radiculopathy or myelopathy. Anterior-posterior fusion may be required in patients with persistent symptoms<sup>(1)</sup>.

In patients undergoing multi-level corpectomy, Epstein reported that the incidence of pseudoarthrosis fell from 13 % to 3.6 % if dynamic plate is used instead of classical posterior stabilization<sup>(2)</sup>. In long fusions with fibular grafting, the incidence of pseudoarthrosis is quite high. The technique is again very important, and the graft must be attached to the vertebral body precisely in the midplane<sup>(1)</sup>.

In patients with spondylosis, cervical disc prosthesis is an alternative to fusion. Sekhon et al. proposed that Byran arthroplasty results in a mobile and painless segment, thus eliminating the risk of pseudoarthrosis<sup>(19)</sup>.

## VII. KYPHOSIS

Postoperative kyphosis may be caused by discectomies, anterior graft collapse, or multi-level laminectomies without fusion procedures. In patients with anterior discectomy without fusion, disc distance collapses and causes kyphosis at the segment in question (Figure-9). Kyphosis accompanied by osteophytes, absence of fusion and permanent mobility may cause cord or nerve root compression. Anterior graft collapse is more common in osteopenic patients and in patients with Dowel type graft<sup>(1)</sup>.



**Figure -9.** Kyphosis of cervical spine.

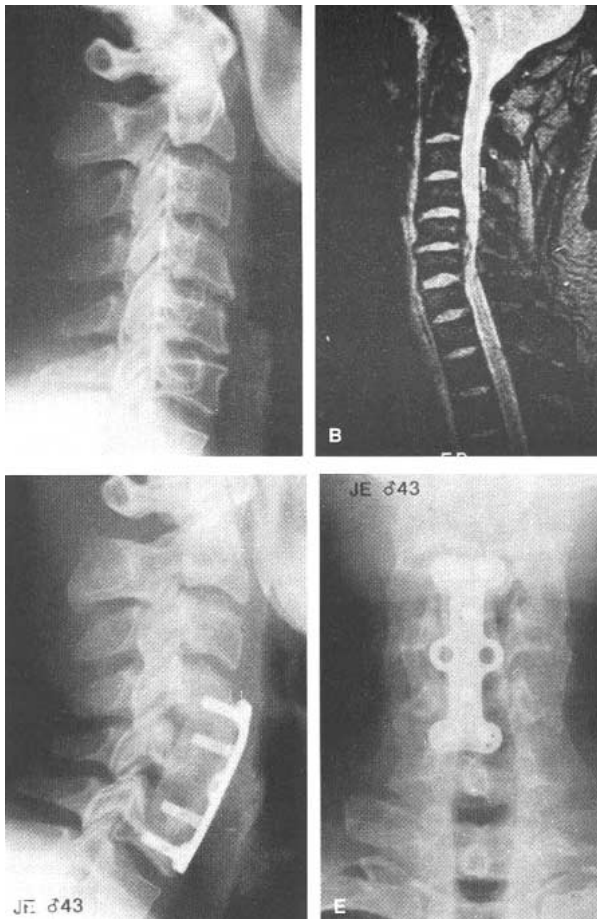
Postlaminectomy kyphosis is more common in children due to the growth potential of the spine and increased anterior load. Laminectomy alone causes varying degrees of destabilization and the incidence of kyphosis is particularly increased in patients such as those with tumors who receive postoperative radiotherapy and have their facet joint removed. In adults, postlaminectomy kyphosis is quite rare. In patients with preoperative kyphosis, removal of facet joint results in kyphosis. Laminectomy performed without stabilization for acute cervical fractures may also cause progressive instability and severe deformity<sup>(1)</sup>.

Katsuura et al. followed 42 patients for 9.8 years, and observed progressive kyphosis in 77 % of fused segments<sup>(9)</sup>.

Although the exact frequency of postlaminectomy kyphosis is unknown, it is not uncommon and may cause mechanical neck pain, radiculopathy and myelopathy. Other conditions associated with spinal canal compression such as disc, osteophyte or posterior longitudinal ligament ossification are aggravated by the co-presence of kyphosis. Surgical treatment involves anterior decompression with structural graft, multi-level corpectomy and fibula graft. Preoperative traction may reduce kyphosis and soft tissue tension. In many patients, halo vest is applied due to the risk of graft displacement. In severe deformity and instability, facet joint fusion, instrumentation with wire or plate, and anterior or posterior refusion may be used (Figure-10)<sup>(1)</sup>.

### - Problems at other levels

In the long term, normal degenerative changes are seen in other levels. Although disc herniation, spondylotic changes, and degenerative spondylolisthesis may seem unrelated to the surgery, fusions cause some derangement in the biomechanical properties of the cervical spine<sup>(1)</sup>. Katsuura et al. reported a degeneration rate of 43 % for the adjacent disc<sup>(9)</sup>.

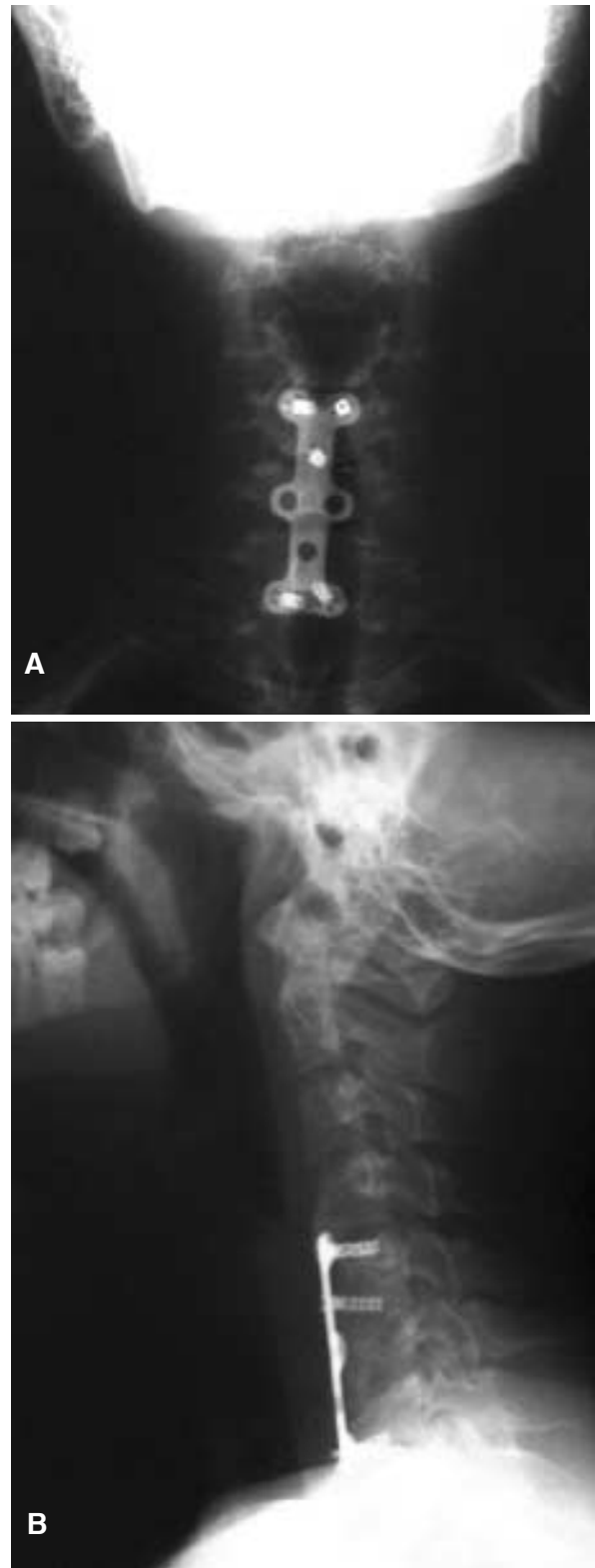


**Figure -10.** Surgical treatment of cervical kyphosis.

Bohlman reported problems in the adjacent disc in 9 % of the patients. Several other studies reported similar findings. Longer term studies are warranted to understand the late effects of posterior decompression and anterior fusion procedures at other levels<sup>(1)</sup>.

**- Our Experience**

At present, we have a total of 40 patients with cervical pathologies who were surgically treated with anterior decompression, anterior autologous grafting, and AO CSLP locked titanium plates at the 1st Department of Orthopaedics and Traumatology, Dışkapı Yıldırım Beyazıt Hospital (Figur-11.a,b). These patients have been followed in collaboration with 2nd Department of



**Figure -11.** Anterior instrumentation of the cervical spine. a- AP rontgenography of the patient treated with AO- cervical spine locking plate, b- Lateral graphy of the patient.

Neurosurgery of the same institution. Of these cases 20 had cervical fractures, 11 had cervical disc pathology, 5 had cervical spondylosis, 3 had cervical tumors, and 1 had cervical Pott's disease. No patient developed pseudoarthrosis or graft migration. Five had temporal dysphagia and disphonia. There were no cases of injury to arteries or nerves. Only one patient with lung cancer metastasis at level C5/6 had worsening of motor deficit, and this patient was already quadriplegic. Apart from that, no early or late local or systemic complications were encountered.

In conclusion, cervical spine surgery requires highly skilled surgical staff, good preoperative planning, and very careful and meticulous surgical technique. These are necessary for reducing the high risk of complications.

## REFERENCES

- 1- Emery SE, Bolesta MJ. Complications of cervical spine surgery. In : The Textbook of Spinal Surgery, 2nd Ed., Bridwell KH, DeWald RL (Eds.), Lippincott – Raven Publishers, Philadelphia, 1997, pp: 1427-1438.
- 2- Epstein NE. Fixed vs dynamic plate complications following multilevel cervical corpectomy and fusion with posterior stabilization. Spinal Cord 2003; 41 (7): 379-384.
- 3- Fujibayashi S, Shikata J, Yoshitomi H, Tanaka C, Nakamura K, Nakamura T. Bilateral phrenic nerve palsy as a complication of anterior decompression and fusion for cervical ossification of the longitudinal ligament. Spine 2001; 26 (12): E281-286.
- 4- Gercek E, Arlet V, Delilse J, Marchesi D. Subsidence of stand-alone cervical cages in anterior ,inter warning. Eur Spine J 2003; 12(5): 513-516.
- 5- Haufe SM, Mork AR. Complications associated with cervical endoscopic discectomy with the holmium laser. J Clin Laser Med Surg 2004; 22 (1): 57-58.
- 6- Heller JG, Edwards CC, Murakami H, Rodts GE. Laminoplasty versus laminectomy and fusion for multilevel myelopathy: an independent matched cohort analysis. Spine 2001; 26(12): 1330-6.
- 7- Jones SJ, Buonamassa S, Crockard HA. Two cases of quadriplegia following anterior cervical dis with normal perioperative somatosensory evoked potentials. J Neurol Neurosurg Psychiatry 2003; 74 (2): 273-276.
- 8- Jung A, SchRamm J, Lehnerdt K, Herberhold C. Recurrent laryngeal nerve palsy during anterior cervical spine surgery: a prospective study. J Neurosurg Spine 2005; 2 (2): 123-127.
- 9- Katsuura A, Hukuda S, Saruhashi Y, Mori K. Kyphotic malalignment after anterior cervical fusion is on factors promoting the degenerative process in adjacent into levels. Eur Spine J 2001; 10 (4): 320-324.
- 10- Martin R, Carda JR, Pinto JI, Sanz F, Montagne F, Paternina B, Trigueros F, Izquierdo JM, Vazquez-Barguero A. Anterior cervical discectomy and interbody arthrodesis Cloward technique: retrospective study of complications radiological results of 167 cases. Neurocirugia (Astur) 2002; 13 (4): 265-284.
- 11- Mummaneni PV, Haid RW, Traynelis VC, Sasso RC, Subach BR, Fiore AJ, Rodts GE. Posterior cervical fixation using a new polyaxial screw and system: technique and surgical results. Neurosurg Focus 2002; 12(1): E8.
- 12- Ozgen S, Naderi S, Ozek MM, Pamir MN. A retrospective review of cervical corpectomy: indications complications and outcome. Acta Neurochir (Wien) 2004; 146 (10): 1099-1105.
- 13- Patel CK, Fischgrund JS. Complications of anterior cervical spine surgery. Instr Course Lect 2003; 52: 465-469.
- 14- Pedram M, Castagnera L, Carot X, Macouillard G, Vital JM. Pharyngolaryngeal lesions in patients undergoing cervical surgery through the anterior approach: contribution of methylprednisolone. Eur Spine J 2003; 12 (1) : 84-90.



- 15- Pollard ME, Little PW. Changes in carotid artery blood flow during anterior cervical surgery. *Spine* 2002; 27 (2): 152-155.
- 16- Rappoport LH, O'leary PF. Cervical Disc Disease. In : *The Textbook of Spinal Surgery*, 2nd Ed., Bridwell KH, DeWald RL (Eds.), Lippincott – Raven Publishers, Philadelphia, 1997; pp: 1373-1396.
- 17- Sagi HC, Beutler W, Carroll E, Connolly PJ. Airway complications associated with surgery on the anterior spine. *Spine* 2002; 27 (9): 949-953.
- 18- Samandouras G, Shafafy M, Hamlyn PJ. A new anterior cervical instrumentation system combining intradiscal cage with an integrated plate: an early technical results. *Spine* 2001; 26 (10): 1188-1192.
- 19- Sekhon LH, Sears W, Duggal N. Cervical arthroplasty after previous surgery: results of treadsises in 15 patients. *J Neurosurg Spine* 2005; 3(5): 335-341.
- 20- Shapiro S, Connolly P, Donaldson J, Abel T. Cadaveric fibula, cervical locking plate, and allogeneic bone matrix anterior cervical fusions after cervical discectomy for radicular or myelopathy. *J Neurosurg* 2001; 95(1 Suppl.): 43-50.
- 21- Smith MD. Cervical spondylosis. In: *The Textbook of Spinal Surgery*, 2nd Ed., Bridwell KH, DeWald RL (Eds.), Lippincott – Raven Publishers, Philadelphia, 1997; pp: 1397-1419.
- 22- Taunt CJ, Sidhu KS, Andrew SA. Somatosensory evoked potential monitoring during anterior discectomy and fusion. *Spine* 2005; 30(17): 1970-1972.
- 23- Terao Y, Matsumoto S, Yamashita K, Takada M, Inadomi C, Fukusaki M, Sumikawa K. Increased incidence of emergency airway management after combined anterior-posterior cervical spine surgery. *J Neurosurg Anesthesiol* 2004; 16 (4): 282-286.
- 24- Tumialan LM, Wippold FJ, Morgan RA. Tortuous vertebral artery injury complicating anterior cervical fusion in a symptomatic rheumatoid cervical spine. *Spine* 2004; 29(16): E343-348.
- 25- Vanderveldt HS; Young MF. The evaluation of dysphagia after anterior cervical spine scase report. *Dysphagia* 2003; 18 (4): 301-304.
- 26- Wang JC, Hart RA, Emery SE, Bohlman HH. Graft migration or displacement after multilevel cervical corpectomy and strut grafting. *Spine* 2003; 28 (10): 1016-1021.
- 27- Wang MY, Green BA. Laminoplasty for the treatment of failed anterior cervical surgery. *Neurosurg Focus* 2003; 15 (3): E7.
- 28- Wang J, Liang FG, Qu DB, Jin DD. Risk factor analysis of early complications following ante surgery in cases of cervical spondylotic myelopathy. *Di Yi Jun Yi Da Xue Xue Bao* 2005; 25 (4): 450-453 (English Abstract).
- 29- Winslow CP, Winslow TJ, Wax MK. Dysphonia and dysphagia following the anterior approach cervical spine. *Arch Otolaryngol Head Neck Surg* 2001; 127 (1): 51-55.
- 30- Woodard EJ, Leon SP, Moriarty TM, Quinones A, Zamani AA, Jolesz FA. Initial experience with intraoperative magnetic resonance spine surgery. *Spine* 2001; 26(4): 410-417.
- 31- Yeh YC, Sun WZ, Lin CP, Hui CK, Huang IR, Lee TS. Prolonged retraction on the normal common carotid artery lethal stroke after cervical spine surgery. *Spine* 2004; 29 (19): E431-434.

