

THE MORPHOMETRY OF THORACIC PEDICLES AND PEDICLE-RIB UNITS AND THEIR RELATIONS TO AORTA: AN MRI STUDY

TORAKAL PEDİKÜL VE PEDİKÜL-KOT ALANININ MORFOMETRİSİ VE BUNLARIN AORTA İLE OLAN İLİŞKİLERİNİN MANYETİK REZONANS GÖRÜNTÜLEME YÖNTEMİ İLE ARAŞTIRILMASI

Levent KARAPINAR*, Nuri EREL**, Ahmet KAYA*, Taşkın ALTAY*

SUMMARY:

Aim: The objective of the study is to determine the safe and reliable area in thoracic spine that application of intrapedicular screw is difficult.

Materials and Methods: A study group is constituted 42 adults (21 men, 21 women) who have no medical history about thoracic spine. The mean age was 36.7(16-56) years old. True axial cross sections passing through both pedicles between T1 to T12 were taken with MRI. On these MRI cross sections, width of transverse intraosseous pedicle, width of transverse intraosseous (Pedicule Rib Unit) PRU, length of pedicle screw path, length of PRU screw path, relation of pedicle screw path with aorta and relation of PRU screw path with aorta were measured with the help of a computer programme.

Results: A statistically significant difference was found on each level between the transverse intraosseous width of pedicle and those of PRU, and length of pedicle screw

path and those of PRU. While injury risk for aorta is high on the left side when the conventional pedicle screw path is used, it is high on the right side when PRU screw path is used.

Conclusions: When we compared PRU screw path with those of conventional pedicle screw path in point of neurological injury risk; PRU screw path provide us to keep away from epidural space. On the contrary, the injury risk of aorta is high at the right side PRU screw path used and is high at the left side when the conventional pedicle screw path used. Hybrid application (the using of PRU screw path at the left side and the using of conventional screw path at the right side) may minimize both neurological and aortic injury risk when the pedicle width is adequate.

Keywords : Pedicle screw, pedicle-rib unit, aorta, MRI

Level of Evidence: Cilinical Study, Level III

(*) Orthopaedic surgeon, Department of Orthopaedics and Traumatology, Izmir-Tepecik Training and Research Hospital, Izmir.

(**) Orthopaedic surgeon, Department of Orthopaedics and Traumatology, Izmir-Izmir Training and Research Hospital, Izmir.

ÖZET:

Amaç: Pedikül içerisinden vida uygulamanın zor olduğu torakal omurgada daha güvenli ve sağlam bir alanı ortaya koymak.

Materyal - Metod: Torakal omurgasına ait hiçbir yakınması olmayan 42 erişkin (21 erkek, 21 kadın) çalışma grubunu oluşturdu. Yaş ortalaması 36.7(16-56) idi. T1'den T12'ye kadar manyetik rezonans görüntüleme (MRG) ile gerçek aksiyel kesitler elde edildi. MRG kesitlerinde transvers pedikül çapı, transvers pedikül-kot alanı çapı, pedikül vida yolu uzunluğu, pedikül-kot alanı vida yolu uzunluğu, pedikül vida yolunun aorta ile ilişkisi, pedikül-kot alanı vida yolu ile aorta ilişkisi bilgisayar programı aracılığı ile ölçüldü.

Sonuçlar: Pedikül ile pedikül-kot alanı çapı arasında ve pedikül vida yolu uzunluğu ile pedikül-kot alanı vida yolu uzunluğu arasında

istatistiksel olarak anlamlı fark tespit edildi. Konvansiyonel vida yolu kullanıldığında sol tarafta yüksek olan aorta yaralanma riski, pedikül-kot alanı vida yolu kullanıldığında sağ tarafta yüksektir.

Çıkarım: Nörolojik yaralanma riski açısından pedikül vida yolu ve pedikül-kot alanı vida yolu karşılaştırıldığında pedikül-kot alanı epidural alandan uzak bir vida yolu sağlamaktadır. Buna karşın aorta yaralama riski pedikül-kot alanı kullanıldığında sağ tarafta, pedikül vida yolu kullanıldığında sol tarafta yüksektir. Hibrid uygulama (sol tarafta pedikül-kot vida yolu, sağ tarafta konvansiyonel pedikül yolunun kullanımı) pedikül çapının uygun olduğu olgularda hem nörolojik, hem de aort yaralanma riskini azaltabilir.

Anahtar Kelimeler: pedikül vidası, pedikül-kot alanı, aorta, MRG

Kanıt Düzeyi: Klinik Çalışma, Düzey III

INTRODUCTION:

Pedicle screw fixation has marked advantages compared with traditional methods of internal fixation in thoracic trauma, instability, deformity and scoliosis^(6,10,25,27). However, appropriate candidates for transpedicular thoracic fixation must be carefully selected, and its application is limited by the too narrowness of pedicles or scoliosis, especially between the third and ninth thoracic vertebrae, and potential harms to surrounding vital structures^(2,23,28). Furthermore, the accuracy of screw placement in the thoracic spine is in question^(23,28). An increasing number of investigations evaluate a safe technique for pedicle screw placement in the thoracic spine^(7-8,13,15,19,22,24,28). Despite some of them report very successful results^(3,12,15,16), the others are cautious about this method^(23,28).

Dvorak et al. presented an extrapedicular thoracic screw placement technique first in an in-vitro study; screws were started lateral to the tip of the transverse process and advanced through the rib and costovertebral joint into the vertebral body⁽¹⁾. Also, a few researchers have attracted attention to advantages of long screw path and the wide area in an extrapedicular zone, named pedicle-rib unit^(7-8,17,19-20). However, relation of PRU screw path and aorta was not evaluated to our knowledge.

Review of the literature revealed only a few studies about PRU (extrapedicular area) as an alternative method for application of screw into the pedicle. However, the morphometry of the pedicle-rib unit has been described only in patients with scoliosis and normal cadaveric thoracic spine^(7,17,20). There are no morphometric studies that define PRU in normal adult thoracic spine.

The objective of this study is to compare PRU and pedicle morphometry with MRI in normal adult population, and to investigate the possible

injury risk of the thoracic aorta when using the both screw application methods.

MATERIAL AND METHODS:

42 adults who have no complaints in thoracic spine constituted the study group. MRI images were taken by using 1.5-tesla magnetom vision unit (Toshiba Excel Art, Japan).

At first, the MRI of six subjects were used for intra and interobserver analyses. Two investigators with 13 (LK) and 14 (AK) years of experience, measured the images and repeated it a week later. We assessed intraobserver and interobserver reliability of the morphometric measurements with the intraclass correlation coefficient of reliability and its 95% confidence interval as described by Fleiss⁽²⁴⁾.

For investigation of pedicle and PRU anatomy and their relations with aorta, the MRI gantry was aligned to allow transverse images to be obtained through both pedicles from T1 through T12. Because of dorsal kyphosis, to prevent deviations from anatomic axial position, the axial images parallel to pedicles were planned through parasagittal cross sections including both pedicles. Because T1 and T12 are not proper to from PRU, both of them are excluded from the study. All images were recorded on a CD. Measurements were done by using e-film medical imaging system program by magnifying these images in computer.

The measurements in the transverse plan included the width of transverse intraosseous pedicle, the width of transverse intraosseous PRU, the length of pedicle screw path, the length of the PRU screw path, the distance of pedicle screw path to aorta, the distance of pedicle-rib unit screw path to aorta (fig1). While measurements were being done, medial and lateral walls of pedicle and pedicle-rib unit were accepted as a safe zone and only intraosseous area was measured.

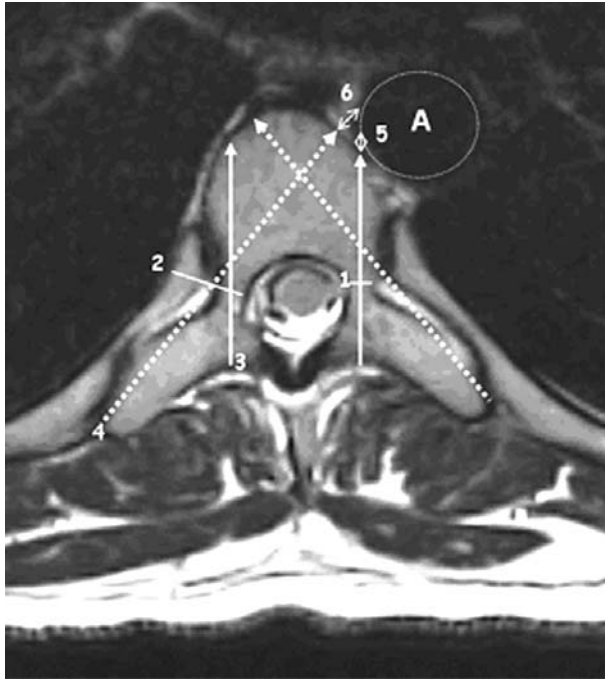


Figure 1. T1-weighted axial magnetic resonance image demonstrating the manner in which the width of transverse intraosseous pedicle(1), the width of transverse intraosseous pedicle-rib unit(2), the length of pedicle screw path(3), the length of pedicle-rib unit screw path(4) were measured. The distance of pedicle screw path to aorta(5) and the distance of pedicle rib-unit to aorta(6) were measured from the outer aspect of the the wall of aorta (A) to the nearest of the vertebral body.

However, when we continued from cortex point that screw paths go over in both zones and measured the distance from aorta, if there was a contact, by measuring its distance from aorta, it was evaluated as high risk for 0-2 mm, moderate for 3-5 mm, mild for 5-10 mm and as safe area for over 10 mm and no contact. Additionally, the risk for each vertebra was evaluated. Statistical analyses were performed by unpaired samples t test, paired samples t test, Mc Nemar test using SPSS (Version 13).

RESULTS:

Statistical analyses showed an excellent intra (0.99-1.0 in 95% confidence) and inter (1.0 in 95% confidence) observer reliability.

The study group was constituted twenty-one female and twenty-one male who had no problem or complaint from thoracic spine. The mean age of them was 36.7 (16-56) years old. The pedicle widths and PRU widths, and the length of pedicle screw paths and the length of PRU screw paths were shown comparatively in Table 1.

Table - 1. Minimum and maximum values, means and standard deviations of the each screw path's width and length for the left and right sides, and for the females and males,

	Left/Right and vertebral Level	Mean Pedicle Width (mm)	Mean Pedicle Rib Unit Width	Mean Length of Pedicle path (mm)	Mean Length of Pedicle Rib Unit Path (mm)
T2L	All	3.86±1.22(2-7)	11.60±2.85(8-22)	31.10±3.92(22-41)	50.81±5.56(41-66)
	Male	4.24±1.22(2-7)	13.14±3.04(20-22)	33.00±3.42(27-41)	54.38±5.06(44-66)
	Female	3.48±1.12(2-6)	10.05±1.53(8-14)	29.19±3.50(22-36)	47.24±3.32(41-54)
T2R	All	3.90±1.28(2-8)	11.64±2.78(8-21)	31.07±4.03(24-41)	50.67±5.44(42-65)
	Male	4.29±1.35(2-8)	13.19±2.86(10-21)	32.95±3.64(26-41)	54.38±4.76(45-65)
	Female	3.52±1.12(2-6)	10.10±1.64(8-14)	29.19±3.56(24-36)	46.95±3.02(42-54)
T3L	All	3.43±0.89(2-5)	10.64±2.16(7-16)	32.57±3.83(23-43)	53.52±4.91(44-63)
	Male	3.71±0.90(2-5)	11.81±2.02(8-16)	34.10±3.81(27-43)	56.52±4.07(48-63)
	Female	3.14±0.79(2-5)	9.48±1.63(7-14)	31.05±3.26(23-36)	50.52±3.74(44-57)
T3R	All	3.48±0.86(2-5)	10.69±2.27(7-16)	32.76±3.74(25-43)	53.55±4.90(45-64)
	Male	3.71±0.90(2-5)	11.90±2.17(8-16)	34.29±3.78(27-43)	56.67±3.89(48-64)
	Female	3.24±0.77(2-5)	9.48±1.66(7-14)	31.24±3.08(25-36)	50.43±3.70(45-57)
T4L	All	3.26±0.80(2-5)	10.64±2.02(8-16)	34.52±4.13(25-44)	56.10±5.04(48-67)
	Male	3.52±0.75(2-5)	11.86±1.96(8-16)	35.95±3.88(28-44)	59.05±4.68(49-67)
	Female	3.00±0.77(2-5)	9.43±1.21(8-13)	33.10±3.95(25-42)	53.14±3.44(48-60)

Table - 1. Minimum and maximum values, means and standard deviations of the each screw path's width and length for the left and right sides, and for the females and males, (devam)

	Left/Right and vertebral Level	Mean Pedicle Width (mm)	Mean Pedicle Rib Unit Width	Mean Length of Pedicle path (mm)	Mean Length of Pedicle Rib Unit Path (mm)
T4R	All	3.31±0.78(2-5)	10.62±2.00(8-16)	34.64±3.91(28-44)	56.26±4.98(48-67)
	Male	3.52±0.75(2-5)	11.76±1.92(8-16)	35.81±4.01(28-44)	59.19±4.56(49-67)
	Female	3.10±0.77(2-5)	9.48±1.33(8-13)	33.48±3.52(28-43)	53.33±3.48(48-61)
T5L	All	3.26±0.86(2-5)	10.90±2.09(7-17)	36.43±4.27(28-46)	58.26±5.49(47-70)
	Male	3.57±0.87(2-5)	12.05±2.16(8-17)	38.05±4.14(32-46)	61.48±5.14(49-70)
	Female	2.95±0.74(2-5)	9.76±1.26(7-13)	34.81±3.83(28-44)	55.05±3.69(47-62)
T5R	All	3.21±0.78(2-5)	10.86±2.08(7-17)	36.50±4.17(28-46)	58.40±5.57(47-70)
	Male	3.48±0.75(2-5)	12.00±2.05(8-17)	38.14±4.30(31-46)	61.71±5.22(49-70)
	Female	2.95±0.74(2-5)	9.71±1.38(7-13)	34.86±3.38(28-43)	55.10±3.66(47-62)
T6L	All	3.81±0.92(2-6)	11.19±2.13(8-18)	38.12±4.79(29-48)	59.88±5.65(51-72)
	Male	4.10±0.83(2-6)	12.33±2.18(8-18)	40.10±4.65(32-48)	63.29±5.23(51-72)
	Female	3.52±0.93(2-6)	10.05±1.36(8-14)	36.14±4.15(29-47)	56.48±3.71(51-66)
T6R	All	3.83±0.93(2-6)	11.17±2.08(8-18)	38.38±5.00(28-48)	59.64±5.54(50-71)
	Male	4.10±0.83(3-5)	12.29±2.08(8-18)	40.52±4.93(32-48)	62.90±5.27(51-71)
	Female	3.57±0.98(2-6)	10.05±1.40(8-14)	36.24±4.17(28-46)	56.38±3.58(50-65)
T7L	All	4.14±0.90(2-6)	11.38±2.25(8-18)	40.00±4.85(31-51)	60.67±5.77(51-72)
	Male	4.48±0.68(3-6)	12.62±2.11(9-18)	42.10±4.74(33-51)	64.38±5.08(54-72)
	Female	3.81±0.98(2-6)	10.14±1.65(8-15)	37.90±4.07(31-49)	56.95±3.67(51-66)
T7R	All	4.12±0.92(2-6)	11.52±2.27(8-18)	40.17±4.88(32-51)	60.81±5.98(51-72)
	Male	4.43±0.68(3-6)	12.71±2.10(9-18)	42.29±4.83(33-51)	64.76±4.96(54-72)
	Female	3.81±1.03(2-6)	10.33±1.77(8-15)	38.05±4.02(32-48)	56.86±3.98(51-67)
T8L	All	4.48±0.99(2-7)	12.02±2.16(9-18)	41.43±4.64(34-54)	61.24±5.95(47-72)
	Male	4.81±0.75(3-6)	13.14±1.85(10-18)	43.43±4.84(36-54)	64.71±4.52(54-72)
	Female	4.14±1.11(2-7)	10.90±1.87(9-17)	39.43±3.52(34-49)	57.76±5.19(47-67)
T8R	All	4.45±1.04(2-7)	12.29±2.19(9-18)	41.50±4.64(32-53)	61.05±6.04(46-72)
	Male	4.81±0.81(3-6)	13.33±1.98(10-18)	43.52±4.65(36-53)	64.43±4.66(54-72)
	Female	4.10±1.14(2-7)	11.24±1.89(9-17)	39.48±3.74(32-49)	57.67±5.38(46-67)
T9L	All	4.98±0.10(2-8)	12.74±2.04(9-18)	42.43±4.51(34-54)	60.12±5.37(50-69)
	Male	5.33±0.73(4-7)	13.71±1.87(10-18)	44.62±3.98(38-54)	63.43±4.39(54-69)
	Female	4.62±1.12(2-8)	11.76±1.73(9-18)	40.24±3.96(34-50)	56.81±4.12(50-65)
T9R	All	5.02±1.00(2-8)	12.83±2.02(9-18)	42.62±4.27(34-53)	60.05±5.52(49-69)
	Male	5.38±0.74(4-7)	13.86±1.88(10-18)	44.62±3.87(38-53)	63.38±4.67(54-69)
	Female	4.67±1.11(2-8)	11.81±1.63(9-17)	40.62±3.73(34-53)	56.71±4.16(49-66)
T10L	All	5.69±1.00(4-9)	13.86±2.17(10-19)	43.21±4.38(36-54)	57.88±6.08(48-68)
	Male	5.90±0.83(5-8)	14.90±1.92(10-19)	45.52±3.71(40-54)	61.71±4.91(52-68)
	Female	5.48±1.12(4-9)	12.81±1.91(10-19)	40.90±3.79(36-50)	54.05±4.57(48-62)
T10R	All	5.64±1.01(4-9)	13.90±2.23(10-19)	43.33±4.19(36-54)	57.62±6.00(47-68)
	Male	5.86±0.85(5-8)	15.05±1.94(11-19)	45.38±3.75(39-54)	61.24±4.96(50-68)
	Female	5.43±1.12(4-9)	12.76±1.92(10-19)	41.29±3.64(36-50)	54.00±4.66(47-63)
T11L	All	6.29±0.94(4-10)	14.14±2.14(10-20)	45.02±4.36(38-56)	55.31±5.90(44-66)
	Male	6.48±0.60(6-8)	15.14±1.80(12-20)	47.48±3.84(42-56)	58.95±4.27(49-66)
	Female	6.10±1.18(4-10)	13.14±2.01(10-19)	42.57±3.41(38-51)	51.67±5.03(44-61)
T11R	All	6.31±0.98(4-10)	14.14±2.10(10-20)	45.00±4.48(37-56)	54.79±6.18(42-66)
	Male	6.57±0.68(6-8)	15.05±1.86(12-20)	47.43±4.02(39-56)	58.57±4.55(48-66)
	Female	6.05±1.16(4-10)	13.24±1.97(10-19)	42.57±3.54(37-51)	51.00±5.24(42-60)

The difference between mean pedicle width and mean pedicle-rib unit, and between mean length of pedicle path and mean length of pedicle rib unit path are significant for all levels and genders ($p<0.001$).

When we evaluated the screw path-aorta relations as high, moderate and mild risk, the following results were obtained consecutively: 0.3%, 0.3% and 2.7% at right pedicular screw path; 8.9%, 24.7% and 34.2% at left pedicular screw path; 10.1%, 21.7% and 22.6% at right PRU screw path and finally 0.9%, 0.9% and 3.6% at left PRU screw path. The highest high risk at either left pedicular screw path or right PRU screw path was observed especially in lower thoracic spines (T_{9,10,11}).

While the injury risk of the thoracic aorta between T4-11 was measured as 3.3% on the right side and the 67.8% on the left side when conventional pedicle screw path used (p<0.001). It was measured as 44.4% on the right side and 4.4% on the left side when the extrapedicular method was used (p<0.001). Relationships of screw paths driven at optimal angles and centralizing the pedicles and PRU's in with thoracic aorta were shown in Table 2.

Table - 2. Relationship of pedicle and pedicle rib unit with thoracic aorta (security rate)

Level	Right pedicle	Left pedicle	Right PRU	Left PRU
T ₄	97.6~	57.1•	66.7•	92.9~
T ₅	100*	45.2#	69•	100*
T ₆	100*	45.2#	66.7•	100*
T ₇	100*	42.9#	57.1•	100*
T ₈	100*	38.1#	42.9#	100*
T ₉	95.2~	16.7#	35.7#	95.2~
T ₁₀	90.5~	9.5#	14.3#	90.5~
T ₁₁	90.5~	2.4#	11.9#	78.6•

*Safe 100% ~Mild risk (81-99%) oModerate risk (51-80%) #High risk (0-50%)

Screw application from PRU on the right side seems to have more risk for aorta compared with screw application conventionally into pedicles. Contrary, since aorta is located in the left side and conventional pedicle screw application is relatively has less

safer area; using PRU screw path provides to avoid from both epidural space and aorta.

DISCUSSION:

The aim of each spinal surgeon is to apply rigid and safe method by avoiding risks as possible as in thoracic spine. Morphological studies carried out in thoracic spine revealed that pedicles are narrow especially in middle and upper zones ^(2,7,17,20,22-23,26). Placing thoracic pedicle screw carries neurological injury risk in high proportion caused by complex and varied anatomy of thoracic pedicles ^(2,17,23,26,28).

Gross examination of the spinal canal after total laminectomy showed that the lateral aspect of the dural sac contacts with the medial wall of the pedicle in all 15 cadavers ⁽²⁾. However, Suk et al. inserted 4604 thoracic pedicle screws in spinal deformities and 67 screw malpositions (1.5%) occurred in 48 patients. The malpositions were lateral in 18 (27%), medial in 4 (6%). There was a transient paraparesis in one patient with neurofibromatosis. The neurological injury was due to medial perforation of the pedicle by the screw causing delayed epidural hematoma ⁽²⁵⁾.

Kim et al reported that free hand thoracic screw application technique was successful in both normal and deformed thoracic spine⁹. We calculated the percentage of the screws penetrating the cortex of the pedicle. This calculation was done by assuming that we have placed screws 4 mm, of 5 mm and 6 mm of diameters, driven at proper angle from the centers of the pedicles. It appears that screws can damage cortex in high proportion even though screws are placed at suitable entering point and again at optimal angles. When all pedicle diameters are evaluated, 18.8 % of the

screw is located in intraosseous area when 6 mm screw was applied, 44 % for 5 mm, 66.7 % for 4 mm. It appears unavoidable that screws that will be applied to the pedicles out of these proportions with conventional method damage pedicle cortex run over the pedicle. This may not only increase the risk of neurological injury but also may create stability problems⁽¹²⁾. T₁₀, T₁₁ vertebrae constitute 74.1% of this proportion of 18.8%; T₉, T₁₀, T₁₁ vertebrae constitute 72.4% of the proportion of 44%. However, all of the screws of 4 mm, 5 mm and 6 mm are located in intraosseous area when PRU is assumed as screw path.

There are three papers concerning about the PRU morphology in the literature^{7,17,20}. However, the subjects were adolescent idiopathic scoliosis (AIS) cases in two^(17,20), and cadavers in the remaining⁷. In our opinion, our series is somewhat different, aiming to obtain normal values. In the series of Liljenqvist, O'Brien, the results are valid only for scoliotic patients. Similarly, the study of Husted may be evaluated as experimental for no living subjects were included in the study. Furthermore, due to the nature of these studies the age groups highly differ from the present study that two of them include adolescent patients while the other was performed in cadavers of elder subjects.

Nevertheless, in both of the studies done with CT, the outer cortex diameters were measured^(7,20). In our study, medial and lateral walls of pedicle and pedicle-rib unit were accepted as a safe zone and only intraosseous area was measured to determine accurate screw width not to lead the injury of the cortex⁽¹²⁾. However, advantages of digital imaging and computer software measurement include elimination of error from different marking pencils and protractors and the ability to

change brightness, contrast, and magnification⁽³⁰⁾. In addition, evaluation of intra and interobserver reliability help us to provide accurate and reliable results^(14,30).

Vaccaro et al demonstrated that the thoracic aorta was at greatest risk for injury in cases of anterior cortex penetration by the screws on the left side by using conventional intrapedicular technique⁽²⁸⁾. Liljenqvist et al reported that the closest distance between the thoracic aorta and the vertebral body was an average of 6 mm at the fourth, fifth, and sixth thoracic vertebrae; 7 mm at the seventh, eighth, and ninth thoracic vertebrae; and 4 mm at the tenth thoracic vertebra. At the eleventh thoracic vertebra, the closest distance measured an average of 3 mm. But Vaccaro and et al stated that the distance between thoracic aorta and vertebral body was less than 5 mm between the sixth to twelfth thoracic vertebrae²⁸. Despite the distance between aorta and the vertebral body was measured in these studies, the screw path aorta relations was not considered.

Additionally, pleural lining of the thoracic cavity is in contact with the inferolateral wall of the pedicle⁽²⁸⁾. A breach of few millimeters of the anterior or anterolateral cortical boundaries of the vertebral body may not initially damage the adjacent soft-tissue structures because of the mobility of these structures. However chronic irritation, especially to the pulsatile aorta, can lead to lethal complications and must be avoided. A few cases of delayed aortic rupture following anterior spinal instrumentation were reported^(18,21,31). Our study supports these findings. We observed that the injury risk to thoracic aorta when the screw directed from pedicle conventionally is higher than those of PRU at the left side. We suggest that the direction of the screw from PRU at the left side is more reliable when compared with pedicle.

The accuracy of magnetic resonance imaging for measurements of pedicle width may be influenced by the increased susceptibility effect between cortical and cancellous bone, which results in a less clear depiction of the cortical structures compared with that seen on computed tomography. This phenomenon can lead to a slight underestimation of the endosteal pedicle width on magnetic resonance imaging ⁽¹⁷⁾. However, MRI is both highly reliable and accurate and helps us to obtain true axial images preventing the faultier results as well as do not use ionizing radiation as CT¹⁶.

Detailed preoperative MRI's can lead us to analyzing the screw application area as well as avoiding from neurological and vascular complications and determining the safe zones and directions. We concluded that the hybrid method one of which was directed from pedicle and the other was directed from PRU which has adequate biomechanical stability ⁽²⁹⁾, this might be as an alternative method based on the results of our study. But in hybrid application method the rods may be on different planes in the coronal aspect because of the entering points of PRU and pedicle were not on same level. Excision of some posterior portion of PRU

with a rongeur may be necessary to balance. Evaluation of PRU by preoperative MRI may be a guide for spinal surgeons in using transverse process wiring method, which provides segmental fixation possibility by avoiding neurovascular structures 5,30. It is essential that spinal surgeons should have knowledge about the position of aorta while they are placing screw to thoracic spine. And they should also considered the pedicle diameters, length of pedicle screw path and the angle between the screw path and midline.

CONCLUSION:

PRU path allows us to apply wider and longer screw path area with avoiding neurological injury, and the risk of aorta injury is high at left side when using pedicular screw path and this high risk is current for PRU path at right side. So, hybrid method (right pedicular screw and left PRU screw) may be an alternative method in order to avoid aorta injury if the anatomical structure of the pedicle is appropriate. In addition, in the circumstance of pedicle explosion or injury when using pedicular screw path, PRU should be considered as an alternative method.

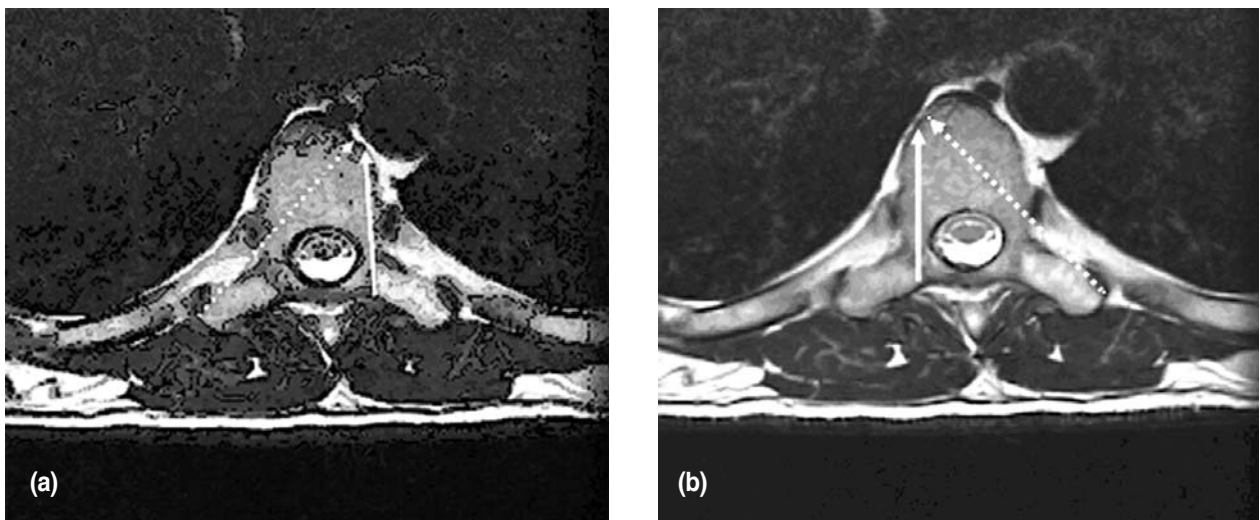


Figure 2. Comparison of pulsatile aorta injury risk. Direction of the screw paths of pedicle from left side and of pedicle-rib unit from right side **(a)**. Direction of the screw paths of pedicle from right side and of pedicle rib unit from left side **(b)**.

REFERENCES:

1. Dvorak M, MacDonald S, Gurr KR, et al. An anatomic, radiographic, and biomechanical assessment of extrapedicular screw fixation in the thoracic spine. *Spine* 1993; 18(12): 1689-1694.
2. Ebraheim NA, Jabaly G, Xu R, et al. Anatomic relations of the thoracic pedicle to the adjacent neural structures. *Spine* 1997; 22: 1553-1556.
3. Erel N, Sebik A, Karapinar L, et al. Transverse process wiring for thoracic scoliosis: A new technique. *Acta Orthop Scand* 2003; 74: 312-321.
4. Fleiss JL. Design and Analysis of Clinical Experiments. New York: *John Wiley and Sons*, 1999.
5. Fujita M, Diab M, Xu Z, et al. A biomechanical analysis of sublaminar and subtransverse process fixation using metal wires and polyethylene cables. *Spine* 2006; 31: 2201-2208.
6. Gertzbein SD, Robbins SE. Accuracy of pedicular screw placement in vivo. *Spine* 1990; 15: 11-14.
7. Husted DS, Haims AH, Fairchild TA, et al. Morphometric comparison of the pedicle rib unit to pedicles in the thoracic spine. *Spine* 2004; 29: 139-146.
8. Husted DS, Yue JJ, Fairchild TA, et al. An extrapedicular approach to the placement of screws in the thoracic spine: An anatomic and radiographic assesment. *Spine* 2003; 28: 2324-2330.
9. Kim YJ, Lenke GL, Bridwell KH, et al. Free hand pedicle screw placement in the thoracic spine: Is it safe? *Spine* 2004; 29: 333-342.
10. Kim YJ, Lenke LG, Cho SK, et al. Comparative analysis of pedicle screw versus hook instrumentation in posterior spinal fusion of adolescent idiopathic scoliosis. *Spine* 2004; 29: 2040-2048.
11. Kim YJ, Lenke LG, Cheh G, et al. Evaluation of pedicle screw placement in the deformed spine using intraoperative plain radiographs: A comparison with computerized tomography. *Spine* 2005; 30: 2084-2088.
12. Kothe R, Panjabi M, Liu W. Multidirectional instability of the thoracic spine due to iatrogenic pedicle injuries during transpedicular fixation: A biomechanical investigation. *Spine* 1997; 22: 1836-1842.
13. Kothe R, Strauss JM, Deuretzbacher G, et al. Computer navigation of parapedicular screw fixation in the thoracic spine. A cadaver study. *Spine* 2001 ;26: E496-E501.
14. Kuklo TR, Potter BK, O'Brien MF, et al. Reliability analysis for digital adolescent idiopathic scoliosis measurements. *J Spinal Disord Tech* 2005; 18: 152-159.
15. Lehman RA, Polly DW, Kuklo TR, et al. Straight-Forward versus anatomic trajectory technique of thoracic pedicle screw fixation: A biomechanical analysis. *Spine* 2003; 28: 2058-2065.
16. Leitzes AH, Potter HG, Amaral T, et al. Reliability and accuracy of MRI scanogram in the evaluation of limb length discrepancy. *J Pediatr Orthop* 2005; 25: 747-749.
17. Liljenqvist UR, Allkemper T, Hackenberg L, et al. Analysis of vertebral morphology in idiopathic scoliosis with use of magnetic resonance imaging and multiplanar reconstruction. *J Bone Joint Surg Am* 2002; 84: 359-368.
18. Matsuzaki H, Tokuhashi Y, Wakabayashi K, et al. Penetration of a screw into the thoracic aorta in anterior spinal instrumentation. A case report. *Spine* 1993; 18: 2327-2331.
19. Morgenstern W, Ferguson SJ, Berey S, et al. Posterior thoracic extrapedicular fixation: A biomechanical study. *Spine* 2003; 28: 1829-1835.
20. O'Brien MF, Lenke LG, Mardjetko S, et al. Pedicle morphology in thoracic adolescent idiopathic scoliosis. Is pedicle fixation an anatomically viable technique? *Spine* 2000; 25: 2285-2293.
21. Ohnishi T, Neo M, Matsushita M, et al. Delayed aortic rupture caused by an implanted anterior spinal device. Case report. *J Neurosurg* 2001; 95: 253-256.
22. Parent S, Labelle H, Skalli W, et al. Thoracic pedicle morphometry in vertebrae from scoliotic spines. *Spine* 2004; 29: 239-248.
23. Potter BK, Lehman RA, Kuklo TR. Anatomy and biomechanics of thoracic pedicle screw instrumentation. *Curr Opin Orthop* 2004; 15: 133-141.

24. Smorgick Y, Millgram MA, Anekstein Y, et al. Accuracy and safety of thoracic pedicle screw placement in spinal deformities. *J Spinal Disord Tech* 2005; 18: 522-526.
25. Suk S, Kim WJ, Lee SM, et al. Thoracic pedicle screw fixation in spinal deformities: Are they really safe? *Spine* 2001; 26: 2049-2057.
26. Ugur HC, Attar A, Uz A, et al. Thoracic pedicle: Surgical anatomic evaluation and relations. *J Spinal Disord* 2001;14:39-45.
27. Vaccaro AR, Rizzolo SJ, Balderston, et al. Placement of pedicle screw in the thoracic spine. Part I: Morphometric analysis of the thoracic vertebrae. *J Bone Joint Surg (Am)* 1995; 77:1193-1199.
28. Vaccaro AR, Rizzolo SJ, Balderston RA, et al. Placement of pedicle screws in the thoracic spine. Part II: An anatomical and radiographic assessment. *J Bone Joint Am* 1995; 77: 1200-1206.
29. White KK, Oka R, Mahar AT, et al. Pullout Strength of thoracic pedicle screw instrumentation. Comparison of the transpedicular and extrapedicular techniques. *Spine* 2006; 31: E355-358.
30. Wills BPD, Auerbach JD, Zhu X, et al. Comparison of Cobb angle measurement of scoliosis radiographs with preselected end vertebrae. *Spine* 2007; 32: 98-105.
31. Woolsey RM. Aortic laceration after anterior spinal fusion. *Surg Neurol* 1986; 25: 267-268.