



## THE APPLICATION OF ALICI SPINAL INSTRUMENTATION IN THE SURGICAL TREATMENT OF SCOLIOSIS<sup>+</sup>

### SKOLYOZ TEDAVİSİNDE ALICI SPİNAL ENSTRÜMANTASYONU UYGULAMALARI<sup>+</sup>

Emin ALICI \*, Nuri EREL \*\*, Serdar PEDÜKCOŞKUN \*\*\*, Tunç KABAKLIOĞLU \*\*\*

#### SUMMARY:

The surgical treatment of 34 patients with scoliosis was performed using anterior spinal and posterior spinal instruments. The instruments were designed in such a way that all of the frontal, sagittal, and axial deformities of the scoliotic curve would be corrected. The scoliosis was of idiopathic origin in 24 patients of paralytic origin in 5 patients and congenital in 5 patients. The age range was 10-23 (mean 13.7) and 22 of the patients were females and 12 of them were males. Anterior Spinal Instrumentation (ASI) was utilized in the correction of lumbar curves and the lumbar regions of thoracolumbar double curves and thoracolumbar curves. Thoracal curves and the

thoracolumbar curves on which ASI's had been applied were later corrected with posterior spinal instrumentations (PSI). All of the curves on which ASI's had been applied were further supported by PSI's. The patients in plastic casts were mobilized in a short period time. Successful results were obtained in the frontal, sagittal and axial planes, with the application of ASI and besides the correction of the deformity a physiological lumbar lordosis was also achieved.

**Key words:** Scoliosis, Alici Spinal Instrumentation.

**Level of evidence:** Level III, retrospective clinical study.

(\*) Professor of Orthopaedic Surgery, University Of Dokuz Eylül Medical Faculty, Department of Orthopaedic Surgery, İzmir.

(\*\*) Research Fellow, Orthopaedic Surgeon, University Of Dokuz Eylül Medical Faculty, Department of Orthopaedic Surgery, İzmir.

(\*\*\*) Research Fellow, University Of Dokuz Eylül Medical Faculty, Department of Orthopaedic Surgery, İzmir.

(<sup>+</sup>) Bu makale JTSS, 1990, 1 (1)'de Yayınlanmıştır. / That article was printed in JTSS, 1990, 1 (1) volume.

**Corresponding Address:** Professor Emin Alici, University Of Dokuz Eylül Medical Faculty, Department of Orthopaedic Surgery, İzmir.

**Phone:** +90 (232) 412 33 50

**e-mail:** ealici@deu.edu.tr

**ÖZET:**

İdiopatik skolyozu olan 34 hastaya anterior ve posterior enstrümantasyon uygulanarak cerrahi tedavileri yapılmıştır. Enstrümanlar skolyotik sagittal, frontal ve aksiyel deformiteleri düzeltmek üzere tasarlanmıştır. 24 hasta idiopatik, 5 hasta nöromusküler kaynaklı, 5 hasta konjenital skolyoza sahiptir. Yaş aralığı 10-23 (ortalama 13.7) olup, hastaların 22'si kadın ve 12'si erkektir. Anterior Spinal enstrümantasyon (ASI) lomber torakolomber ve çift majör eğriliklerin lomber eğriliklerini düzeltmek için kullanılmıştır. ASI uygulanan hastalarda torakal ve torakolomber eğriliklere

daha sonra posterior spinal enstrümantasyonla (PSI) düzeltilmiştir. ASI uygulanan hastalarda ayrıca anteriordan enstrümanite edilen lomber eğrilikleri de posterioran PSI ile desteklenmiştir. Hastalar kısa bir süre plastik alçı ile immobilize edilmişlerdir. ASI uygulamasıyla lomber bölgede fizyolojik lomber lordozun sağlanması yanı sıra, frontal, sagittal ve aksiyel planda başarılı bir düzeltmenin sağlandığı da belirlenmiştir.

**Anahtar Kelimeler:** Skolyoz, Alıcı Spinal Enstrümantasyonu

**Kanıt Düzeyi:** Düzey III, retrospektif klinik çalışma

## **INTRODUCTION:**

Scoliosis is a deformity of the vertebral column in the frontal, sagittal, and axial planes <sup>(1)</sup>.

In 1974, Dwyer and Schafer reported their results using Dwyer apparatus in double-curve pattern scoliosis.

In 1975, O'Brien et al <sup>(6)</sup> published an article on the combined use of Dwyer and Harrington instrumentation for the treatment of paralytic pelvic obliquity and, in 1978, Winter et al <sup>(9)</sup> mentioned the application of the same method for the treatment of adult scoliosis.

In 1975, Zielke first described his experience with a new method-Ventral derotation system (VDS) in the treatment of scoliosis. Hennemann <sup>(2)</sup> described the first 43 combined VDS and Harrington operations. In 1977, Micheli et al <sup>(4)</sup> noted that "The most frequent complaint of the adult patients who come to our clinic is intractable, unremitting type of back pain" and recommended the combined Dwyer-Harrington approach, especially for double balanced curvatures.

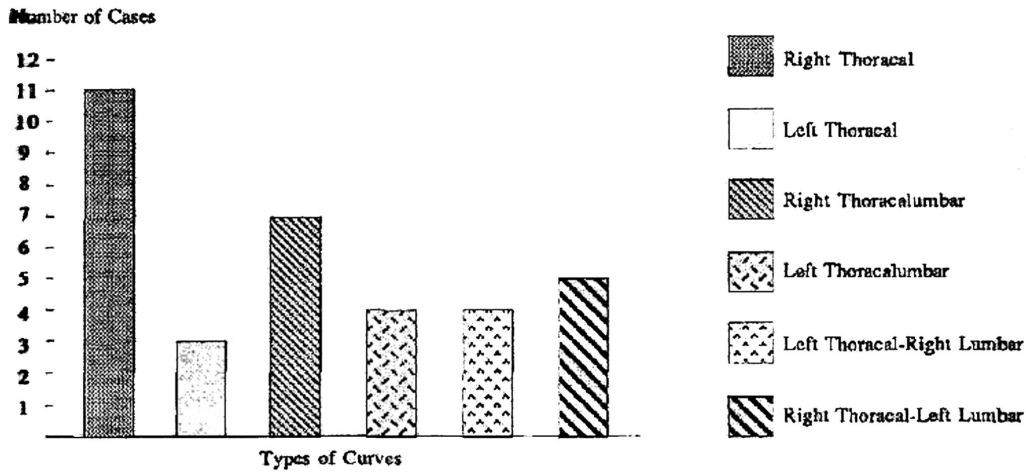
Using posterior correction (Harrington alone) and fusion in a patient who has a double structural right thoracic, left lumbar curve pattern we achieve only partial correction of each curve. The correction of the thoracic curve is often much better than of the lumbar (more structural). In the final evaluation, the end vertebra of the fusion area, usually L4, still remains tilted, thus lending increased possibilities for degeneration at the L4-L5 and L5 S1 interspaces. It would be preferable for long-term mechanics to have L4 be as horizontal as possible. The L4 could be centralized and made horizontal above the midsacrum more effectively by the combined VDS-Harrington technique than by posterior instrumentation alone. <sup>(3)</sup>

In the following report results of the application of the ALICI-ASI and ALICI-PSI in combination and separately are presented.

## **MATERYAL VE METOT:**

The ALICI spinal instruments are composed of grooved rods with flat surfaces varying in length from 4 inches to 12 inches and closed laminae, closed pedicle, open laminae, open pedicle hooks and of various nuts attaching these hooks to the rods. Due to the flat surfaces of the rods the grooves can bend without be connecting the rods which are placed on the right and left side of the spine as a pair with upper and lower transverse traction devices. In the A.S.I, system staples which cover the corpora, hooks with screws and telescopic nuts which fix the screws to the rods are present.

In the past year 34 patients with scoliosis were treated with the Alici spinal instruments in three hospitals in Izmir. In 17 of the patients first ASI and later PSI were performed in combination. In the remaining 17 patients correction was achieved by PSI only. Fusion was performed in all cases. 22 of the patients were females and 12 were males. The mean age was 13.7 (range 10-23). When the 34 cases were classified etiologically 5 of the cases were in the postpolio paralytical group, 24 cases were in the idiopathic scoliosis group and 5 were in the congenital group. According 10 the localization of the curves they were grouped as 11 right thoracic, 3 left thoracic, 7 right thoracolumbar, 4 left thoracolumbar, 4 left thoracic-right lumbar, 5 right thoracic- left lumbar (Table-1).



**Table - 1.** The distribution of the patients according to curve types.

In the P/A radiographs obtained in the standing position the thoracic curves were mean  $52.4^\circ$  (range  $30^\circ$ -  $98^\circ$ ) and the lumbar curves were mean  $36.28^\circ$  (range  $25^\circ$ - $44^\circ$ ). The mean curve of the congenital scoliosis group was  $57.8^\circ$  (range  $38^\circ$ - $80^\circ$ ) and the mean curve in the poliomyelitis scoliosis group was  $83^\circ$  (range  $50^\circ$ -  $135^\circ$ ). In the idiopathic scoliosis group the rotation degree measured by CT was mean  $19^\circ$  (range  $6.9^\circ$ - $37.8^\circ$ ). The mean rotation values measured were  $25.5^\circ$  (range  $16.6^\circ$ - $35.5^\circ$ ) for the congenital scoliosis and  $66.7^\circ$  range  $37.1^\circ$ - $78.3^\circ$ ) for the poliomyelitic scoliosis groups. (According to RA-AN1) We did not apply any radiological measurements on the sagittal plane neither at the preoperative nor at the postoperative periods because vertebral rotation can mask the curves on the sagittal plane.

Preoperative evaluation of all patients was standardized and included a careful neurologic evaluation, routine blood examinations, posterior-anterior (PA) and lateral standing radiographs and right and left supine maximum bending radiographs; pulmonary function testing; electrocardiogram and clinical photographs.

All immature curves above  $40^\circ$ , immature, progressive curves above  $30^\circ$  with a thoracic lordosis and resistant to conservative treatment, painful mature curves above  $50^\circ$  were included in the surgical treatment indication limits.

#### OPERATIVE TECHNIQUE:

In single thoracic curves a closed pedicle hook is inserted on the concave side pedicle of the vertebra at the apex of the curve. In order to make the operation easier and decrease the risk of complication the lamina and transverse process of the superior facet of the vertebra below should be decorticated. 2 spaces above the apical vertebra of the curve an open pedicle hook, two spaces below an open lamina hook and a closed lamina hook must be inserted to the lower most vertebra of the curve. A pair of rods appropriate to the length of the curve should be chosen and should be bended approximately  $20^\circ$ - $30^\circ$  all along the rods.

In order to achieve this curvature the rod should be bended from a the rod won't be damaged and the nuts will operate properly for each open hook a pair of telescopic nuts, for each of the lower and upper hooks a normal

nut should be mounted on the rod. The lamina at the concave side of the curve should be decorticated. The upper tip of the rod should be inserted in the upper hook and the lower tip should be slipped into the lower hook. The telescopic nuts should be rotated so that they will have the hooks inside and the rod should be inserted into the two hooks situated in the middle.

In order to rotate the telescopic nuts the middle hooks should be separated from each other (should be moved apart). After a certain degree of correction has been obtained at the apex of the curve the rod should be held from the middle part and rotated toward the concave side. It can be observed that by performing this procedure the frontal curvature turns to a physiological thoracic sagittal curve and the rotation is corrected. In order to fix the rod in this position the pair of telescopic nuts for each hook should be pressed towards each other and the rod should be locked to the hook. By rotating the upper and lower nuts so that the upper and lower hooks move away from each other, the correction should be increased a little more. A closed pedicle hook should be inserted to the facet joint of the upper tip vertebra in the convex side of the curve, a closed lamina hook should be placed on the transverse process and a lamina hook should be inserted to the transverse processes of the two upper and two lower vertebra in a direction that they will tighten (press) each other.

The lamina at the convex side of the curve should be decorticated. A rod of appropriate length gives a curve of 20° should be mounted to the hooks after appropriate nuts are placed on the rods. The nuts should be rotated in a direction to tighten the hooks. Both of the rods should be attached to each other from their upper and lower ends by transverse traction

devices. The fusion should be completed by grafts taken from the iliac bone.

If the curve is of the double thoracolumbar type first a retroperitoneal approach from the convex side of the lumbar curve is conducted so that the lumbar vertebrae will be exposed. The intervertebral discs which remain within the curve are resected including the terminal plaques and thus the curve gains flexibility. Bone grafts are inserted in to the intervertebral spaces. Staples are placed on the convex side surfaces of the vertebral corpus. Hooks (holders) with screws are mounted on the vertebra corpus through the holes in the middle of the staples in so that they will not pass the cortex on the other side. A rod of appropriate length is chosen and it is curved not to exceed 20° along its whole length. Pairs of telescopic nuts are mounted heads of the screws and the nuts are rotated so that the convex side of the curve will be compressed. Thus the lumbar curve fits the 20° curve of the rod. By rotating the rod around itself by 90° the curve of the rod on the frontal plane is converted to physiological normal lordosis. The rod is locked by pressing the nuts towards each other. The wound is closed. By using this method a flexible lumbar curve of 60° can be corrected completely in a single session.

When the lumbar curve is less than 20° in thoracic and lumbar double scoliosis the thoracic and lumbar curves can be corrected in a single session by a posterior approach (intervention). A rod of appropriate length should be bent in a manner to form the physiological thoracic kyphosis and lumbar lordosis.

In addition to the thoracic curve hooks open lamina hooks and closed lamina hooks should be inserted to the top and lower lips of the lumbar curve respectively. Preoperative halo

femoral traction was used for five paralytic severe curves. In these patients the traction was continued after the anterior surgical intervention and the traction was terminated only after the second operation was performed.

The mean operative period per patient was 160 minutes for the posterior approach and 225 minutes for the anterior approach. The mean intraoperative blood loss was 3 unites.

### RESULTS:

The postoperative radiological measurement of the dorsal curves was mean 10° (range 0°-40°) in frontal plane in the patients with idiopathic scoliosis. The mean correction rate was 79.4 %. In the idiopathic scoliosis patients the postoperative radiological measurement of the lumbar curves was mean 2.2° (range 0°-8°). The average correction rate in frontal plane was calculated as 93 % (Table-2).

The radiological measurement of the paralytic scoliosis patients post-operatively was mean 24° in frontal plane (range 0-42°) and the correction rate was 71.0 %.

In the congenital scoliosis patient group the postoperative radiological measurement was mean 21° in frontal plane (range 0°- 42°) and the correction rate was 63.7 %.

The mean rotation correction measurement was mean 10.3° (44 %) for the idiopathic

scoliosis group, 1.7° (4 %) for the congenital scoliosis group and 23.6° (33.4 %) for the paralytic scoliosis group. (According to RA-ANi)

### COMPLICATIONS:

A psoas abscess developed in one patient and superficial wound infection developed in two patients and they were managed by appropriate antibiotherapy. There was no postoperative neurological or instrumentation failure.

### DISCUSSION:

The correction and fusion of scoliosis deformities is performed by various methods. The oldest and most widely used instrumentation in the correction of scoliosis is the Harrington instrumentation (1949) and it has opened a new in spinal surgery. Although Harrington instrumentation is easy to apply it has the following disadvantages. It does not have sufficient effect on the rotational component of the deformity and it doesn't supply sufficient rotational stability and it requires external fixation (immobilization) postoperatively.

Luque's segmental spinal instrumentation has achieved stronger stabilization and early mobilization was possible in the post operative period but its application has resulted in extreme loss of correction.

**Table-2.** The radiologic values of the patients according to etiology of the scoliosis.

		Pre-Op.	Post-Op	Correction %
PARALYTHIC		83° (50°-135°)	24° (0-42°)	71
IDIO-PATHIC	Thoracal	52.1° (30°-98°)	10° (0-40°)	79.4
	Lumbar	36.2° (25°-44°)	22° (0-8°)	93
CONGENITAL		57.8° (38°-80°)	21° (0-42°)	63.7



Internal spinal instrumentation has gained new dimensions with the Cotrel-Dubousset method and it has been suggested that this method is effective to all components of the deformity. Besides external support is not required<sup>(1)</sup> but this method lacks the approach to achieve anterior spinal correction and fusion.

The Alici spinal instruments provide all the advantages of the CD instruments and possess the anterior spinal instruments required for the correction of lumbar curves up to 60°.

By converting lateral curves up to 20° physiological lumbar lordosis the application of anterior spinal instruments in lumbar curves is superior to the anterior instruments of the Dwyer and Zielke methods.

The application of Alici spinal instruments to idiopathic scoliosis cases has achieved an average of 79.5 % correction. This correction rate was 71.0 % for the paralytic and 63 % for the congenital scoliosis groups.

The higher rate of success in the correction of idiopathic scoliosis curves in comparison to the paralytic scoliosis was due to the higher mean age value (17 years) and to a higher curve degree (mean 83°, range 50°-135°) in the latter group. The correction rate obtained for the congenital scoliosis curves was 63.7 % and was due to the loosening or resection of the congenital vertebra by anterior approach.

The results that we have obtained appear to be more successful than many results reported in the literature<sup>(5,7,8)</sup>. Although the most important factor is the application of the anterior spinal instrument together with the

posterior spinal instrument, especially in the idiopathic scoliosis patient group an average age of 13.5 and an average curving of 52.4 degrees have played a substantial role.

#### REFERENCES:

1. Cotrel Y. Dubousset J. New universal instrumentation in spinal surgery. *Clin Orthop* 1988; 227: 10-23.
2. Hennemann S. Zielke K. 1st die Behandlung der kombinierten scoliose durch operationen von ventralen and dorsalen zungng gcrechtfertigt? Presented at the Orthopaedic Congress. Basel, 1979.
3. Korovessis P. Combined VDS and Harrington instrumentation for treatment of idiopathic double major curve. *Spine* 1987; 12: 3.
4. Micheli LJ, Riseborough EJ, Hall JE. Scoliosis in the adult. *Orthop Rev* 1977; 6: 27.
5. Mielke C.H. Surgical treatment of adolescent idiopathic scoliosis. *J Bone Joint Surg* 1989; 71-A: 8.
6. O'Brien JP, Dwyer AP, Hodgson AR. Paralytic pelvic obliquity: Its prognosis and management and the development of a technique for full correction of the deformity. *J Bone Joint Surg* 1975; 57-A: 626.
7. Van Dam BE. Adult idiopathic scoliosis treated by posterior spinal fusion and Harrington instrumentation. *Spine* 1987; 12: 1.
8. Winter RB. Adult idiopathic scoliosis treated with Luque or Harrington rods and sublaminar wiring. *J Bone Joint Surg* 1989; 71-A: 9.
9. Winter RB: Combined Dwyer and Harrington instrumentation and fusion in the treatment of the selected patients with painful adult idiopathic scoliosis. *Spine* 1978; 3 : 135.

