



VASCULAR INJURY USING THE CERVICAL SPINE TRANSARTICULAR SCREW FIXATION

SERVİKAL OMURGA TRANSARTİKÜLER VİDA FİKSASYONU SIRASINDA OLUŞAN DAMAR YARALANMALARI

Kadir KOTIL*, Neslihan SUTPİDELER **

SUMMARY:

Object: Transarticular C1-2 fixation is a surgical alternative in the treatment of atlantoaxial instability. To clarify the present incidence and management of iatrogenic vertebral artery injury (VAI) during cervical spine surgery. The majority of spine surgeons prefer to perform posterior fixation for C1-2 instability. Our hypotheses are that posterior transarticular screw fixation is enough for stabilization and it may result in vascular injury. Vertebral artery injury during posterior C1-2 transarticular screw fixation occurs in approximately 3 % of patients and may remain asymptomatic or result in arteriovenous fistulae, occlusion, narrowing, or dissection of the vertebral artery, and lead to transient ischemic attacks, stroke, or death

Method: During a period of 6 years (2003-2009), transarticular C1/2 fixation was performed in 20 patients. All were followed-up for 10–35 months (average 24.1 months) and were included in this retrospective study. The average age was 49.2 years (range 12–75

years). Atlantoaxial fusion was required in 9 (45 %) patients for an acute injury to the upper cervical spine, in 5 (25 %) patients with rheumatoid arthritis for atlantoaxial vertical instability, in 1 (5 %) patient for malunion of the old fractured dens, and in 5 (25 %) patients for os odontoideum.. Retrospectively, we evaluated age; gender; diagnosis; preoperative neurological status; technique of surgery; operative time; intraoperative blood loss; interval of X-ray exposure; placement, direction and length of the screws used; relation between vertebral artery and the screws; postoperative neurological outcome; vascular and other postoperative complications; follow-up time and fusion time. The post-operative condition was subjectively evaluated by patients. The relation between vertebral artery (VA) and the screws was detected by postoperative computed tomography (CT). Stability of the temporary fixation was evaluated on radiographs taken at 3, 12 weeks and 6 and 24 months after the surgery. Monitoring of postoperative

(*) M.D., Assoc. Prof., Istanbul Educational and Research Hospital. Department of Neurosurgery*, İstanbul.

(**) M.D., Istanbul Educational and Research Hospital. Department of Neurosurgery*, İstanbul.

complications was focused on vertebral artery injury, delayed healing of the wound, breaking or loosening of screws and development of instability.

Results: Operative time was 35 to 155 min, (average 83 min). Intraoperative blood loss ranged from 80 to 220 ml (average 155 ml). A total of 40 transarticular screws were inserted into the C1-2, screw lengths ranged from 45 to 50 mm (average, 47 mm). In 4 cases the screws were combined another vertebral segment such as C0, C1 and C3. In this series, neither vertebral artery injury nor spinal cord injury was experienced clinically. In our series the risk of vertebral artery injury was 0 %. The risk of minor breach of vertebral foramen was 10 %. The mortality rate was 0 %. The fusion was

observed in all cases (100 %). Only 2 (10 %) screws protruded into the transverse foramen. C1–C2 stability was achieved in all patients. We observed postoperative dermal cerebrospinal fluid fistules in 2 (10 %) patients.

Conclusion: Bilateral transarticular posterior screws have excellent clinical results without VA injury. The risk of catastrophic vascular or neural injury is small and can be minimized by assessing the position of the foramen transversaria on preoperative computed tomographic scans and by using intraoperative fluoroscopy.

Key words: *Transarticular, screw, upper cervical, vertebral artery, injury*

Level of evidence: *Retrospective clinical study, Level III*

ÖZET:

Amaç: Transartiküler C1-2 fiksasyonu atlantoaksiyel instabilite tedavisinde bir alternatiftir. Amacımız servikal omurga cerrahisi sırasında iatrojenik vertebral arter hasarı (IVAH) riskinin insidansı ve bu durumun yönetimini tartışmaktır.

Gereçler ve Yöntem: Omurga cerrahlarının çoğu C1-2 instabilitesi için posterior fiksasyonu tercih ederler. Biz, posterior transartiküler vida fiksasyonunun stabilizasyon için yeterli olduğunu ve bu yöntemin vasküler hasara yol açabileceğini öngörerek bu çalışmayı yaptık. Posterior transartiküler vida ile fiksasyon sırasında vakaların yaklaşık % 3'ünde vertebral arter hasarı olabilir ve asemptomatik de kalabilmekle birlikte arteriovenöz fistüller, vertebral arter de oklüzyon, darlık veya disseksiyona yol açarak geçici iskemik ataklar, inme ve hatta ölümlerle sonuçlanabilir. Altı yıllık bir dönemde (2003-2009), 20 hastada transartiküler C1-2 fiksasyonu uygulandı. Hastaların tümü 10-35 ay (ortalama 24.1 ay) takip edildi ve bu retrospektif çalışmaya dahil edildi. Ortalama yaş 49.2 (12-75 yaş) idi. Hastaların 9'unda (% 45) atlantoaksiyel füzyona, üst servikal omurganın akut hasarı, 5 hastada (% 25) romatoid artrit nedeniyle gelişen atlantoaksiyel vertikal instabilite, 5 hastada (% 25) os odontoideum ve 1 hastada (% 5) eski dens kırığının kötü kaynaması nedeniyle gerek görüldü. Retrospektif olarak yaş; cinsiyet; tanı; preoperatif nörolojik durum; cerrahi teknik; operasyon süresi; intraoperatif kan kaybı; görüntüleme aralıkları; yerleştirilen vidaların yönelim, yerleşim ve uzunlukları; vertebral arter ve yerleştirilen vidalar arasındaki ilişki; postoperatif nörolojik sonuç; vasküler ve diğer postoperatif nörolojik

komplikasyonlar; takip süresi ve füzyon için geçen zaman tespit edildi. Postoperatif durum hastalar tarafından subjektif olarak belirlendi. Vertebral arter (VA) ve vidalar arasındaki ilişki postoperatif bilgisayarlı tomografi (BT) ile incelendi. Geçici fiksasyonun stabilitesi cerrahi sonrası 3 ve 12. haftalar ile 6 ve 24. Aylarda çekilen direk grafipler ile değerlendirildi. Postoperatif komplikasyon araştırması vertebral arter hasarı, yaranın geç iyileşmesi, vidaların kırılması ya da gevşemesi ve instabilite gelişmesine yönelikti.

Sonuçlar: Operasyon süresi 35 ile 155 dakika arasında değişmekteydi (ortalama 83 dakika). İntraoperatif kan kaybı 80 ile 220 ml arasındaydı (ortalama 155 ml). C1-2'ye toplam 40 transartiküler vida yerleştirilmişti, vida uzunlukları 45 ile 50 mm arasındaydı (ortalama 47 mm). Dört vakada vidalar C0, C1 ve C3 gibi başka segmentlerle kombine edilmişti. Bu seride klinik olarak vertebral arter hasarı ya da omurilik hasarı izlenmedi. Vertebral arter hasarı oranı % 0 idi. Vertebral foramenin minör etkilenme oranı % 10 idi. Moratlite oranı % 0 idi. Tüm vakalarda füzyon izlendi (% 100). Sadece 2 vida (% 10) transverse foramene uzanmaktaydı. C1-2 stabilitesi tüm hastalarda sağlandı. Hastaların 2'sinde (% 10) postoperatif dermal serebrospinal sıvı fistülü gözlemlendi.

Sonuç: Bilateral transartiküler vidaların VA hasarı olmaksızın mükemmel sonuçları vardır. Katastrofik vasküler ya da nöral hasar riski küçüktür ve transverse foramenlerin pozisyonu preoperatif bilgisayarlı tomografide incelenerek ve intraoperatif fluoroskopi kullanılarak en aza indirilebilir.

Anahtar kelimeler: Transartiküler, vida, üst servikal, vertebral arter, yaralanma

Kanıt Düzeyi: Retrospektif klinik çalışma, Düzey III

INTRODUCTION:

Previous methods included posterior wiring to immobilize C1-2, but suboptimal arthrodesis rates, the need for postoperative Halo immobilization, and incompatibility with cases requiring decompressive laminectomy led to subsequent introduction of C1-2 transarticular screw (TAS) fixation by Magerl and Seeman⁽¹⁶⁾. Transarticular screws gained widespread popularity for their superior biomechanical immobilization of C1-2, especially when used in combination with posterior wiring. As a result, improved fusion rates were observed even without the use of adjunctive Halo immobilization^(2,5,9). The success of the Magerl technique lies in the central screw positioning which provides better control of stability than the previously mentioned techniques which rely only on peripheral fixation.^(5, 10) The patients do not require immobilization in a Halo vest postoperatively, and biomechanical studies have shown this construct to be superior to Halifax, Gallie, and Brooks fixation^(5,25). Transarticular posterior screw technique is ten times stronger than other techniques⁽²⁵⁾. As Guiot and Stillerman had reported, excellent results have also been obtained with the use of Magerl screws without posterior bone grafting or cerclage wiring. But, vascular injury is the most important possible complication, vertebral artery (VA) injury may be caused by this technique. The given risk of this complication is different many series^(8,21,24,26). Vertebral artery injury during posterior C1-2 transarticular screw fixation occurs in approximately 3 % of patients and may remain asymptomatic or result in arteriovenous fistulae, occlusion, narrowing, or dissection of the vertebral artery, and lead to transient ischemic attacks, stroke, or death⁽²¹⁾ In clinical study we described our results for transarticular screw fixation, to clarify the

present incidence and management of iatrogenic vertebral artery injury (VAI) during cervical spine surgery.

MATERIALS AND METHOD:

From June 2003 to January 2009, 20 patients underwent posterior C1–C2 transarticular fixation and fusion (both autograft and allograft). Each surgical procedure was performed by the same senior spine surgeon (KK). The data collected included age; gender; diagnosis; preoperative neurological status; technique of surgery; operative time; intraoperative blood loss; interval of X-ray exposure; placement, direction and length of the screws used; relation between vertebral artery and the screws; postoperative neurological outcome; vascular and other postoperative complications; follow-up time and fusion time. Our indications for surgery were the presence of a neurological deficit, C1–C2 instability, or severe C1–C2 kyphotic deformity. Atlantoaxial instability was diagnosed before surgery by radiologic investigations. If the displacement was difficult to reduce, even with strong skull traction under general anesthesia, it was considered as irreducible atlantoaxial dislocation. These cases were treated by occipitocervical fixation with transarticular screw and fusion. There are two kinds of malpositions of the transarticular screws⁽²¹⁾:

- 1- Major breach: Encroachment of the vertebral artery canal of more than 25 %, like medial pedicle perforation with dural laceration and risk of radicular or medullar compression or injury,
- 2- Minor breach: Lateral or ventral perforation of the vertebral body, slight influence of the lateral recess without dural contact or narrowing of the vertebral artery canal less than 25 % of its diameter.

All patients were assessed clinically for neurologic recovery by Odom's criteria ⁽¹⁹⁾.

We took dynamic flexion and extension views and lateral cervical standing roentgenograms before surgery, after surgery immediately, at 3, 12, and 24 months, and annually thereafter. Vertebral artery doppler ultrasonography was performed for all patients, because dominant VA should be detected before the surgery. All patients underwent thin-slice CT scans from the occipital condyles through C3 with sagittal reconstruction through the C1-2 facet on both side to look for the presence of a vertebral artery in the intended path of screw. Also, risk of VA injury can be reduced using CT scans reconstructed along the planned trajectory of the screw. Vertebral

artery CT reconstruction with contrast enhancement was performed immediately after operation to verify the screw position.

- Surgical Technique of Transarticular C1–C2 Screw Fixation:

The patient is carefully placed in sitting position after intubation. A midline incision is made and the subinion, laminae of C1 to C4 were exposed. The screw entry point should be at the lower edge of the conjunction of C2 lamina and its lateral mass. A 2.0-mm hand bit was drilled through the isthmus, exiting from the articular mass of C2 at the posterior one third of its superior articular surface. The C2 minihemilaminotomy can be performed to achieve ideal screw position (Figure-1). Then

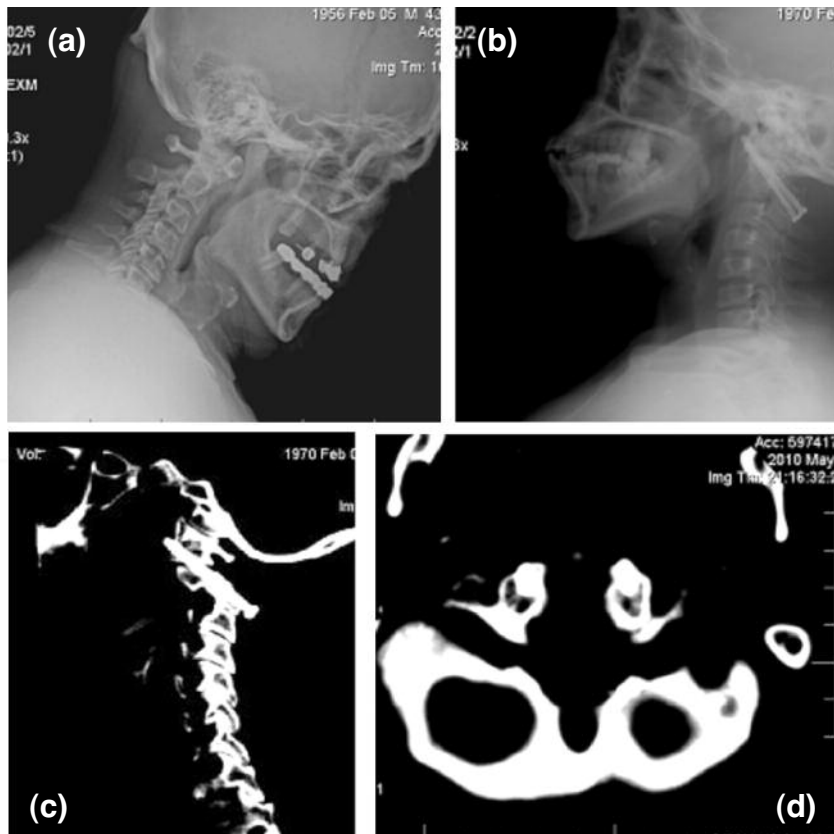


Figure-1. A 44-year-old women had atlantoaxial instability with os odontoideum. (a) Lateral radiograph showed os odontoideum and atlas anterior displacement. (b) Sagittal CT showed, TAS fixation and cancellous grafts could be recognized on radiograph 1 year after operation. (c) Sagittal CT showed transarticular screw and normal anatomic curvature (d) Axial CT showed bilatereal screws into the lateral mass of C1. E, Bilateral transarticular screws are showed by Coronal cervical CT.

the entry point is drilled into C2 posterior pedicle entry point. Ideal entry point is challenging. Our entry point is at the superior one-fourth of the C2 lateral mass. Mean trajectory angles of the sagittal plane was 55.3° (46-63 $^\circ$).

Two full-threaded cortical noncannulated titanium screws are inserted across the C1–C2 joints. Fusion is achieved using different techniques including autograft use. The fusion is determined by 2D-CT (Figure-2).

RESULTS:

This series includes 8 male and 12 female patients whose average age was 49.2 years (range 12–75 years). The pathology and clinical data is demonstrated in Table-1. A total of 40 transarticular screws were placed. No major vascular complication was observed related to VA. Minor breach was detected in only 2 (10 %) screws. 3D CT demonstrated that all the screws were placed satisfactorily except in 2 (10 %) cases who were first in the learning curve period. 2 (10 %) cases (cases 2 and 9) had medial pedicle wall penetration (Figure-3). There were no symptoms in these patients. All patients attained strong fixation, and no screw

failure occurred. Fusion was observed in all cases (100 %). All cases were checked for any instability at the postoperative period (Figures-4.a and b). The average follow-up was of 47 months (range, 24–76 months). There was no screw fracture, loosening, or backout. In the 20 cases with preoperative neurologic symptoms, the outcome was excellent in 11 (55 %), same or good in 8 (40 %) and poor in 1 (5 %) according to Odom's criteria.

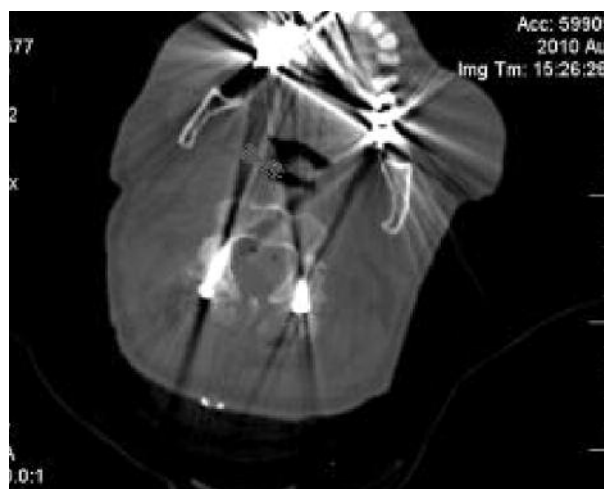

Figure-3. An axial CT scan showed minor breach of the right pedicle screw .

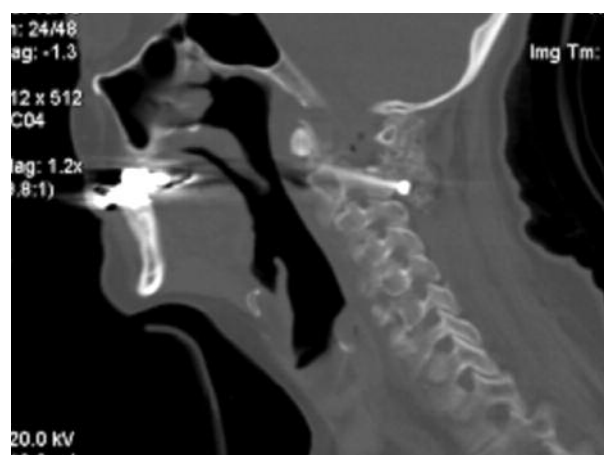
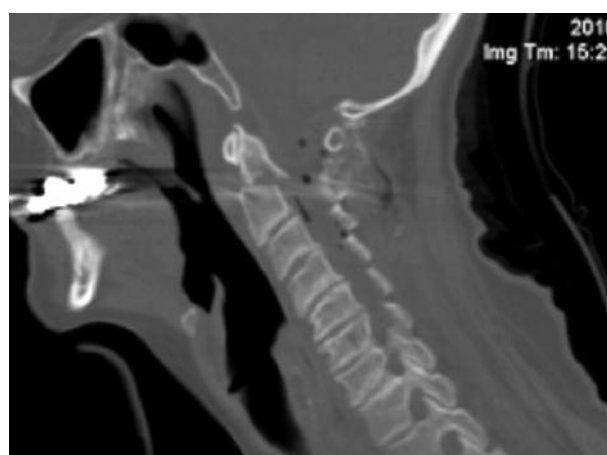

Figure-2. (a) 64-year-old woman had atlantoaxial instability with type 2 dens fracture (with rupture of the atlas ligament). **(b)** Sagittal cervical CT showed TAS fixation and cancellous grafts could be recognized 1 year after operation.

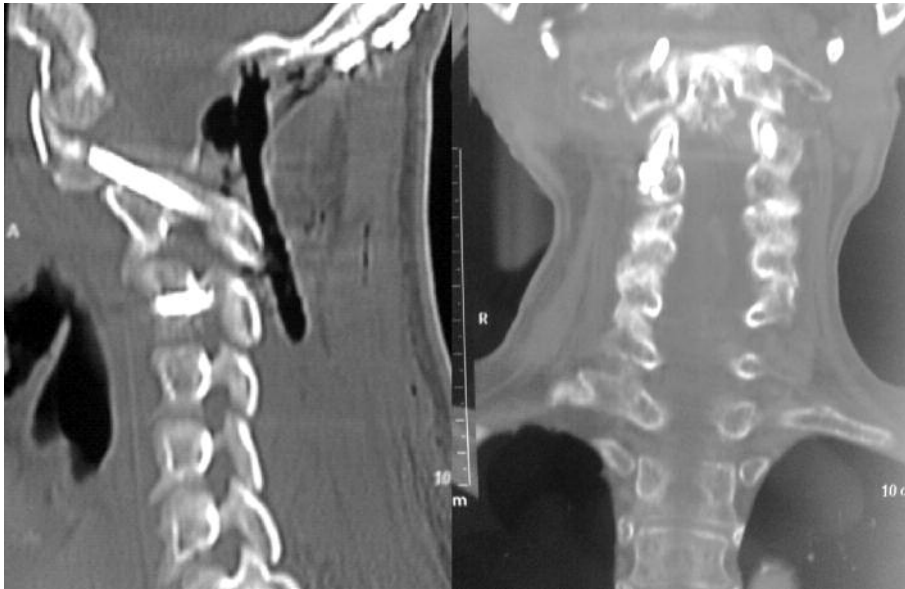


Figure-4. (a) A sagittal CT scan showed optimal transarticular fixation of the C1-C2 complex. **(b)** Coronal CT scan showed optimal transarticular fixation of the C1-C2 complex .

Table - 1. Clinical findings of the patients.

Age/sex	Etiology	Surgery	Complication/ VA breach	Fusion Time (mo)	Postop Neurologic Status.	Follow-up (mo)
1-44/M	UCT	TA	NO	4	Same-good	12
2-29/M	UCT	TA	NO/minor	5.5	Same-good	13
3-33/M	UCT	TA	NO	6	improved	23
4-39/F	OO	TA	NO	4.5	improved	21
5-65/M	OO	TA+OC	NO	6	improved	16
6-55/M	RA	TA+OC	CSF fistule	6	improved	27
7-73/M	UCT	TA	SWI	5.4	improved	15
8-75/F	OO	TA	NO	6	improved	19
9-12/M	UCT	TA+OC	NO/minor	10	improved	17
10-77/M	RA	TA	NO	5.3	Same-good	26
11-66/F	UCT	TA	NO	6.4	Same-good	32
12-54/M	RA	TA+OC	NO	8	Same-good	35
13-54/F	UCT	TA	NO	7	Same-good	29
14-15/M	RA	TA+OC	NO	7.5	Poor	17
15-44/F	UCT	TA	SWI.	6	improved	24
16-70/M	RA	TA	NO	7.8	improved	18
17-45/M	UCT	TA	NO	6	Same-good	31
18-36/F	OO	TA	NO	5.5	improved	19
19-23/M	OF	TA+OC	CSF fistul	9	Same-good	21
20-49/M	OO	TA	NO	4	Improved	23

SCE: superficial infection, UCT: upper cervical trauma, RA: rheumatoid trauma, OO: Os odontoideum, OF: old fracture malunion, SWI: Superficial wound infection, CSF: cerebrospinal fluid, TA: Transarticular, OC: Occipitocervical.

- Other complications of screw placement:

Fusion failure didn't occur any patient, intraoperative dural tear was encountered in one patient (5 %), two patients were reported to have a dermal CSF fistule.

DISCUSSION:

Upper cervical spine instability can be corrected by a wide variety of surgical techniques. Recently, various techniques for screw fixation of C-1 and C-2 have been developed to stabilize the atlantoaxial complex ⁽¹⁶⁾. It is well known that the atlantoaxial segment is the most mobile region of the vertebral column. Approximately 50 % of the rotation of the cervical spine occurs at the C1-C2 joint ^(1,7). C1-C2 instability may result from various pathologic conditions such as trauma, congenital anomalies, skeletal dysplasia, Down syndrome, rheumatoid arthritis, osteoarthritis, infections or tumors ⁽⁹⁾.

Mixter and Osgood first described securing the posterior elements of the atlas and axis with heavy silk thread in a case of traumatic instability ⁽¹⁹⁾. Since that time, other posterior fusion techniques have been advocated, such as the Gallie fusion ⁽⁷⁾, the Brooks-Jenkins fusion ⁽¹⁾, the interlaminar clamp ⁽¹²⁾ and Sonntag's modified Gallie fusion ⁽²⁾. Unfortunately studies have shown non-union rates as high as 80% even with the use of halo vest. These outcomes led to the development of new techniques for the treatment of C1-C2 instability. In 1987, Magerl and Seemann introduced an original technique for posterior transarticular screw fixation of the C1-C2 facets which provided immediate rigid multidirectional stability with successful fusion rates from 95 to 100 % ⁽²⁴⁾. The technique has increasingly been used to treat patients with significant rotatory instability of the atlantoaxial complex. Clinical and cadaver studies have shown that C1-C2 transarticular

screw fixation provides significantly greater biomechanical stability in axial rotation, lateral bending, flexion and extension than conventional posterior fusion ^(2,9,16,24). In addition, this method obviates the need for rigid external bracing after surgery as the biomechanical strength of the fixated atlantoaxial complex is excellent ⁽⁵⁾.

Despite its success, there are complications associated with the Magerl technique ^(6,8,26). It is a technically demanding procedure and poses risks of malpositioning of screws, long-term implant failure, dural tear, neurological deficit (including suboccipital paresthesia or hypoglossal paresis) and vertebral artery injuries, ranging from occult arteriovenous fistula to frank arterial compromise causing brainstem infarction and death ^(4,8,15, 23-24,26). The risk of vertebral artery injury ranges from 0 to 8.2 % ^(4,14). The risk of potential injury to vertebral arteries, the spinal cord, the underlying dura and the adjacent exiting nerve roots is prominent because of the close proximity of the screw path to these important structures. Additionally, approximately up to 22% of the patients in need of C1-C2 fusion may not be suitable for transarticular screw fixation due to certain anatomical variations ^(13-15,17,20).

The course of the vertebral artery and the inconstant size and location of the transverse foramina in the lateral masses of both the atlas and axis place the VA at risk during drilling or screw placement. The C1 and C2 are atypical vertebrae and have unusual shape and architecture and a complex and important vertebral artery relationship ^(14,22). The risk of vertebral artery injury increases in patients with anomalies in the course of the artery in the C2 vertebra. Superior facet of the C2 vertebra differs from the facets of all other vertebrae in two important characters, which

maket his region prone to vertebral artery injury during screw fixation. First is that the superior facet of C2 is present in proximity to the body when compared to other facets which are located in proximity to the lamina. Second, the vertebral artery foramen is partially or completely in the inferior of the superior facet of C2, while in the other cervical vertebrae, vertebral artery foramen is located entirely in relationship with the transverse process. The course of the vertebral artery in relationship to the inferior of the superior articular facet of the C2 makes it susceptible to injury during transarticular and interarticular screw implantation techniques⁽²²⁾. Madawi, et al. found large variations in the dimensions and symmetry of 50 dry C2 vertebrae⁽¹⁵⁾. The transverse foramen of axis is an angulated canal with inferior and lateral openings that cause the artery to deviate 45° laterally before its ascent to enter the transverse foramen of the atlas. It may enlarge at the expense of the surrounding structures, affecting the diameter of the pedicle and the internal height of the lateral mass. Thus the importance of preoperative radiological imaging, including fine-slice axial computerized tomography scans of the C1-C2 complex, in a patient in whom transarticular screw fixation of the atlantoaxial complex is planned to assess not only the anatomy of the vertebral artery but also the physical dimensions of the C2 pedicle has been reported⁽¹²⁾.

Venous plexuses cover the entire course of the artery, making it identifiable during surgery . Venous plexuses are found to be largest in the region lateral to the C1-C2 joint. The occupancy of the artery in the vertebral artery groove is found to be 34 to 100 % (79 %) in C2 and 42 to 71 % (57 %) in C1⁽²²⁾. As vertebral artery does not fill the osseous canal completely, a screw taht crosses the canal does not necessarily injure the artery.

Injuries of the vertebral artery and spinal cord are considered to be highly correlated with screw malpositioning. Adherence to the operation guidelines along with detailed preoperative investigations to determine the exact anatomical properties of the patient would prevent malpositioning. But there exists no general trajectory line for screw placement and the decision of the number of screws to be placed is patient based.

The incidence of VAI during cervical spine surgery from this survey was similar to or slightly less than that in the literature. Tamponade was effective in many cases, but prompt consultation with an endovascular team is recommended if the bleeding is uncontrollable. Preoperative careful evaluation of the vertebral artery seems to be most important to prevent iatrogenic VAI and to avoid postoperative neurologic sequelae^(3,11,18).

In conclusion, we believed that bilateral transarticular posterior screws have excellent clinical results without VA injury. The risk of catastrophic vascular or neural injury is small and can be minimized by assessing the position of the foramen transversaria on preoperative computed tomographic scans and by using intraoperative fluoroscopy

REFERENCES:

1. Brooks AL, Jenkins EB. Atlanto-axial arthrodesis by the wedge compression method. *J Bone Joint Surg* 1978; 60-A: 279-284.
2. Dickman CA, VK. Posterior C1-C2 transarticular screw fixation for atlantoaxial arthrodesis. *Neurosurgery* 1998; 43: 275-281.
3. Dull ST, Toselli RM. Preoperative oblique axial computed tomographic imaging for C1-2 transarticular screw fixaiton. Technical note. *Neurosurg* 1995; 37: 150.

4. Gluf WM, Schmidt MH, Apfelbaum RI. Atlantoaxial transarticular screw fixation: a review of surgical indications, fusion rate, complications, and lessons learned in 191 adult patients. *J Neurosurg Spine* 2005; 2(2): 155-163.
5. Grob D, Crisco JJ III, Panjabi MM, Wang P, Dvorak J. Biomechanical evaluation of four different posterior atlantoaxial fixation techniques. *Spine* 1992; 17: 480-490.
6. Farey ID, Nadkarni S, Smith N. Modified Gallie technique versus transarticular screw fixation in C1-C2 fusion. *Clin Orthop* 1995; 359: 126-135
7. Gallie WE. Fractures and dislocations of the cervical spine. *Am J Surg* 1939; 46: 495-499.
8. Grob D, Jeanneret B, Aebi M, Markwalder T-M. Atlantoaxial fusion with transarticular screw fixation. *J Bone Joint Surg* 1991; 73-B: 972-976.
9. Haid RW Jr, Subach BR, McLaughlin MR, Rodts GE Jr, Wahlig JB Jr. C1-2 transarticular screw fixation for atlantoaxial instability: a 6-year experience. *Neurosurgery* 2001; 49: 65-70.
10. Hanson PB, Pasquale MX, Sharkey NA, Rauschnig W. Anatomic and biomechanical assessment of transarticular screw fixation for atlantoaxial instability. *Spine* 1991; 16: 1141-1145.
11. Hedequist D, Proctor M. Screw fixation to C2 in children. A case series and technical report. *J Pediatr Orthop* 2009; 29: 21-25.
12. Holness RO, Huestis WS, Howes WJ, Langille RA. Posterior stabilization with an interlaminar clamp in cervical injuries: technical note and review of the long term experience with the method. *Neurosurg* 1984; 13: 318-322.
13. Jun T. Computer-assisted screw insertion for cervical disorders in rheumatoid arthritis. *Eur Spine J* 2007; 14: 485-410
14. Madawi AA, Casey AT, Solanki GA, Tuite G, Veres R, Crockard HA. Radiological and anatomical evaluation of the atlantoaxial transarticular screw fixation technique. *J Neurosurg* 1997; 86(6): 961-968.
15. Madawi AA, Solanki G, Casey AT, Crockard HA. Variation of the groove in the axis vertebra for the vertebral artery: implications for instrumentation. *J Bone Joint Surg* 197; 79-B: 820-823.
16. Magerl F, Seeman PS. Stable posterior fusion of the atlas and axis by transarticular screw fixation, in Kehr P, Weidner A: Cervical spine I. Vienna: Springer-Verlag, 1987, pp: 322-327.
17. Mandel IM, Kambach BJ, Petersilge CA, Johnstone B, Yoo JU. Morphologic considerations of C2 isthmus dimensions for the placement of transarticular screws. *Spine* 2000; 25: 1542-1547.
18. Neo M, Fujibayashi S, Miyata M, Takemoto M, Nakamura T. Vertebral artery injury during cervical spine surgery: a survey of more than 5600 operations. *Spine* 2008; 33 (7): 779-785.
19. Odom GL, Finney W, Woodhall B. Cervical disk lesions. without the explanation of the criteria. *J Am Med Assoc* 1958; 166 (1): 23-28.
20. Paramore CG, Dickman CA, Sonntag VK. The anatomic suitability of the C1-C2 complex for transarticular screw fixation. *J Neurosurg* 1996; 85: 221-224.
21. Prabhu VC, France JC, Voelker JL, Zoarski GH. Vertebral artery pseudoaneurysm complicating posterior C1-2 transarticular screw fixation: case report. *Surg Neurol* 2001; 55 (1): 29-33.
22. Sen MK, Steffen T, Beckman L, Tsantrizos A, Reindl R, Aebi M. Atlantoaxial fusion using anterior transarticular screw fixation of C1-C2: technical innovation and biomechanical study. *Eur Spine J* 2005; 14(5): 512-518.
23. Sherk HH, Snyder B. Posterior fusions of the upper cervical spine: indications, techniques, and prognosis. *Orthop Clin North Am* 1978; 9: 1091-1099.
24. Stillerman CB, Wilson JA. Atlanto-axial stabilization with posterior transarticular screw fixation: technical description and report of 22 cases. *Neurosurgery* 1993; 32: 948-955.
25. Wilke HJ, Fischer K, Kugler A, Magerl F, Claes L, Worsdorfer O. In vitro investigations of internal fixation systems of the upper cervical spine, II: stability of posterior atlanto-axial fixation techniques. *Eur Spine J* 1992; 1: 191-199.
26. Wright NM, Laurysen C. Vertebral artery injury in C1-2 transarticular screw fixation: results of a survey of the AANS/CNS section on disorders of the spine and peripheral nerves. *J Neurosurg* 1998; 88: 634-640.