



SELECTIVE THORACIC FUSION IN ADOLESCENT IDIOPATHIC SCOLIOSIS WITH LENKE TYPE 1C, 3C OR KING TYPE 2 LUMBAR CURVES OF MORE THAN 50 DEGREES IN MAGNITUDE

50°'DEN FAZLA LOMBER EĞRİLİĞE SAHİP LENKE TİP 1C, 3C VEYA KING TİP 2 ADÖLESAN İDİOPATİK SKOLYOZDA SELEKTİF TORASİK FÜZYON

Çağatay ÖZTÜRK*, Meriç ENERCAN*, Sinan KAHRAMAN*
İbrahim ÖRNEK*, Azmi HAMZAOĞLU**

SUMMARY:

The operative goals of surgery in adolescent idiopathic scoliosis are to prevent progression while providing safe and optimal coronal correction, sagittal alignment, and axial derotation. The aim of this retrospective clinical study was to evaluate the outcome of selective thoracic fusion for adolescent idiopathic scoliosis in the presence of compensatory lumbar curve of more than 50 in terms of if the King's criteria are still valid or not.

Between the years of 1991 and 2000, 122 consecutive patients with major thoracic and compensatory lumbar AIS curves undergoing selective thoracic fusion were retrospectively identified from our surgical database. Twenty-nine of those patients were determined to have compensatory lumbar curves of more than 50 degrees in magnitude and included in the study.

All patients were female and the average age at the time of surgery was 16.5 years, range 13–19. The mean duration of radiographic follow-up was 12 years, range 7–16. Curve types according to the Lenke system were: 1C in 23 patients and 3C in 6 patients. The average preoperative main thoracic curve measured 65° (range 55°–90°) and decreased to 26° on side bending. The average preoperative compensatory lumbar curve measured 55° (50°–75°) and decreased to 13.2° on side bending. The per cent main thoracic curve operative correction was meanly 61 % and the per cent compensatory lumbar curve operative correction was meanly 50 %. There was no radiographic evidence of correction loss, implant loosening, dislodgement, low back pain complaint or fracture during the follow-up period. There were neither decompensation seen during

(*) M.D., Surgeon of Orthopaedics and Traumatology, Istanbul Spine Center, Florence Nightingale Hospital, Istanbul, TURKEY.

(**) Prof., M.D., Surgeon of Orthopaedics and Traumatology, Istanbul Spine Center, Florence Nightingale Hospital, Istanbul, TURKEY.

Corresponding author: Çağatay ÖZTÜRK, MD
Istanbul Spine Center, Florence Nightingale Hospital
Abide-I Hürriyet Caddesi No: 290, 34430, Şişli, Istanbul, TURKEY
Tel: +90 212 315 36 36
Fax: +90 212 234 86 89
e-mail: cgyztrk@yahoo.com

follow-up period nor re-operations applied in the patient group.

One simple principle different from King's criteria is that if the neutral vertebra and the stable vertebra is not the same vertebra and if the stable vertebra is within the lumbar curve, it is better to stop instrumentation and fusion distally at the neutral vertebra to obtain better spontaneous compensatory lumbar curve

correction even the CSVL does not touch neutral vertebra as it will be centered over the sacrum to achieve a balanced, stable spine after correction.

Key Words: *Idiopathic scoliosis, Lenke classification, posterior instrumentation, decompensation.*

Level of Evidence: *Retrospective clinical study, Level III*

ÖZET:

Adölesan idiopatik skolyozda cerrahi tedavinin amacı, aksiyel rotasyon, sagittal dizlimin sağlanması ve koronal planda eğriliğin düzeltilmesi ve düzeltilmiş pozisyonda korunması yanı sıra progresyonun da durdurulmasıdır. Bu retrospektif çalışmanın amacı King kriterlerine göre 50° üzeri lomber kompenzatuvar eğriliğe sahip ana torasik eğriliklerde seçici torasik füzyon sonuçlarının değerlendirilmesidir.

1991-2000 yılları arasında ardışık olarak 122 ana torasik eğriliğe ve lomber kompenzatuvar eğriliğe sahip adölesan idiopatik skolyoz vakası opere edilmiştir. Bunlardan 39'unda eğriliğin 50° üzerinde olduğu belirlenmiş ve bu çalışmaya dahil edilmiştir.

Tüm hastalar kız olup operasyon sırasındaki ortalama yaşın 16.5 (13-19) olduğu, hastaları 23'ünün Tip IC ve 6'sının Tip 3C olduğu belirlenmiştir. Ortalama ana torasik eğrilik 65° (55°-90°) olup, eğilme grafilerinde 26°'ye düştüğü, lomber kompenzatuvar

eğriliklerin ise preoperatif ortalama 55° (50°-75°) olup, eğilme grafilerinde ortalama 13.2°'ye düştüğü saptanmıştır. Postoperatif ana torasik eğriliklerde ortalama % 61 ve kompenzatuvar eğriliklerde ortalama % 50 korreksiyon elde edilmiştir. Son kontrolde korreksiyon kaybı, implant yetmezliği ve bel yakınması görülmemiştir. Hiçbir hastada reoperasyon gerektiren bir dekompanzasyon problemine rastlanmamıştır.

Bu çalışmanın verilerine göre King Sınıflamasında nötral ve stabil vertebranın aynı olmadığını akılda tutarak, stabil vertebranın lomber kompenzatuvar eğrilik içinde yer alması durumunda füzyon ve enstrümantasyonun nötral vertebrada sonlandırılmasının dekompanzasyonun önlenmesi açısından daha iyi sonuçlara sahip olduğu fikri elde edilmiştir.

Anahtar Kelimeler: İdiopatik skolyoz, Lenke sınıflaması, posterior enstrümantasyon, dekompanzasyon.

Kanıt Düzeyi: Retrospektif klinik çalışma, Düzey III.

INTRODUCTION:

The operative goals of surgery in adolescent idiopathic scoliosis are to prevent progression while providing safe and optimal coronal correction, sagittal alignment, and axial derotation. Certainly, fusing the smallest number of spinal segments possible while obtaining those goals is also desirable to maximize motion segments both above and below the fused spinal segments^(3,7).

For adolescent idiopathic scoliosis (AIS), selective thoracic fusion in the presence of a compensatory lumbar curve remains controversial. Ideally, after selective thoracic fusion, the unfused lumbar curve will spontaneously accommodate to the corrected position of the thoracic curve. It was assumed a mechanism whereby improvement of the lumbar curve occurred through counterbalancing the surgical correction of the thoracic curve. The correction of the lumbar curve is said to echo the correction obtained for the thoracic curve⁽⁹⁾. Although selective fusion has the advantage of preserving lumbar motion segments, it may in certain cases result in postoperative coronal decompensation^(1,6,14,18,21).

Selective thoracic fusion was first described by Von Lackum in 1949⁽²²⁾. Later, King *et al*⁽¹²⁾ recommended that patients with Type II (major thoracic/compensatory lumbar) curves be treated with selective thoracic fusion. They reported that if the neutral and the stable vertebra were same, one could safely fuse to this level. If the neutral and stable vertebra did not correspond, the fusion to stable vertebra would give the most reliable and satisfactory long term results. Subsequent studies that focused on the treatment of this Type II curves have had varying conclusions about fusing the lumbar curve. Some agree with King's guidelines, whereas others have put forth limitations of curve magnitude, stating that a

lumbar curve greater than 40° to 45° should be fused regardless of flexibility^(11,17-18,21).

After the introduction of 3rd generation spinal implants (C-D from 1985); severe decompensation after selective thoracic fusion was increased to be seen and in 2001, Lenke *et al*⁽¹¹⁾ described a new surgical classification system for AIS that specifically quantified the structural aspects of regional scoliosis curves based on relative curve magnitude, flexibility and position. According to this system curves are classified according to: 1) curve pattern; 2) lumbar apical vertebral translation; and 3) sagittal alignment. In general, for curves in which the lumbar apical vertebral body is incompletely translated from the midline (lumbar modifier A&B) selective thoracic fusion is recommended. The more challenging curves in which the lumbar apical vertebra is totally translated from the midline (lumbar modifier C) may also be treated with selective thoracic fusion, but are considered to be at greatest potential for subsequent decompensation.

The aim of this retrospective clinical study was to evaluate the outcome of selective thoracic fusion for adolescent idiopathic scoliosis in the presence of compensatory lumbar curve of more than 50 degrees (apical vertebra totally translated from midline = lumbar modifier C) in terms of if the King's criteria are still valid or not.

MATERIALS AND METHODS:

Between the years of 1991 and 2000, 122 consecutive patients with major thoracic and compensatory lumbar AIS curves undergoing selective thoracic fusion were retrospectively identified from our surgical database. Twenty-nine of those patients were determined to have compensatory lumbar curves of more than 50 degrees in magnitude and included in the study.

Preoperative long-cassette standing upright anteroposterior (AP) and lateral radiographs, as well as right and left bending coronal radiographs, were independently reviewed. The Cobb angles of both thoracic and compensatory lumbar curves and translation of the lumbar apical vertebra from midline were measured pre and postoperatively. Translation of the lumbar apical vertebra was strictly defined for each patient by the relation of the center sacral vertical line (CSVL) to the apex of the lumbar spine on the preoperative standing long-cassette radiograph. Curve patterns were given the lumbar modifier C if the CSVL passed completely medial to and did not touch the lumbar apical vertebra. The stable vertebra was defined as the most proximal lumbar or lower thoracic vertebra most nearly bisected by the CSVL.

Selective thoracic fusion was performed by the senior surgeon (A.H.) at a single institution with modern segmental spinal instrumentation. The indication for surgery in all patients was a combination of thoracic curve magnitude greater than 50°, global imbalance, and/or poor cosmeses. Procedures involved posterior approach with the distal fusion level ending at L1 or above in all cases. All procedures were performed in a similar manner with selective distraction and compression forces and *in situ* rod bending correction maneuvers without derotation to avoid overcorrection.

Standing long cassette AP and lateral radiographs from preoperative, immediate postoperative and most recent follow-up were evaluated to determine changes in radiographic characteristics over time like spontaneous correction and decompensation in lumbar curves.

RESULTS:

All patients were female and the average age at the time of surgery was 16.5 years, range

13–19. The mean duration of radiographic follow-up was 12 years, range 7–16. Curve types according to the Lenke system were: 1C in 23 patients and 3C in 6 patients. The average preoperative main thoracic curve measured 65° (range 55–90°) and decreased to 26° on side bending (flexibility ratio: 60 %). The average preoperative compensatory lumbar curve measured 55° (50–75°) and decreased to 13.2° on side bending (flexibility ratio: 76 %).

Preoperative apical vertebral translation for the main thoracic curve averaged 58 mm (30–88 mm) and for the compensatory lumbar curve was 31 mm (19–47). In no patient were the compensatory lumbar curve magnitude, apical vertebral translation and apical vertebral rotation greater than that of the main thoracic curve.

All patients underwent posterior selective thoracic fusion procedure. The per cent main thoracic curve operative correction was meanly 61 % and the per cent compensatory lumbar curve operative correction was meanly 50 %. The apical lumbar vertebral displacement improved to 1.8 cm from 3.1 cm at the latest follow-up.

The lowest level of instrumentation and fusion was the stable vertebra (same as neutral vertebra) in 14 patients (Group I), the neutral vertebra if it is one level cephalad to stable vertebra in 6 patients (Group II) and the stable vertebra if it is one level caudad to neutral vertebra in 9 patients (Group III). The spontaneous correction in the lumbar curve was 58 % in Group I (*figure I*), 53 % in Group II (*figure II*) and 40 % in Group III (*figure III*). There was no radiographic evidence of correction loss, implant loosening, dislodgement, low back pain complaint or fracture during the follow-up period. There were neither decompensation seen during follow-up period nor re-operations applied in the patient group.

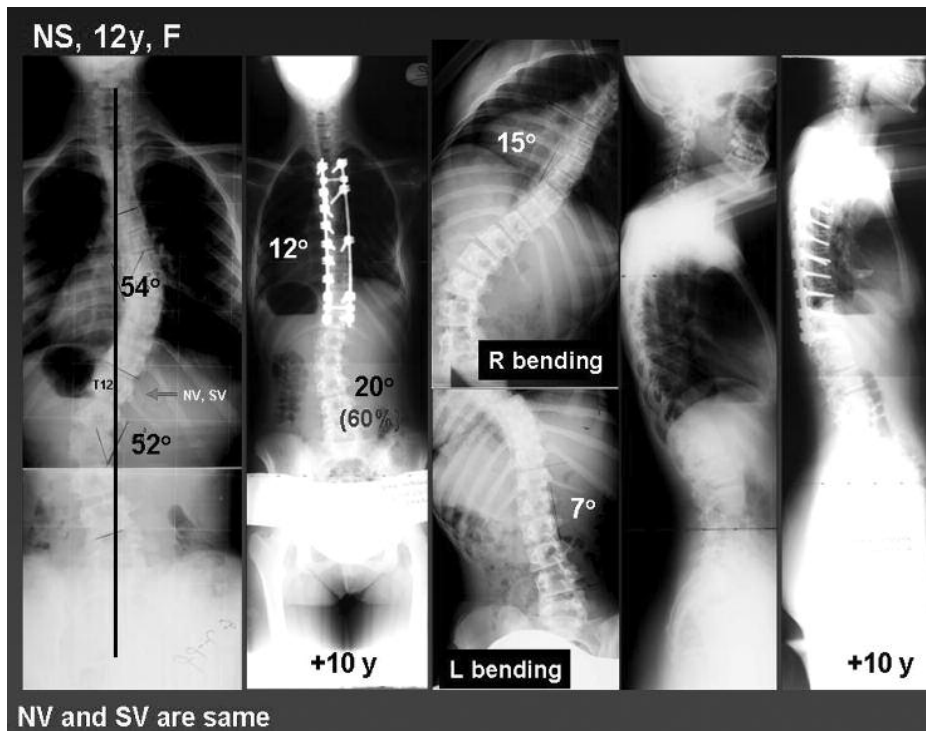


Figure-1. The lowest level of instrumentation and fusion was the stable vertebra (same as neutral vertebra) in 14 patients (Group I).

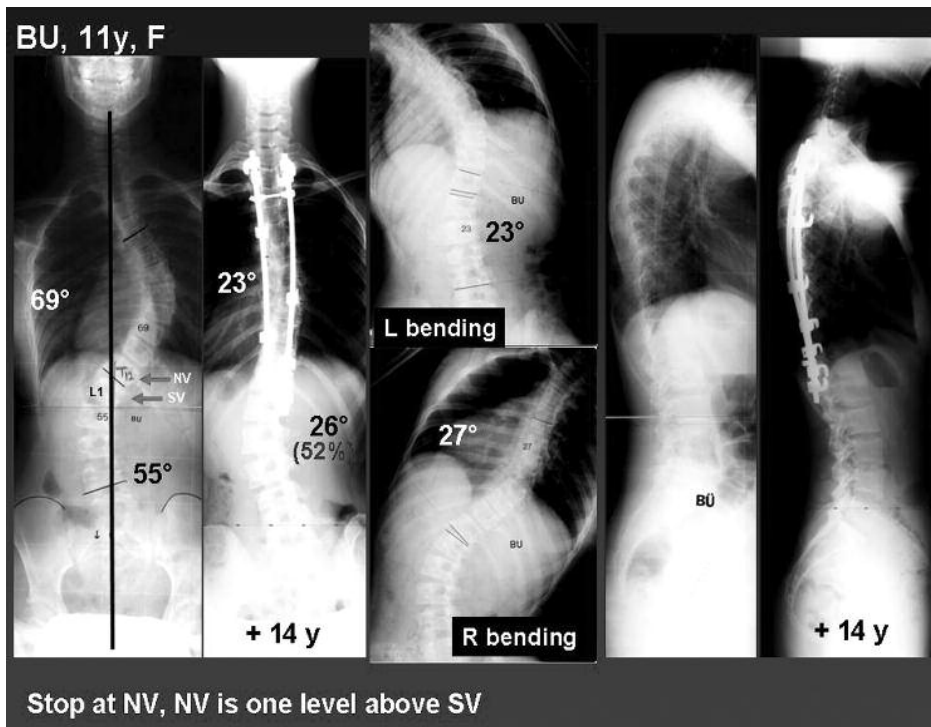


Figure-2. The lowest level of instrumentation and fusion was the neutral vertebra if it is one level cephalad to stable vertebra in 6 patients (Group II).

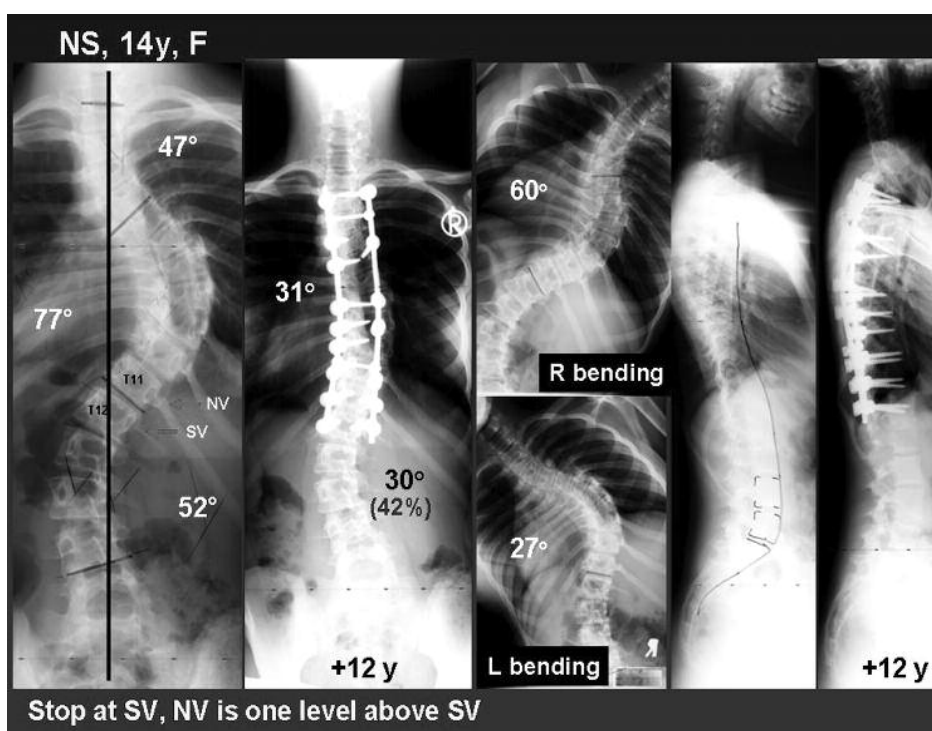


Figure-3. The lowest level of instrumentation and fusion was the stable vertebra if it is one level caudad to neutral vertebra in 9 patients (Group III).

DISCUSSION:

The goals of surgical treatment for adolescent idiopathic scoliosis are to halt curve progression, maintain balance, and correct deformity, while fusing the least amount of motion segments and avoiding complications. Selective thoracic fusion provides for the control and partial correction of the major curve while maintaining mobile lumbar motion segments. Numerous reports describe the potential of the unfused lumbar curve to accommodate to the corrected thoracic curve while maintaining global balance^(12-13,15,18). Occasionally, the unfused lumbar curve is not able to accommodate to the corrected alignment and the development of global imbalance follows^(1,14,21).

After the introduction of 3rd generation spinal implants (C-D from 1985); severe decompensation after selective thoracic fusion

was reported due several reasons such as; overcorrection of thoracic curve, derotation maneuver with instrumentation, > 45 degrees lumbar curves with low flexibility, global thoracic hyperkyphosis and < 40% apical lumbar vertebra derotation^(1-2,6,9,15,19-20).

The surgical alternative to selective thoracic fusion is fusion of both curves. Typically, fusion of the major thoracic curve and compensatory lumbar curve involves a long fusion from the upper thoracic spine to either L3 or L4. Advantages associated with fusion of both curves are the greatly diminished risk of postoperative decompensation and improved correction of both curves. However, these benefits must be weighed against the increased potential for accelerated lumbar degeneration and an increased incidence of late sagittal decompensation and pain (3-5, 10). Lumbar motion is important for function during the

decades of life these adolescent patients have remaining. There is reason to believe that distal degeneration will be less problematic if more motion segments remain below a fusion.

Very little has been reported on the outcome of selective thoracic fusion of main thoracic compensatory lumbar curves in which the lumbar apical vertebra is completely deviated from the midline. To our knowledge, there are only two studies reporting the results of selective thoracic fusion in the presence of "C" modifier curves^(6,11) that the spontaneous correction ability of such curves is limited with 32 % to 68 % lumbar decompenzation rate in 5-year follow-up. Unfortunately, additional published studies on the success of selective thoracic fusion specifically in the presence of widely translated compensatory lumbar curves are lacking, and the long-term fate of the unfused "C" modifier, large magnitude lumbar curve is unknown.

King *et al.*⁽¹²⁾ did not report a certain flexibility ratio of compensatory lumbar curve for selective thoracic fusion and Lenke *et al.*⁽¹⁴⁾ proposed that to fuse selectively in a false double major curve, the thoracic curve should be at least 20 % bigger, lumbar curve should be at least 20 % flexible. According to our criteria, the flexibility ratio of compensatory lumbar curve should be at least 50 %, or in other words, should be at least 10 % more flexible than main thoracic curve according to side bending graphics to be able to perform selective thoracic fusion. After the year 1999; we are using traction radiographies taken under general anesthesia for the evaluation of curve flexibility⁽⁸⁾ and our newer cases undergoing selective thoracic fusion show much more flexibility of compensatory lumbar curve (ratio between 80 % to 85 %).

Although, the current study was retrospective in nature and, as such, suffers from the

shortcomings of all retrospective studies like limited number of patients and insufficient statistical power; we have founded that selective thoracic fusion can work in such large lumbar curves. So; according to our results, we can conclude that criteria for selective thoracic fusion established by King *et al.*⁽¹²⁾ are still valid. Posterior selective thoracic fusion works in all Lenke type 1C, 3C or King Type II curves regardless of rotation, translation of apical lumbar vertebra and magnitude of compensatory lumbar curve. One simple principle different from King's criteria is that if the neutral vertebra and the stable vertebra is not the same vertebra and if the stable vertebra is within the lumbar curve, it is better to stop instrumentation and fusion distally at the neutral vertebra to obtain better spontaneous compensatory lumbar curve correction even the CSVL does not touch neutral vertebra as it will be centered over the sacrum to achieve a balanced, stable spine after correction.

REFERENCES:

1. Bridwell K, McAllister J, Betz R, Huss G, Clancy M, Schoenecker PL. Coronal decompenzation produced by Cotrel-Dubousset 'derotation' maneuver for idiopathic right thoracic scoliosis. *Spine* 1991; 16: 769-777.
2. Chang KW, Chang KI, Wu CM. Enhanced capacity for spontaneous correction of lumbar curve in the treatment of major thoracic-compensatory C modifier lumbar curve pattern in idiopathic scoliosis. *Spine* 2007; 32: 3020-3029.
3. Cochran T, Irstam L, Nachemson A. Long-term anatomic and functional changes in patients with adolescent idiopathic scoliosis treated by Harrington rod fusion. *Spine* 1983; 8: 578-584.
4. Danielson AJ, Cederlund CG, Elkhalm S, Nachemson AL. The prevalence of disc aging and back pain after fusion extending into the

- lower lumbar spine: a matched MR study twenty-five years after surgery for adolescent idiopathic scoliosis. *Acta Radiol* 2001; 42: 187-197.
5. Edgar M, Mehta M. Long-term follow-up of fused and unfused idiopathic scoliosis. *J Bone Joint Surg* 1998; 70-B:712-716.
 6. Edwards CC, Lenke LG, Peelle M, Sides B, Rinella A, Bridwell KH. Selective thoracic fusion for adolescent idiopathic scoliosis with C modifier lumbar curves: 2 to 16-year radiographic and clinical results. *Spine* 2004; 29: 536-546.
 7. Ginsburg HH, Goldstein LA, Robinson SC, Cari DPK, Robinson SC, Jensen M. Back pain in postoperative idiopathic scoliosis: a long term follow-up study. *Spine* 1979; 4: 518.
 8. Hamzaoglu A, Talu U, Tezer M, Mirzanli C, Domanic U, Goksan SB. Assessment of curve flexibility in adolescent idiopathic scoliosis. *Spine* 2005; 30: 1637-1642.
 9. Hansen RC, vanRhijn LW, Duinkerke E, van Ooij A. Predictability of spontaneous lumbar curve correction after selective thoracic fusion in idiopathic scoliosis. *Eur Spine J* 2007; 16: 1335-1342.
 10. Hayes M, Tompkins S, Herndon WA, Gruel CR, Kopta JA, Howard TC. Clinical and radiological evaluation of lumbosacral motion below fusion levels in idiopathic scoliosis. *Spine* 1998; 13: 1161-1167.
 11. Kalen V, Conklin M. The behavior of the unfused lumbar curve following selective thoracic fusion for idiopathic scoliosis. *Spine* 1990; 15: 271-274.
 12. King H, Moe J, Bradford DS, Winter RB. The selection of fusion levels in thoracic idiopathic scoliosis. *J Bone Joint Surg* 1983; 65-A: 1302-1313.
 13. Lenke L, Bridwell K, Baldus C, Blanke K. Preventing decompensation in King Type II curves treated with Cotrel-Dubousset instrumentation: strict guidelines for selective fusion. *Spine* 1992; 17S: 274-281.
 14. Lenke L, Bridwell K, Baldus C, Blanke K. Cotrel-Dubousset instrumentation for adolescent idiopathic scoliosis. *J Bone Joint Surg* 1992; 74-A: 1056-1067.
 15. Lenke L, Betz R, Bridwell K, Harms J, Clements DH, Lowe TG. Spontaneous lumbar curve coronal correction after selective anterior or posterior thoracic fusion in adolescent scoliosis. *Spine* 1999; 25: 1663-1672.
 16. Lenke L, Betz R, Harms J, Bridwell KH, Clements DH, Lowe TG, Blanke K. Adolescent idiopathic scoliosis: a new classification to determine extent of spinal arthrodesis. *J Bone Joint Surg* 2001; 83-A: 1169-1181.
 17. McCall RE, Bronson W. Criteria for selective fusion in idiopathic scoliosis using Cotrel-Dubousset instrumentation. *J Pediatr Orthop* 1992; 12: 475-479.
 18. McCance S, Denis F, Lonstein J, Winter RB. Coronal and sagittal balance in surgically treated adolescent idiopathic scoliosis with the King II curve pattern. A review of 67 consecutive cases having selective thoracic arthrodesis. *Spine* 1998; 23: 2063-2073.
 19. Netwon OP, Faro FD, Lenke LG. Factors involved in the decision to perform a selective versus nonselective fusion of Lenke 1B and 1C (King-Moe II) curves in adolescent idiopathic scoliosis. *Spine* 2003; 28: S217-S223.
 20. Patel PN, Upasani VV, Bastrom TP, Marks MC, Pawelek B, Betz RR, Lenke LG, Newton PO. Spontaneous lumbar curve correction in selective thoracic fusion of idiopathic scoliosis. A comparison of anterior and posterior approaches. *Spine* 2008; 33: 1068-1073.
 21. Richards S. Lumbar curve response in type II idiopathic scoliosis after posterior instrumentation of the thoracic spine. *Spine* 1992; 17S: 282-286.
 22. Von Lackum VH, Miller JP. Critical observations of the results in the operative treatment of scoliosis. *J Bone Joint Surg* 1949; 31-A (1): 102-106.