



RARE S4 FRACTURE WITH INTERESTING INJURY MECHANISM

İLGİNÇ BİR YARALANMA MEKANİZMASI İLE GELİŞEN NADİR S-4 KIRIĞI

Ömer ERŞEN¹,
Burak BİLEKLİ²,
Serkan BİLGİÇ³,
Nuray CAN²,
Erbil OĞUZ³

¹Orthopedics and Traumatology,
MD, TSK Rehabilitation Center,
Ankara

²Orthopedics and Traumatology
resident, MD, GATA Orthopedics
and Traumatology Department,
Ankara

³Orthopedics and Traumatology,
MD, Assoc. Prof., GATA
Orthopedics and Traumatology
Department, Ankara

Address: Serkan Bilgiç,
GATA Orthopedics and
Traumatology Department. 06018
Etlik / Ankara
Tel.: 0312 3043076
Fax: 0312 3045500
E-mail: serbil11@yahoo.com
Received: 2nd January, 2012
Accepted: 20th February, 2012

SUMMARY:

Sacral fractures due to direct trauma are very rare. Sacral fractures usually occur as a result of high energy trauma, and are accompanied by pelvic fractures in 40–50% of cases. With conventional radiological techniques, sacrum fractures can be overlooked due to intestinal gas, the shadow of the bladder or the shape of the sacrum itself. It needs to be kept in mind that 35% of sacral fractures can be overlooked in X-rays. In the presence of clinical suspicion, computerized tomography is needed for a diagnosis.

We report here the diagnosis by computerized tomography of a sacrum fracture of a 20-year-old man, who suffered from an S4 fracture with a rare mechanism of injury, and received conservative treatment.

Key words: Sacral fracture, direct trauma, diagnosis, treatment

Level of Evidence: Case report, Level V

ÖZET:

Direk travma sonrası görülen sakral kırıklar nadirdir. Sakral kırıklar genellikle % 40-50 oranında eşlik eden pelvik kırıklarla seyrederek ve yüksek enerjili travmalar sonrasında görülürler. Sakrum kırığının konvansiyonel radyolojik tetkiklerle değerlendirilmesi önündeki bağırsak gazı, mesane ve sakrumun açılanması nedeniyle zordur. Düz grafiyle sakrum kırıklarının % 35'i gözden kaçırılabilir olduğu unutulmamalıdır. Şüpheli klinik durumlarda konvansiyonel radyograflarla tanı konulamazsa 1-2 mm kesitlerle bilgisayarlı tomografi kullanılabilir.

Bu çalışmada intergluteal sulkusa direk travma sonrası gelişen nadir sakrum kırığının bilgisayarlı tomografi ile tanısı ve konservatif tedavisi sunulmaktadır.

Anahtar Kelimeler: Sakrum kırığı, direkt travma, tanı, tedavi

Kanıt Düzeyi: Olgu sunumu, Düzey V

INTRODUCTION:

Sacral fractures after direct trauma are rare. Sacral fractures are observed with pelvic fractures in 40–50% of cases, and are most commonly seen after high-energy trauma^{1,5,6}. Additionally, diagnosis of these fractures is difficult using conventional radiology techniques, due to the superposition of bowel gas in front of the sacrum^{8,14}.

In this case study, a rare sacral fracture that was diagnosed with computerized tomography and treated with conservative treatment, and occurred after direct trauma to the intergluteal sulcus, is presented.

CASE PRESENTATION:

A 20-year old male patient presented at the emergency room with coccygeal pain after a fall. X-rays were normal, and so he was treated with analgesics. The patient was not referred to the orthopedic clinic. After three days, the patient came to the orthopedic clinic with ongoing pain. The patient history revealed that he had fallen from a sledge while sledging on snow, been dragged downhill, and hit his sacrum on a stone. As this injury resembled the part of a credit card machine through which the card is swiped, we named it a “card swipe” fracture.

A physical examination of the patient revealed ecchymosis in the sacral region, edema, superficial lacerations and severe pain on palpation. A rectal examination did not reveal any bleeding or lacerations. The bulbo-cavernosus reflex and the perianal sensation were normal. A neurovascular examination was normal and there were no additional pathologies in other system examinations (Figure-1).

Lateral X-rays of the patient showed a transverse fracture line in the fourth sacral vertebra (Figure-2).

CT of the patient showed the transverse fracture of the 4th sacral vertebrae (Figure-3). Patient was treated with analgesic/anti-inflammatory medicine together with topical epithelization treatment for the superficial lacerations in the sacral region. Patient was given 4 weeks of bed rest, limitation of activity and analgesic treatment and followed up.

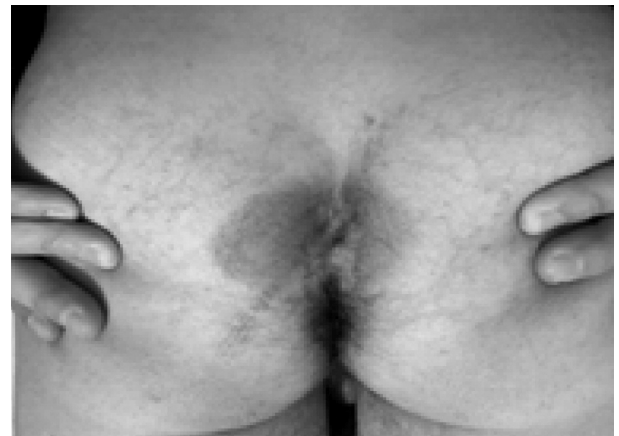

Figure-1. Clinical view of the patient.

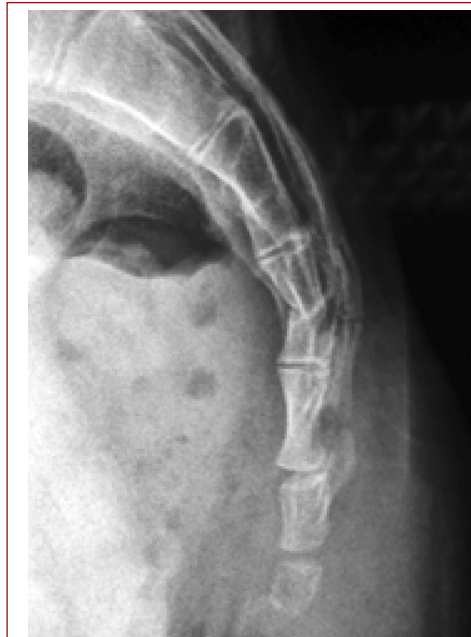

Figure-2. Suspicious fracture at the S4 vertebra.

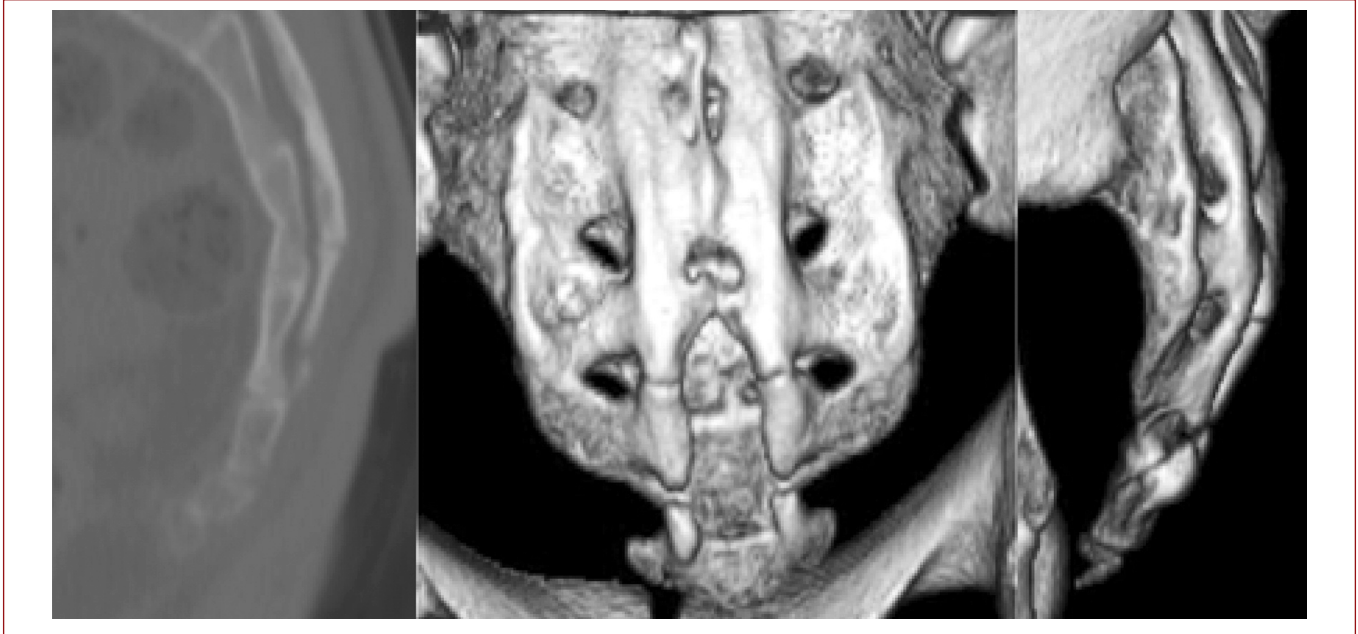


Figure-3. CT images of the sacral fracture.

We considered the fracture to be stable and so orthosis was not applied. A follow-up appointment four weeks after the incident showed complete regression of the clinical complaints.

DISCUSSION:

Denis et al. grouped sacral fractures into three zones, according to their anatomical location and neurological damage risk. Zone I includes the alar region, Zone II the sacral foramina, and Zone III sacral wing fractures³. Roy-Camille then grouped Zone III fractures into four groups⁹. This classification was later modified by Strange-Vognsen and Lebech. Type 1 are fractures that are angled but not translated, Type 2 are angled and translated, Type 3 are fractures that are translated to the cephalic or caudal direction, and Type 4 are segmental complex fractures resulting from axial impaction¹¹. In this study, the fracture was Zone III. As it was angled but not translated, it fits the Roy-Camille Type 1 subgroup.

Sacral fractures generally occur after high-energy trauma, such as falling from a height or traffic accidents, by indirect mechanisms^{3,5,6}. The case presented here occurred after a direct trauma to the intergluteal sulcus. This type of injury, that we termed a card swipe fracture, has never before been defined in the literature.

It is hard to evaluate sacral fractures by conventional radiological methods, due to gas superposition and the position of the bladder, which causes angling of the sacrum^{10,14}. Pelvic inlet or outlet X-rays or Ferguson X-rays can be used to evaluate the sacrum^{4,13}. In direct X-rays, it must be remembered that 35% of sacral fractures may be overlooked⁷. In suspicious clinical situations, if a diagnosis cannot be made through conventional radiographs, computerized tomography with 1–2 mm thick slices can be used¹². In this case, a diagnosis was made by conventional X-ray. Further diagnostics were made to detect possible accompanying pathologies, which were able to confirm the initial diagnosis.

Because sacral fractures generally happen after high-energy trauma, head trauma and internal organ trauma are frequently observed². In this case, an isolated sacral fracture was detected, as the relatively high-energy trauma had a localized effect and the intensity of the trauma did not cause any additional wounds.

Isolated sacral fractures can be easily overlooked, and this must be taken into account when considering any case in the emergency room with a possible sacral trauma. A conventional X-ray may not detect the fracture, so in cases where a sacral fracture is suspected, computerized tomography must be used.

REFERENCES:

1. Bilgiç S, Kılınçoğlu V, Yurttaş Y, Soyulu K, Sehirlioğlu A. Isolated zone I vertical fracture of first sacral vertebrae: a case report. *Cases J* 2009; 2: 6257
2. Dalal SA, Burgess AR, Siegel JH, Young JW, Brumback RJ, Poka A, Dunham CM, Gens D, Bathon H.. Pelvic fracture in multiple traumas: classification by mechanism is key to pattern of organ injury, resuscitative requirements, and outcome. *J Trauma* 1989; 29: 981-1002.
3. Denis F, Davis S, Comfort T. Sacral fractures: An important problem. Retrospective analysis of 236 cases. *Clin Orthop* 1988; 227: 67-81.
4. Ebraheim NA, Sabry FF, Tomic A. Radiographic evaluation of transverse sacral fractures. *Orthopedics* 2001; 24: 1071-1074.
5. Inaba K, Sharkey PW, Stephen DJ, Redelmeier DA, Brenneman FD. The increasing incidence of severe pelvic injury in motor vehicle collisions. *Injury* 2004; 35: 759-765.
6. Kim MY, Reidy DP, Nolan PC, Finkelstein JA. Transverse sacral fractures: case series and literature review. *Can J Surg* 2001; 44: 359-363
7. Levine AM. Lumbar and sacral spine trauma. In: Browner BD, Jupiter JB, Levine AM, Trafton PG (Eds.). *Skeletal Trauma: Fractures, Dislocations, and Ligamentous Injuries*. W.B. Saunders, Philadelphia 1992; pp: 805-848.
8. Resnik CS, Stackhouse DJ, Shanmuganathan K, Young JWR. Diagnosis of pelvic fractures in patients with acute pelvic trauma: efficacy of plain film radiographs. *AJR Am J Roentgenol* 1992; 158: 109-112.
9. Roy-Camille R, Saillant G, Gagna G, Mazel C. Transverse fracture of the upper sacrum. Suicidal jumper's fracture. *Spine* 1985; 10: 838-845.
10. Sklar EML, Ruiz A, Falcone S. Radiographic evaluation of spinal injuries. In: Cotler JM, Simpson JM, An HS (Eds.). *Surgery of Spinal Trauma*. Lippincott Williams & Wilkins, Philadelphia 2000; pp: 127-155.
11. Strange-Vognsen HH, Lebech A. An unusual type of fracture in the upper sacrum. *J Orthop Trauma* 1991; 5: 200-203.
12. Templeman D, Goulet J, Duwelius P, Olson S, Davidson M. Internal fixation of displaced fractures of sacrum. *Clin Orthop* 1996; 329: 180-185.
13. Vaccaro AR, Kim DH, Brodke DS, Harris M, Chapman JR, Schildhauer T, Routt C, Sasso RC. Diagnosis and management of sacral spine fractures. *J Bone Joint Surg* 2004; 86-A: 166-175.
14. White JH, Hague C, Nicolau R, Gee R, Marchinkow LO, Munk PL. Imaging of sacral fractures. *Clinical Radiology* 2003; 58: 914-921.