



OSTEOMYELITIS IN MULTIPLE VERTEBRAE IN PATIENTS WITH SICKLE CELL ANEMIA: PERCUTANEOUS ANTERIOR ABSCESS DRAINAGE AND POSTERIOR DECOMPRESSION

ORAK HÜCRELİ ANEMİLİ HASTADA MULTİPL VERTEBRADA OSTEOMİYELİT: PERKÜTAN ANTERİOR APSE DRENAJI VE POSTERİOR DEKOMPRESYON

Metin ÖZALAY¹,
Murat Ali HERSEKLI¹

¹Başkent University Medical School, Orthopedics and Traumatology Department, Adana, Turkey.

ABSTRACT:

In sickle cell anemia, vertebral osteomyelitis is a common complication in patients with spinal symptoms. The most common organisms causing osteomyelitis in these patients are Staphylococcus aureus and Salmonella. This case study concerns a 25-year-old male sickle cell anemia patient, who was admitted to hospital with complaints of lower back and bilateral leg pain, and difficulty walking. Multiple vertebral osteomyelitis, a paravertebral abscess and an epidural abscess were diagnosed in the lumbar area. Percutaneous anterior abscess drainage and posterior decompression were performed. A culture revealed methicillin-sensitive Staphylococcus aureus. The patient responded well to surgery and six months of antibiotic treatment, without the need for recurrent surgical treatment.

Key Words: osteomyelitis, sickle cell anemia, abscess, epidural abscess

Level of evidence: Case report, Level IV

ÖZET:

Orak hücreli anemide vertebra osteomiyeliti spinal bulguları olan hastalarda gelişebilecek bir komplikasyon olup, en sık stafilokokus aureus ve salmonella enfeksiyonları görülmektedir. 25 yaşında erkek orak hücreli anemi mevcut olan hasta bel ve her iki bacak ağrısı, halsizlik, gün geçtikçe artmakta olan yürüme gücünü nedeniyle başvurdu. Lomber bölgede multipl vertebra osteomiyeliti, paravertebral apse ve epidural bölgede apse tespit edildi. Hastaya perkütan ultrasonografi eşliğinde anterior apse drenajı ve posterior yolla epidural apse drenajı ve dekompresyon uygulandı. Kültüründe metisiline duyarlı stafilokokus aureus üredi. Hastaya uygulanan cerrahi tedavi ve 6 aylık antibiyotik tedavisi ile başka bir cerrahi girişim gerektirmeden, iyi sonuç alındı.

Anahtar Kelimeler: osteomiyelit, orak hücreli anemi, apse, epidural apse.

Kanıt düzeyi: Olgu sunumu, Düzey IV

Address: Metin Özalay,
Başkent Üniversitesi Adana
Hastanesi, Dadaloğlu mah.
39. sok, No.6, Yüreğir, 01250,
Adana.
Tel.: 0322 3272727
Fax: 0322 3271273
E-mail: metinozalay@gmail.com
Received: 10th January, 2012
Accepted: 25th February, 2012

INTRODUCTION:

Spinal infections are more common today due to an increase in immune system diseases. Vertebral involvement in sickle cell anemia is a result of bone marrow hyperplasia, and the radiological findings are characterized by a decrease in vertebral height and annular overflow in intervertebral discs^{1,8}. In cases where avascular necrosis has developed, vertebral collapse can be observed. In patients with spinal symptoms, vertebral osteomyelitis must be eliminated³. It has been shown that 24% of patients with spinal symptoms have osteomyelitis⁵. In this study, a patient with sickle cell anemia and multiple spondylitis treated with percutaneous drainage and antibiotics is presented, and spondylitis and its treatment are discussed, taking into account the recent literature.

CASE PRESENTATION:

A 24-year-old male patient with sickle cell anemia was referred to our clinic after experiencing lumbar and bilateral leg pain complaints and increased difficulty in walking for a month. The patient's history included antibiotic treatment as an inpatient at another clinic for lethargy and fever.

In a physical examination, the patient had tenderness in the lumbar region, constraint in movement, and a positive Laseque test in both legs. Both lower extremities showed progressive neurological deficit, with a muscle power of 4 in the tibialis anterior, extensor hallucis longus and gluteus medius muscles. The reflexes were normoactive and no pathological reflexes were observed.

The laboratory findings included 7 g/dl hemoglobin, 13800 leucocytes, a sedimentation rate of 53 mm/s, and 128 mg/l CRP. *Brucella* and *Salmonella* agglutination tests and PPD were negative.

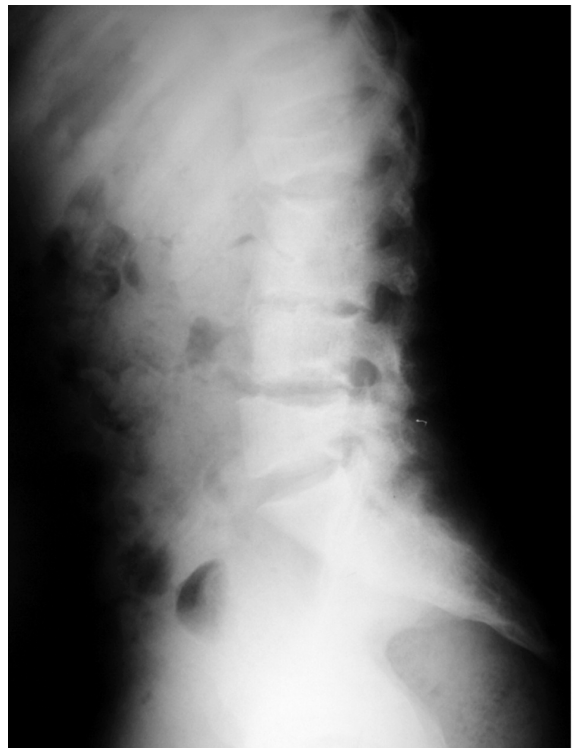
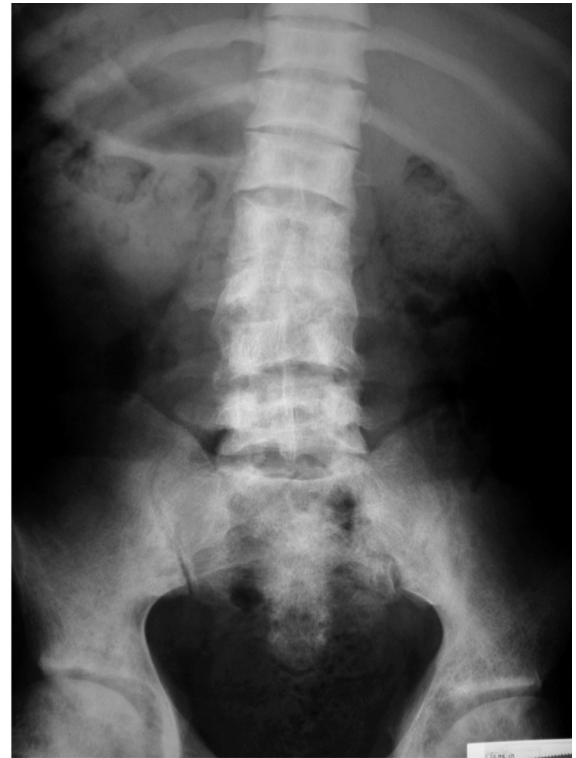
Figure-1. Collapse in lumbar 2, 3 and 4 vertebrae and shrinkage in disc spaces.

Hemoglobin electrophoresis showed 87.40% Hb A, 9.7% Hb S and 2.09% Hb A2. Blood transfusion was not performed before surgery.

In X-rays, biconcave vertebrae, compression of the second, third, and fourth lumbar vertebrae, and shrinkage of the disc space were observed (Figure-1). MRI images with contrast showed contrast retention in the second, third, and fourth lumbar vertebrae, paravertebral abscess foci, and an epidural abscess (Figures 2 and 3).

The retroperitoneal abscess region was biopsied using ultrasonography as a guide, a catheter was placed and the abscess was drained. The abscess material was cultured for pathogens. From the sample taken from the anterior region, *Staphylococcus aureus* sensitive to methicillin was grown. There was no growth from the posterior. According to the antibiograms, the patient was treated with ceftriaxone 2×1 g and teicoplanin 2×400 mg for three weeks, and amoxicillin clavulanic acid 1 g 2×1 and ciprofloxacin 750 mg 2×1 PO for six months.

The CRP values decreased to 20 mg/l in the first week and normalized in the sixth week. The pathology results were compliant with osteomyelitis. A follow-up MRI in the fifth month showed regression of the epidural and paravertebral abscesses and osteomyelitis in the corpus region.

DISCUSSION:

In sickle cell anemia, osteomyelitis is generally seen in the medullary cavities of tubular bones. Vertebral osteomyelitis can also be observed rarely in this group of patients. Collapse in the vertebrae is generally due to avascular necrosis, but osteomyelitis must be eliminated. Early

diagnosis and treatment are very important to prevent neurological deficit and similar complications^{2,6,7}.

Unclear symptoms may cloud the diagnosis of infection². In this case, a decrease in the height of the vertebrae, similar to findings of avascular necrosis, was determined. Culture of the surgical material showed methicillin-sensitive *S. aureus*. The most commonly observed agents in sickle cell anemia are *Staphylococcus aureus* and *Salmonella* spp. Anaerobic agents are infrequently observed. *Bacteroides fragilis* has been reported rarely^{1,4,7,8}. In younger children, *Salmonella* is more common³.

Spondylodiscitis seen in sickle cell anemia patients is responsive to conservative treatment^{3,6}. Indications for surgical intervention are neurological deficit, deformity, development of instability, abscess formation, insufferable pain, and unresponsiveness to medical treatment. The most commonly used surgical intervention is surgical decompression and an anterior support graft. Eradication of infection and alignment of the spinal elements are targeted in this treatment. In this case, taking into consideration the surgical morbidity risk, the patient was treated with anterior percutaneous abscess drainage. This was selected due to the high morbidity rates with an anterior surgical approach. Because the patient did not have excessive height loss in the vertebrae, he did not require posterior instrumentation, and so only posterior decompression was applied.

Interventions using the percutaneous technique harbor a low morbidity and mortality risk.

It is also a very effective method for diagnosis (biopsy) and treatment (abscess drainage) of thoracic and lumbar spinal infections, as it

allows a combination of techniques such as fluoroscopy, ultrasonography, or computerized tomography to be used alongside the procedure⁹.

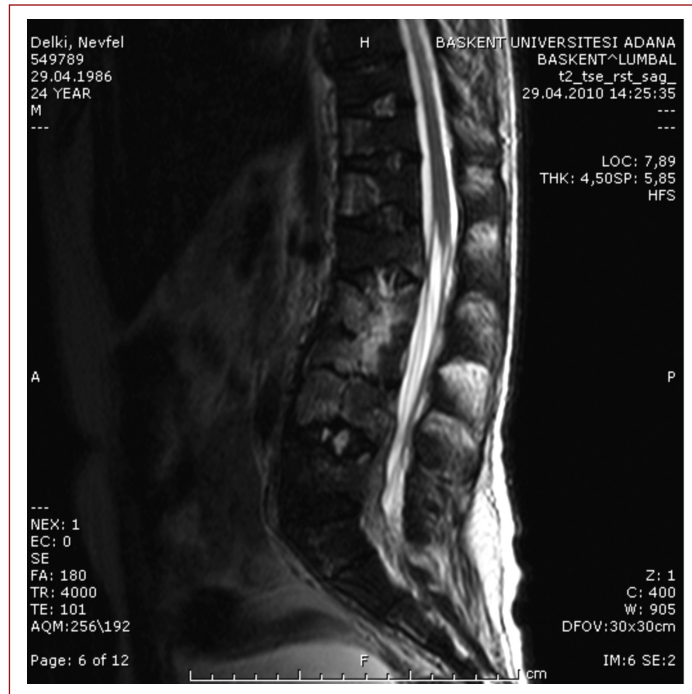

Figure-2. Osteomyelitis appearance in lumbar 2-3-4 vertebral corpus in contrast T2 sagittal MRI sections.

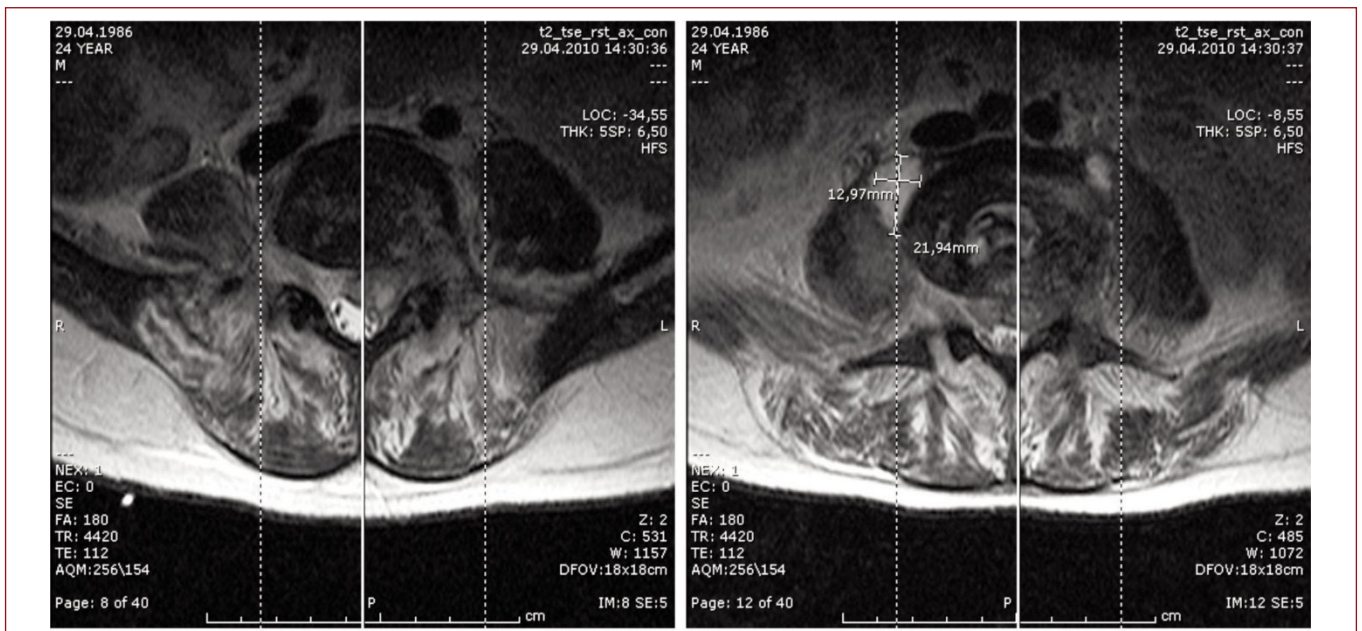


Figure-3. a. Epidural abscess in T2 axial sections, **b.** Paravertebral abscess foci.

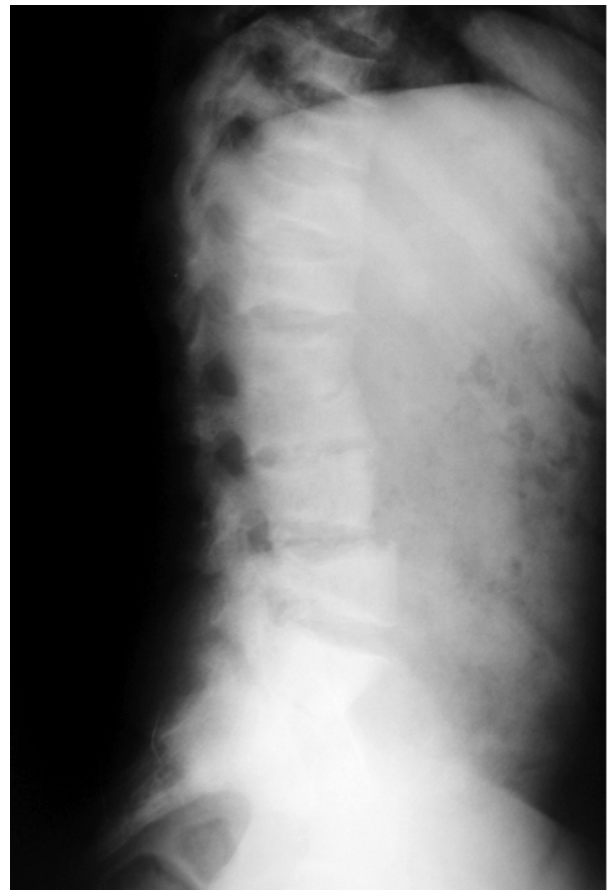
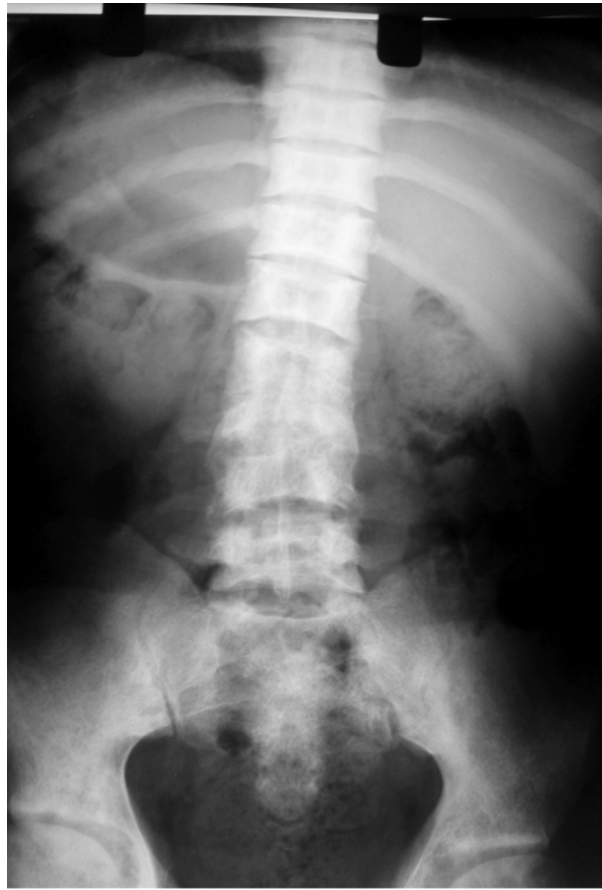

Figure-4. Radiological appearance postoperatively.

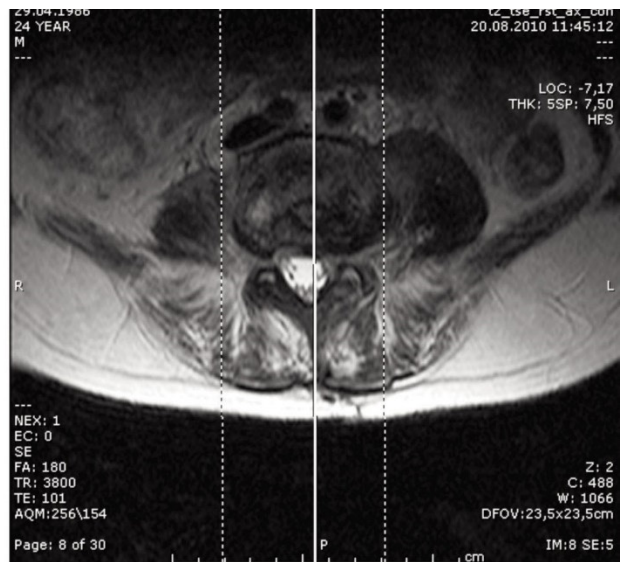
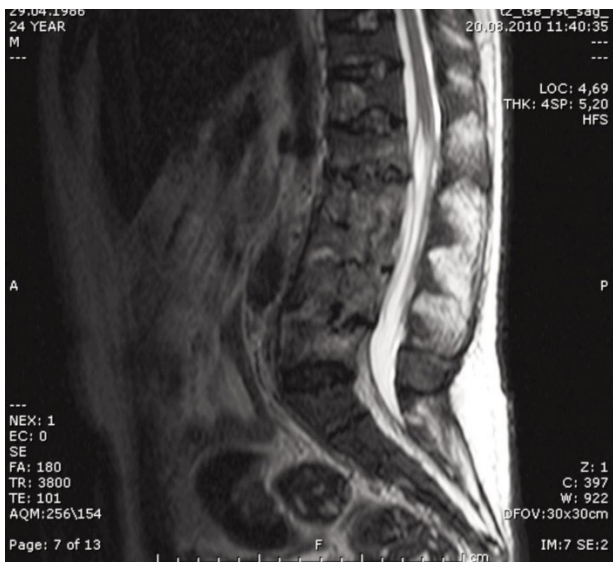


Figure-5. X-ray and MRI images in the postoperative fifth month.

Currently, the first line of treatment for vertebral osteomyelitis is percutaneous biopsy and abscess drainage with antimicrobial treatment³.

Our patient responded to the anterior abscess drainage and posterior epidural abscess decompression treatment. The patient's infection regressed and his neurological condition improved.

Vertebral osteomyelitis must always be kept in mind in a sickle cell anemia patient with spinal symptoms. Anterior and posterior open surgery has serious morbidity risks, and the method described in this paper shows less morbidity and mortality. In conclusion, for patients with sickle cell anemia and multiple spondylitis, percutaneous abscess drainage and antibiotic treatment could have favorable results without the need for surgery.

REFERENCES:

1. Al-Tawfig JA. Bacteroides fragilis bacteremia associated with vertebral osteomyelitis in a sickle cell patient. *Intern Med* 2008; 47(24): 2183-2185.
2. Devrim I, Kara A, Kanra G, Yazici M, Gucer S, Gumruk F, Cengiz AB, Secmeer G. Atypical presentation of spondylitis in a case with sickle cell disease. *Turk J Pediatr* 2005; 47(4): 369-372.
3. Herring JA. Hematologic disorders. In: Herring JA (Ed.). *Tachdjian's Pediatric Orthopaedics from the Texas Scottish Rite Hospital for Children*. 3rd edition, Vol. 3, WB Saunders, Philadelphia 2002; pp: 1879-1894.
4. Lott-Duarte AH, Dourado L, Tostes M, Nascimento-Carvalho CM. Extensive spondylodiscitis with epidural abscess causing fever and lower limbs pain in a child with sickle cell disease. *J Pediatr Hematol Oncol* 2008; 30(1): 70-72.
5. Martino AM, Winfield JA. Salmonella osteomyelitis with epidural abscess. A case report with review of osteomyelitis in children with sickle cell anemia. *Pediatr Neurosurg* 1990-1991; 16(6): 321-325.
6. Morgan JS, Laber DA. Ceftriaxone-resistant Salmonella septicemia and osteomyelitis in sickle cell disease adults. *South Med J* 2006; 99(6): 625-627.
7. Rivierez M, Heyman D, Bazin M. Vertebral osteomyelitis with epidural abscess in child with sickle cell disease. *Neurochirurgie* 2000; 46(1): 47-49,
8. Sadat-Ali M, Ammar A, Corea JR, Ibrahim AW. The spine in sickle cell disease. *Int Orthop* 1994; 18: 154-156.
9. Tsui HF, Chiu KH, Leung KS. Osteomyelitis of the spine due to salmonella infection-conservative treatment with quinolone: a case report. *Can J Surg* 1997; 40(1): 48-50.