



## PAIN RELIEF CAN BE ACHIEVED BY VERTEBROPLASTY IN KÜMMEL' S DISEASE

### KÜMMELL HASTALIĞINDA VERTEBROPLASTİ İLE AĞRI Palyasyonu Sağlanabilir

Alpaslan ŞENKÖYLÜ<sup>1</sup>,  
Mehmet Ali DEVECİ<sup>2</sup>,  
Necdet ALTUN<sup>3</sup>

<sup>1</sup>Orthopedics and Traumatology, MD, Assoc. Prof., Gazi University, Medical School, Orthopedics and Traumatology Department, Beşevler, Ankara.  
<sup>2</sup>Orthopedics and Traumatology, MD, Assist. Prof., Çukurova University, Medical School, Orthopedics and Traumatology Department, Balcalı, Adana.  
<sup>3</sup>Orthopedics and Traumatology, MD, Prof., Gazi University, Medical School, Orthopedics and Traumatology Department, Beşevler, Ankara.

**Address:** Doç.Dr. Alpaslan Şenköylü  
Gazi Üniversitesi Tıp Fakültesi  
Ortopedi ve Travmatoloji A.D.  
Beşevler-Ankara.  
**Tel.:** 0555 2697998  
**E-mail:** senkoylu@gazi.edu.tr  
**Received:** 5th January, 2012  
**Accepted:** 5th March, 2012

#### SUMMARY:

**Background Data:** Kümmel's Disease is defined as osteonecrosis of the vertebrae, which is characterized radiologically by the phenomenon of vacuum clefts within the vertebral corpus.

**Purpose:** To evaluate the pain relief and quality of life on treatment of Kümmel's Disease with vertebroplasty.

**Materials and Methods:** Between 2005 and 2010, 14 patients with Kümmel's Disease received a percutaneous vertebroplasty procedure in our department. The mean follow-up was 32 months. The inclusion criteria were: 1. prolonged pain symptoms for more than three months, 2. the presence of a vacuum phenomenon in direct X-rays or CAT scans, and 3. related findings in fat-suppressed T2 magnetic resonance imaging. The VAS, Oswestry Disability Index, and radiographic parameters, including the sagittal index, local kyphosis angle, and compression rate, were compared preoperatively and postoperatively.

**Results and Conclusion:** The VAS and Oswestry scores were significantly improved in all of the patients ( $p<0.05$ ). There were no significant differences between the preoperative and postoperative radiographic measurements ( $p>0.05$ ). There was cement leakage to the paravertebral space in one patient, which remained asymptomatic. The characteristic radiological finding of Kümmel's Disease has been shown in previous studies to be the phenomenon of vacuum clefts. The cause of pain is pathological dynamic mobility of the unfused fracture. Filling the cleft with bone cement can relieve the pain by reducing the dynamic mobility.

**Key words:** Kümmel Disease, vertebral osteonecrosis, osteoporotic vertebral fracture, vertebroplasty

**Level of Evidence:** Retrospective clinical study, Level III

#### ÖZET:

**Geçmiş Bilgiler:** Kümmell Hastalığı, radyolojik olarak vertebra cismi içinde yarık şeklindeki vakum fenomeni ile karakterize vertebranın posttravmatik osteonekrozudur.

**Amaç:** Kümmell Hastalığı olan olguların vertebroplasti ile tedavisi sonrası ağrı palyasyonu ve yaşam kalitesi açısından değerlendirilmesidir.

**Materyal ve Metod:** 2005-2010 yılları arasında radyolojik olarak Kümmell Hastalığı tanısı alan 14 olguya perkütan vertebroplasti uygulanmıştır. Ortalama takip süresi 32 ay olan olguların çalışmaya dahil edilme kriterleri: 1. Ağrı semptomunun üç aydır var olması, 2. direkt röntgenogram ya da bilgisayarlı tomografide vakum fenomeninin saptanması, 3. manyetik rezonans görüntüleme STIR kesitlerinde bununla uyumlu bulguların olmasıydı. Bu kriterlerin birincisine ek olarak ikinci veya üçüncüsünün bulunduğu olgular çalışmaya dâhil edildi. Bu olguların tamamına peruktan vertebroplasti uygulandı. Tüm olgularda ameliyat öncesi ve sonrası görsel analog ağrı cetveli, Oswestry sakatlık indeksi ve radyolojik parametreler karşılaştırıldı.

**Sonuçlar ve Çıkarımlar:** Olguların tamamında görsel analog cetveli ve Oswestry skorlarında anlamlı düzelme izlendi ( $p<0.05$ ). Ameliyat öncesi ve sonrası radyolojik ölçümlerde anlamlı fark yoktu ( $p>0.05$ ). Bir olguda sağ paravertebral bölgeye çimento kaçağı oldu ve bu hasta asemptomatik seyretti. Kümmell Hastalığı'nın radyolojik bulgusunun vertebra cismi içindeki yarık şeklindeki vakum fenomeni olduğu önceki çalışmalarda gösterilmiştir. Bu olgularda ağrı nedeni, bu kaynamaza hattındaki patolojik harekettir. Yarığın kemik çimentosuyla doldurularak patolojik hareketin azaltılması ile yeterli ağrı palyasyonu sağlanabilmektedir.

**Anahtar Kelimeler:** Kümmell hastalığı, vertebra osteonekrozu, osteoporotik vertebra kırığı, vertebroplasti

**Kanıt Düzeyi:** Retrospektif klinik çalışma, Düzey III

---

## INTRODUCTION:

Kümmel's disease is post-traumatic osteonecrosis of the vertebrae. It was first defined in 1985 by Herman Kümmel<sup>17</sup> and is most commonly observed after osteoporotic vertebral fractures. Risk factors include corticosteroid use, alcoholism, and radiotherapy, and in most patients there is no cause other than low energy trauma<sup>4,17</sup>. Although the pathophysiology is not clearly known, it is believed that this disease occurs due to disruption of the circulation of the vertebral body. Disease is most commonly seen in the anterior third of the vertebrae, due to weak circulation in this region. It has been proposed that chronic microfractures damage the arterioles in the medulla, resulting in osteonecrosis<sup>4</sup>.

An important radiological finding of Kümmel's disease is a vacuum phenomenon in the vertebral body, like a cleft. This gas accumulation in the bone can be defined as a pseudarthrosis line, and can be in an open or closed conformation, depending on the position<sup>12,13</sup>. The sensitivity of this direct X-ray finding is 85%, and the specificity is 99%<sup>10</sup>.

Historically, vertebroplasty was first implemented in France for the treatment of hemangioma. Today, it is commonly used for the palliative treatment of pain resulting from osteoporotic vertebral fractures<sup>5,6</sup>.

The aim of this study is to evaluate the pain palliation and quality of life of Kümmel's disease patients after treatment with vertebroplasty.

## MATERIALS AND METHODS:

59 patients who had undergone percutaneous vertebroplasty between 2005 and 2010 were

studied prospectively. 14 (9 female, 5 male) of these patients, who were diagnosed with Kümmel's disease radiologically, were included in the study.

The average age of the patients included in the study was 76 (61–88), and the average surveillance period was 32 months (10–56).

The criteria for inclusion into the study were as follows: 1. Back pain or lumbar pain for at least three months, 2. Additional to the pain, an X-ray or computerized tomography (CT) scan showing a cleft or non-fusion of the fracture line or vacuum phenomenon (Figure-1), and 3. In magnetic resonance imaging (MRI) in fat-suppressed T2 sagittal plane (STIR) sections, a cleft appearance in the vertebral body and a fluid-filled cavity characterized by homogenous hyper-intense signals. A diagnosis of Kümmel's disease was established together with the first criterion by the presence of the second or third criterion<sup>5,10,17</sup>.

Patients where the symptoms were observed for less than three months or no cleft phenomenon was observed in the imaging, as well as patients with neurological findings, were not included in the study.

The patients' age, gender, time of pain onset, level of vertebral fracture, and trauma, and other Kümmel's disease risk factors, accompanying diseases, medications, risk factors for osteoporosis and treatment for osteoporosis were registered. All patients underwent a physical examination, including a neurological examination.

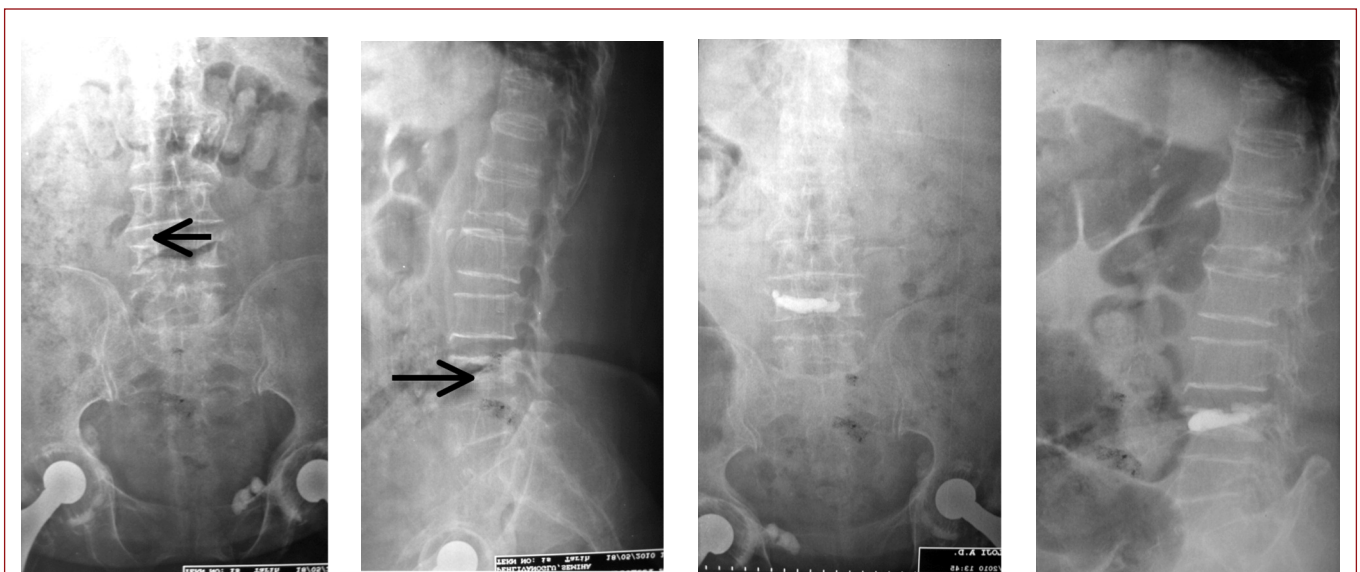## SURGICAL TECHNIQUE:

As defined previously, all the vertebroplasty operations were conducted under local anesthesia and mild sedation in a prone position on a radiolucent table. At the beginning of the procedure, the level of vertebroplasty was defined, and at the antero-posterior position using fluoroscopy, the pedicular entrance zone and the path of the biopsy needle were infiltrated with local anesthesia (5 ml lidocaine or bupivacaine diluted using 10 ml of physiological serum). Then, using fluoroscopy images, in the 2–3 o'clock direction for the right side and in the 9–10 o'clock direction for the left side, the site was penetrated by a biopsy (Jamshidi) needle. The presence of the needle in the pedicle was controlled using lateral fluoroscopy images. At this point, vertebrography was applied, considering the risk of leakage of the cement into the medullary canal, neighboring disc or paravertebral region<sup>15</sup>. For this, 2 ml of non-ionic contrast matter (Iohexol 350 mg/50 ml, Omnipaque®, Opakim, Istanbul) was injected into the biopsy cannula to check

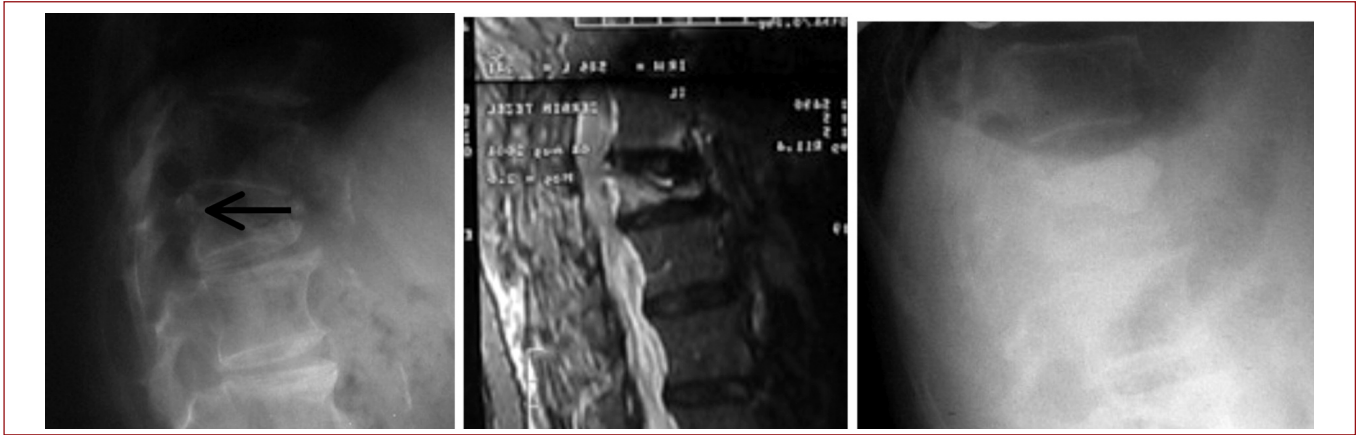
for leakage fluoroscopically. If there were signs of leakage, the cannula was further advanced or reintroduced from another location. If, in a single pedicle, penetration to the cleft was successfully shown by a radiopaque filled cavity, bone cement was applied to a single pedicle (Figure 2). In order to compare the radiopaque bone cement and contrast matter images, the region was washed with physiological serum.

As recommended by the vertebroplasty kit that was used, cement applicators were placed and mixed cement was injected. The amount of cement that was injected depended on the size of the vertebral body and, if present, the size of the cleft. After the bone cement was set, the cannula was removed and the skin was sutured. The amount of cement used in each operation was recorded<sup>14,15</sup>.

After surgery, the patients had 24 hours of bed rest, and were mobilized by walking. Bisphosphonates, active vitamin D and calcium treatment was initiated for the patients who were not receiving any treatments for osteoporosis.



**Figure-1.** Vacuum cleft finding in L4 vertebra, classical finding in X-ray (black arrow). Application of vertebroplasty to a single pedicle where the whole cleft was filled with cement.



**Figure-2.** L1 X-ray showing a vacuum phenomenon in the vertebral body of a patient with Kümmel's Disease (Black arrow). The patient's STIR MRI image shows hyper-intense signals coming from the lesion at the same region. When the patient was laid in a prone position the local kyphosis disappeared, and vertebroplasty was applied to two pedicles in this position.

### CLINICAL EVALUATION:

For evaluation of the patients' pain, a visual analogous pain chart was used. In this method, the patient decides on the level of pain according to the figures on the chart, and a pain score corresponding to those figures on a scale from 1–10 is recorded (where 0 = no pain, and 10 = serious pain).

For functional evaluation, the Oswestry Disability Index version 2.0 was employed. The Oswestry Disability Index consists of ten sections, with six articles in each section that can be scored from 0 to 5 for each corresponding section. These sections were specified as level of pain, personal care, weight lifting, walking, sitting, standing, sleep, sexual life, social life and travel. In each section the scores from 0 to 5 are added together, divided by 50 and multiplied by 100 to calculate the final score of the patient<sup>16</sup>.

### RADIOLOGICAL EVALUATION:

Preoperatively, antero–posterior and lateral X-rays were used to calculate the wedging index

and local kyphosis angle, and the compression ratio and amount of collapse were evaluated. The local kyphosis angle was calculated using the Cobb method.

### STATISTICAL ANALYSIS:

Statistical analyses of the results were calculated using the Statistical Package for Social Sciences-16 (SPSS-16) program. For comparison of the preoperative and postoperative visual pain scale, Oswestry Disability Index and radiological measurements, a paired sample t-test and the Pearson correlation coefficient were used. In the paired sample t-test and Pearson correlation coefficient,  $p < 0.05$  was accepted as significant.

### RESULTS:

Eight of the 14 patients were diagnosed due to pain complaints together with the presence of a fluid-filled cavity seen in MRI STIR sagittal sections.

---

For the other six cases, a pain complaint was present, but the presence of an air-filled cleft (vacuum phenomenon) in the vertebral body seen by X-ray or computerized tomography images was sufficient.

At two of the 14 levels to which vertebroplasty was applied, the intervention was for both pedicles, but for 12 patients, bone cement injection to only one pedicle was found to be sufficient. The average amount of bone cement used was 4.5 ml (3–7 ml) (Table-1). The distribution of Kümmel's disease according to the spinal levels is shown in Table-1.

When the visual pain scores of the patients were evaluated, the preoperative average was 7, while at the first day postoperatively these were seen to be improved, with an average of 2.4.

At the final follow-up of the patients' visual pain score, the average was found to be 2.8. When the preoperative, first day postoperative, and final postoperative follow-up scores were compared, this improvement was found to be statistically significant ( $p < 0.05$ ) (Table-2).

The patients were functionally evaluated using the Oswestry Disability Index. In the preoperative evaluation, the Oswestry Disability Index average score was 66, postoperatively it was 35, and at the final follow-up it was 32. This improvement in the Oswestry Disability Index was found to be statistically significant ( $p < 0.05$ ) (Table-2).

Preoperative and postoperative radiological evaluation was made using lateral X-rays,

considering the local kyphosis angle, the wedging index and the compression ratio. In the group that received vertebroplasty, the average preoperative kyphosis angle was  $28^\circ$ , the average wedging index was 56 and the average compression ratio was 57%. Postoperatively, the average local kyphosis angle was  $22^\circ$ ,

the average wedging index was 66 and the average compression ratio was 60%. All three parameters for radiological evaluation were compared preoperatively and postoperatively, and the differences were not shown to be statistically significant ( $p > 0.05$ ) (Table-3).

There was a cement leak during surgery of one of the patients that received intervention in both pedicles at the right L2 level to the paravertebral region. In that patient, cement injection was continued at the left pedicle. This patient was asymptomatic in the postoperative period. There were no other local or systematic complications in other the cases.

## **DISCUSSION:**

At the time Herman Kümmel described this disease, X-rays were not in use for medical applications. At that time, Kümmel described the disease as an asymptomatic time period after which post-traumatic kyphosis could be observed, but the vacuum phenomena in the form of a cleft was not known, due to the absence of X-ray imaging. Later, Madalogue defined this characteristic radiological finding and correlated it with Kümmel's disease <sup>10,12,13</sup>.

**Table-1.** Level distribution in Kümmel's disease and average bone cement application amount.

Level	Number of cases	Average bone cement amount (ml)
T9	1	3
T10	2	3
T11	1	3
T12	2	3.5
L1	3	4.5
L2	2	4
L4	2	6
L5	1	5
<b>Total</b>	<b>14</b>	

**Table-2.** Clinical evaluation of the patients with the visual pain scale and Oswestry Disability Index.

	Preop	Postop	Final
Visual pain scale (Average)	7	2.1	2.6
Oswestry Disability Index (Average)	66	35	32
P<0.05			

**Table-3.** Radiological evaluation of the patients.

	Preop (SD)	Postop (SD)
Local kyphosis angle	28 (5)	22 (4)
Wedging index	56 (6)	60 (5)
Compression ratio (%)	57 (4)	60 (6)
p>0.05		

Armingeat et al., in their study of 278 cases of vertebral fractures, found 13 cases with a cleft-shaped vacuum phenomenon. From this point forward, Armingeat et al. proposed that gas accumulation in the disc space leaks to the vertebral body from the fractured plate<sup>1</sup>. However, Libicher et al. drew a different conclusion. In a multicenter study, all the vertebroplasty patients were biopsied and histopathologically evaluated. In 11 of the 12 patients, osteonecrosis was diagnosed

pathologically. However, 11 of the 13 patients that were diagnosed histopathologically had a vacuum phenomenon in the form of a cleft. As a result, they proposed that the presence of a vacuum phenomenon in the vertebral body shows high sensitivity and specificity for osteonecrosis<sup>10</sup>. This study is the only histology study in the literature, and, taking the results into account, we accepted vertebral osteonecrosis patients with a vacuum phenomenon as cases of Kümmel's disease.

---

The rate of Kümmel's disease in osteoporotic vertebral fractures in the literature is shown to be between 8% and 37%<sup>5,9,11</sup>. In our case study, this rate is 23.7%, which supports the hypothesis that Kümmel's disease is not as rare as previously thought.

Two prospective studies in 2009 proposed that the results from percutaneous vertebroplasty surgery were no different to the results from a sham procedure for osteoporotic vertebral fractures<sup>3,7</sup>. Later studies were published criticizing the amount of bone cement used in those studies, which was less than expected, and other problematic aspects<sup>2</sup>. In our study, there was no sham procedure cohort; however, in Kümmel's disease, the pain palliation through vertebroplasty depends on the reduction of motion of the non-union line caused by filling the cleft with polymethyl methacrylate<sup>8</sup>. Also, all of the cases included in our study had symptoms for at least three months and were chronic cases, while in both of the studies discussed here, acute cases were included<sup>3,7</sup>.

Our study shows that the preoperative pain is significantly decreased postoperatively, and the Oswestry Disability Index is also decreased. However, the sagittal contour of the vertebrae was not improved with this procedure.

In Kümmel's disease or post-traumatic osteonecrosis of the vertebrae, the pain symptoms decrease the quality of life of the patients. Percutaneous vertebroplasty could be a good option for the maintenance of pain palliation and for increasing the quality of life of the patients.

## REFERENCES:

1. Armingeat T, Pham T, Legre V, Lafforgue P. Coexistence of intravertebral vacuum and intradiscal vacuum. *Joint Bone Spine* 2006; 73: 428-432.
2. Boszczyk B. Volume matters: a review of procedural details of two randomised controlled vertebroplasty trials of 2009. *Eur Spine J* 2010 ; 19: 1837-1840.
3. Buchbinder R, Osborne RH, Ebeling PR, Wark JD, Mitchell P, Wriedt C, Graves S, Staples MP, Murphy B. A randomized trial of vertebroplasty for painful osteoporotic vertebral fractures. *N Engl J Med* 2009 ; 361:557-68.
4. Chou LH, Knight RQ. Idiopathic avascular necrosis of a vertebral body. Case report and literature review. *Spine* 1997; 22: 1928-1932.
5. Freedman BA, Heller JG. Kummell Disease: a not-so-rare complication of osteoporotic vertebral compression fractures. *J Am Board Fam Med* 2009; 22: 175-178.
6. Galibert P, Deramond H, Rosat P, Le Gars D. Preliminary note on the treatment of vertebral angioma by percutaneous acrylic vertebroplasty. *Neurochirurgie* 1987; 33(2): 166-168.
7. Kallmes DF, Comstock BA, Heagerty PJ, Turner JA, Wilson DJ, Diamond TH, Edwards R, Gray LA, Stout L, Owen S, Hollingworth W, Ghdoke B, Annesley-Williams DJ, Ralston SH, Jarvik JG. A randomized trial of vertebroplasty for osteoporotic spinal fractures. *N Engl J Med* 2009 ;361: 569-579.
8. Kawaguchi S, Horigome K, Yajima H, Oda T, Kii Y, Ida K, Yoshimoto M, Iba K, Takebayashi T, Yamashita T. Symptomatic relevance of intravertebral cleft in patients with osteoporotic vertebral fracture. *J Neurosurg Spine* 2010; 13: 267-275.

- 
9. Lane JI, Maus TP, Wald JT, Thielen KR, Bobra S, Luetmer PH. Intravertebral clefts opacified during vertebroplasty: pathogenesis, technical implications, and prognostic significance. *AJNR Am J Neuroradiol* 2002; 23: 1642-1646.
  10. Libicher M, Appelt A, Berger I, Baier M, Meeder PJ, Grafe I, Dafonseca K, Nöldge G, Kasperk C. The intravertebral vacuum phenomenon as specific sign of osteonecrosis in vertebral compression fractures: results from a radiological and histological study. *Eur Radiol* 2007; 17: 2248-2252.
  11. Maheshwari PR, Nagar AM, Prasad SS, Shah JR, Patkar DP. Avascular necrosis of spine: a rare appearance. *Spine* 2004; 29: E119-122.
  12. Maldague BE, Noel HM, Malghem JJ. The intravertebral vacuum cleft: a sign of ischemic vertebral collapse. *Radiology* 1978; 129: 23- 29.
  13. Malghem J, Maldague B, Labaisse MA, Doods G, Duprez T, Devogelaer JP, Vande Berg B. Intravertebral vacuum cleft: changes in content after supine positioning. *Radiology* 1993; 187: 483-487.
  14. Şenköylü A, Deveci MA, Ateş A, Altun N. Vertebroplasti vertebrografi ile yapıldığında daha güvenli. *J Turk Spinal Surg* 2009; 20: 53- 62.
  15. Şenköylü A. Perkütan vertebroplasti. *Türkiye Klinikleri J Orthop & Traumatol-Special Topics* 2008, 1(4): 83-87.
  16. Yakut E, Düger T, Öksüz Ç, Yörükan S. Validation of Turkish version of the Oswestry Disability Index for patients with low back pain. *Spine* 2004, 29(5): 581-585.
  17. Young WF, Brown D, Kendler A, Clements D. Delayed osteonecrosis of a vertebral body (Kummell's Disease). *Acta Orthop Belg* 2002; 68: 13-18.