



## THE THREE-ROD (TWO-ROD FOR CONCAVE) TECHNIQUE FOR THE TREATMENT OF SEVERE SCOLIOSIS AND KYPHOSCOLIOSIS

### AĞIR SKOLYOZ VE KİFOSKOLYOZLARIN TEDAVİSİNDE 3-ROD (KONKAVA 2-ROD) TEKNİĞİ

Yunus ATICI<sup>1</sup>,  
Onat ÜZÜMCÜGİL<sup>2</sup>,  
Murat MERT<sup>3</sup>,  
Sinan ERDOĞAN<sup>4</sup>,  
Engin ÇARKÇI<sup>4</sup>,  
Barış POLAT<sup>4</sup>,  
Mustafa CANIKLIOĞLU<sup>5</sup>

<sup>1</sup>Op. Dr., Orthopedics and Traumatology Specialist, S.B. Metin Sabancı Balta limanı Bone Diseases Training and Research Hospital, Orthopedics and Traumatology Clinics, Spinal Diseases Surgery and Prosthesis Surgery Group, İstanbul.

<sup>2</sup>Assoc. Prof. Dr., Orthopedics and Traumatology Specialist, S.B. İstanbul Training and Research Hospital, Orthopedics and Traumatology Clinics

<sup>3</sup>Op. Dr., Orthopedics and Traumatology Specialist, S.B. İstanbul Training and Research Hospital, Orthopedics and Traumatology Clinics

<sup>4</sup>Assistant Dr., S.B. İstanbul Training and Research Hospital, Orthopedics and Traumatology Clinics

<sup>5</sup>Prof. Dr., Orthopedics and Traumatology Specialist, Trakya University, Medical Services Vocational School.

Address: Dr. Yunus Atıcı, S.B. Metin Sabancı Baltalimanı Kemik Hastalıkları Eğitim ve Araştırma Hastanesi, Ortopedi ve Travmatoloji Kliniği, Baltalimanı-Sarıyer-İSTANBUL  
E-mail: yunaticici@hotmail.com  
Received: 1st April, 2012  
Accepted: 4th June, 2012

#### SUMMARY:

**Purpose:** The aim of this retrospective clinical trial was to evaluate the efficacy of a three-rod technique with a posterior approach in the surgical treatment of rigid spinal deformities, including scoliosis and kyphoscoliosis.

**Materials and Methods:** Between 2003 and 2009, ten patients with severe and rigid spinal deformities (five with scoliosis and five with kyphoscoliosis) that were treated surgically using a three-rod technique with a posterior approach and instrumentation were retrospectively evaluated. Of the ten patients, six were female and four were male. Seven patients were idiopathic and three had a congenital-originated deformity. The mean age at the time of surgery was 20.3 years old (range: 14–38). In a radiographic assessment, parameters including the Cobb angles of the curves, the sagittal and coronal balance measurements, the apical vertebral translation, the thoracic kyphosis with lumbar lordosis, and the correction that was both gained and lost were recorded in the preoperative, postoperative, and final follow-up periods.

During the procedure, the apex of the concavity of the main curve was firstly instrumented and distracted (first rod). Then, a second rod was inserted to the highest and

lowest vertebrae of the concavity, followed by derotation and distraction (second rod). A long third rod was then inserted to the convexity of the deformity (third rod).

**Results:** The mean follow-up was 48.8 months. The mean preoperative Cobb angle of the major thoracic curve was 102.6° (range: 67–132°), which improved to 56° (range: 26–96°) in the early postoperative period, and was measured as 58.1° (range: 27–98°) in the final follow-up. The mean initial correction was measured as 45.42%, and the final correction rate was 43.37%. The loss of correction at the end of the follow-up period was 2.05%. Two patients had sagittal and one had coronal decompensation as complications.

**Discussion:** The treatment of rigid and severe scoliosis or kyphoscoliosis is difficult. Rigid and severe spinal deformities can be treated with various osteotomies and posterior and/or anterior techniques. Based on our results, we suggest that a three-rod technique with a posterior approach may be an effective and safe mode of surgical treatment for the management of severe and rigid spinal deformities such as scoliosis and kyphoscoliosis.

**Key Words:** Three-rod technique, severe scoliosis, rigid, scoliosis, kyphoscoliosis, posterior instrumentation

**Level of Evidence:** Retrospective clinical trial, Level III

#### ÖZET:

**Amaç:** Bu çalışmanın amacı, posterior girişimle 3-rod tekniğinin rigid ve ağır deformitelerde güvenli ve yeterli düzelme sağlayarak tedavide ki başarısını geriye dönük olarak değerlendirmektir.

**Gereç ve Yöntem:** 2003-2009 yılları arasında ağır, rijit spinal deformiteli 10 hasta (5 hasta skolyoz, 5 hasta kifoskolyoz) 3-rod tekniği ile posterior enstrümantasyon uygulanarak ameliyat edildi. On hastanın 6'sı bayan, 4'ü erkek idi. 7 hasta idiopatik, 3 hasta konjenital kökenli deformite idi. Hastaların ameliyat sırasında ki ortalama yaşı 20,3 yaş (Aralık, 14-38) idi. Radyografide üç farklı zamanda (ameliyat öncesi, ameliyat sonrası, ileri takip dönemi) torakal ve lomber eğriliğinin Cobb açısı, koronal ve sagittal denge, apikal vertebra translasyonu parametreleri, torakal kifoz, lomber lordoz, deformitenin düzelme oranları, düzelme kayıpları ölçüldü. Posteriordan öncelikle ana eğriliğin tepe noktasının konkav tarafına 1. rod (kısa rod) yerleştirilip distraksiyon uygulandı. 2. rod (uzun rod) eğriliğin konkav tarafındaki üst-son ve alt-son vertebraları arasına yerleştirilip derotasyon ve distraksiyon uygulandı. 3. rod (uzun rod) ise eğriliğin konveks tarafına yerleştirildi.

**Sonuçlar:** Hastaların ortalama takip süresi 48,8 ay (Aralık, 18-98) idi. Hastaların ameliyat öncesi ana torakal eğriliğindeki ortalama Cobb açısı 102,6° (aralık, 67°-132°) iken ameliyat sonrası dönemde 56° (aralık, 26°-96°) olarak ölçüldü. Son takipteki ana torakal eğriliğin ortalama Cobb açısı 58,1° (aralık, 27°-98°) olarak belirlendi. Ameliyat sonrası ortalama düzelme %45,42 iken son takipteki düzelme oranı %43,37 olarak tespit edildi. İleri takip döneminde ortalama düzelme kaybı %2,05 olarak tespit edildi. İleri takip döneminde ise 1 hastada koronal dengede bozukluk devam ederken, 2 hastada sagittal dengede bozukluk tespit edildi. Hiçbir hastada klinik bir komplikasyon gelişmedi.

**Tartışma:** Rijit ve ağır skolyoz veya kifoskolyozların düzeltilmesi zordur. Çeşitli osteotomiler ve posterior ve/veya anterior tekniklerle rijit ve ağır spinal deformiteler tedavi edilebilir. Çalışmamız posterior girişimle 3-rod tekniğinin rijit ve ağır deformitelerin tedavisinde etkili ve güvenilir bir teknik olduğunu göstermektedir.

**Anahtar Kelimeler:** 3-rod tekniği, ağır ve rijit, skolyoz, kifoskolyoz, posterior enstrümantasyon

**Kanıt Düzeyi:** Retrospektif klinik çalışma, Düzey III

---

## INTRODUCTION:

Progressive curvatures without early surgical intervention turn to rigid and severe deformities over time. Then, cosmetic problems (rib hump deformities), lateral pain, cardiopulmonary problems and balance disorders of the body can develop<sup>14</sup>. Three critical phases (phase 1: placement of implants, phase 2: mobilization of the spine and chest wall, and phase 3: a correction strategy for the deformity) should be applied in order to be successful in the surgical treatment of severe and rigid deformities<sup>9</sup>. For the treatment of severe and rigid curvatures, combined surgical techniques can be used by including various posterior and/or anterior approaches and various osteotomies (wide facet resections from the posterior, posterior transpedicle osteotomy and partial or total vertebrectomy)<sup>15</sup>. New instrumentation systems and techniques make the treatment of this kind of deformity easier<sup>13</sup>. Although correction of severe and rigid spinal deformities using only a single technique is difficult, neurological complications need to be considered<sup>17</sup>. This study aims to contribute to the literature about the efficacy and safety of the technique by retrospectively evaluating the clinical and radiological results of patients that received posterior instrumentation with a three-rod technique for severe and rigid deformities.

## PATIENTS AND METHODS:

Ten patients with a severe and rigid spinal deformity (five with scoliosis and five with kyphoscoliosis) received surgical application of posterior instrumentation with a three-rod technique between 2003 and 2009. Six of the ten patients were female and four were male. Seven patients had idiopathic deformities and three had congenital-originated deformities. The mean

age was 20.3 years old at the time of surgery (range: 14–38). The patients were evaluated by an orthopedist, an internist, a pulmonologist and a dietitian. All patients were evaluated by taking standing antero–posterior, lateral, traction and bending orthoroentgenograms, and tomography and magnetic resonance of the whole vertebral column. In the antero–posterior radiographies, the type of curve, the Cobb angle of the thoracic and lumbar curve, the coronal balance and the apical vertebral translation were measured. In lateral radiography, the thoracic kyphosis, lumbar lordosis and sagittal balance were measured. The measured values were recorded at three different times (before and after surgery and at the end of the follow-up period) and the results were evaluated. The corrections gained and lost were also measured.

In antero–posterior radiography, the upper and lower vertebral limits of the thoracic and lumbar curves were defined. The sizes of the thoracic and lumbar curves were calculated with the Cobb method. By lateral radiography, the kyphosis angle and the angle between the upper end plate of the T5 vertebra and the lower end plate of the T12 vertebra were calculated with the Cobb method. The lordosis angle was defined by measuring the angle between the L1 vertebral upper last plate and the S1 vertebral upper last plate in lateral radiography.

The apical vertebral translation was calculated by measuring the distance between the apical vertebra or the midline of the disc and the middle sacral line in antero–posterior radiography. The apical vertebral translation was recorded in millimeters.

The coronal balance was calculated by measuring the distance between horizontal lines descending

---

from the midline of the C7 vertebra and drawn from the central vertical line. The sagittal balance was evaluated based on the relationship to a point at which a line drawn straight down the C7 vertebral body passes through the posterosuperior edge of the S1 vertebra. The coronal and sagittal balance were recorded in millimeters. All patients were laid face down under general anesthesia and they were operated on using a posterior midline cut.

Determination of the incision was performed by referencing the C7–T1 spinous projection and the intergluteal space. The choice of fusion level was performed by including neutral vertebrae proximally (vertebrae without rotation) and stable vertebrae distally (the distal vertebra divided in two by the middle sacral vertebra line in antero-posterior radiography, the distal vertebra divided in two by the corpus of the vertical line coming from the posterosuperior edge of the promontorium in lateral radiography), with the addition of structural deformities in both sagittal and coronal planes. If the distance between C7–CSVL (the central sacral vertebral line) in the coronal plane and the distance between the center of the C7 corpus and the posterosuperior edge of the promontorium of the sacrum was higher than 20 mm, this was evaluated as a balance disorder. In all cases, third-generation instrumentation systems were used. Between the fusion levels, hybrid (screw and hook) instrumentation was applied to five patients, and instrumentation of only a pedicle screw was applied to five patients. At the apex of the deformity, wide facet resection was applied to five patients, posterior pedicle removal osteotomy to five patients, and rib resection to two patients. During the procedure, the apex of the concavity of the main curve was

first instrumented and distracted (first rod). Then a second rod was inserted to the upper and lower vertebrae of the concavity, followed by derotation and distraction (second rod). A long third rod was then inserted to the convexity of the deformity (third rod). Transverse connectors were placed between the two long rods. In all cases, a cancellous allograft after decortication and an autograft taken from the spinous projections were used to provide posterolateral solid fusion. Halo–femoral traction before or during surgery and neuro-monitorization or a wake-up test during surgery were not applied.

In addition, blood loss, the length of the operation and the follow-up, and any complications that developed during or after surgery were noted.

## RESULTS:

The mean follow-up period was 48.8 months (range: 18–98). The mean blood loss during the operation was 1960 ml (range: 1300–3575) and the mean operation time was 342 minutes (range: 240–420).

The preoperative mean Cobb angle of the major thoracic curve was 102.6° (range: 67–132°), which improved to 56° (range: 26–96°) in the early postoperative period, and was measured as 58.1° (range: 27–98°) at the final follow-up. The mean initial correction was 45.42%, and the final correction rate was 43.37%. The loss of correction at the end of the follow-up period was 2.05% (Figure-1).

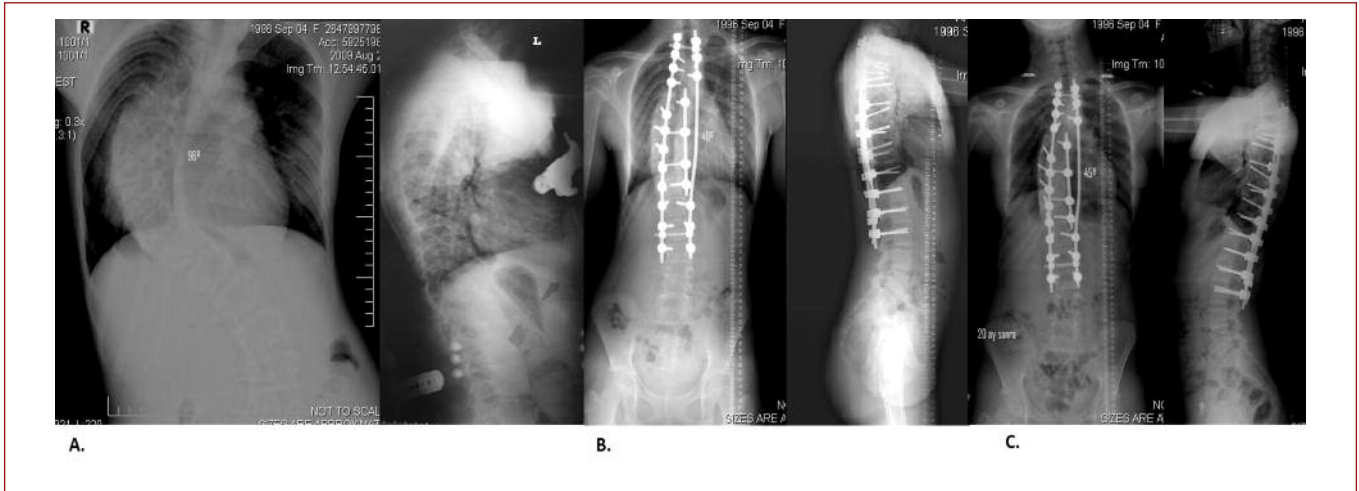
The preoperative mean Cobb angle of the lumbar curve was 43.6° (range: 25–55°), which improved to 6.2° (range: 0–37°) in the postoperative period, and was measured as 16.2° (range: 0–37°) at the final follow-up.

The mean correction after surgery was 62.84%, and it was 62.84% at the final follow-up. No loss of correction was found in the lumbar region.

(range: 14–80). The apical vertebral translation at the final follow-up was 36.44 mm (range: 10–80).

The preoperative apical vertebral translation of the thoracic curve was 86.22 mm (range: 61–115) and the postoperative value was 42 mm

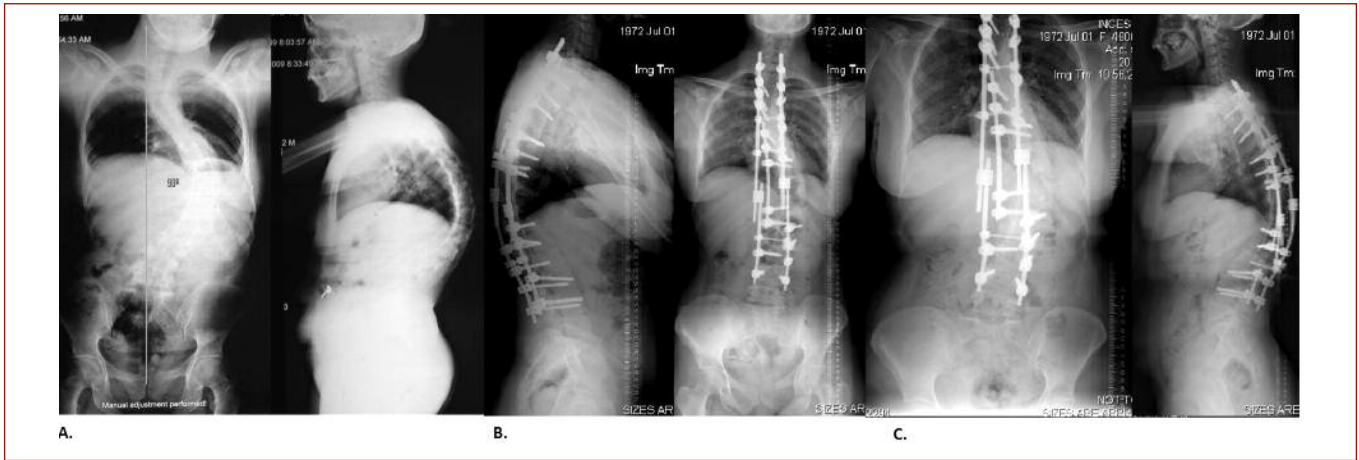
In this study, the preoperative mean coronal balance was 23.98 mm (range: 0–95), and this was 17.56 mm (range: 4–59) postoperatively.



**Figure-1.** Patient 1 **A.** antero-posterior and lateral X-ray before surgery **B.** antero-posterior and lateral X-ray after surgery **C.** antero-posterior and lateral X-ray after follow-up period.

**Table-1.** Demography of patients that received the three-rod technique

Patient	Implant	Age	Gender	Followup (months)	Scoliosis type	Fusion level	Risser	Blood amount	Op. time (min)
1	screw	14	F	20	Idiopathic	T2-L3	4	3575	420
2	hybrid	38	F	26	Idiopathic	T2-L4	5	1625	360
3	screw	24	M	47	Idiopathic	T2-L3	5	1625	380
4	screw	14	F	28	Idiopathic	T2-L4	3	1950	360
5	screw	20	M	18	Idiopathic	T2-L4	5	2925	300
6	hybrid	24	M	59	congenital	T2-L2	5	1350	330
7	hybrid	16	F	24	Idiopathic	T3-L5	5	1300	240
8	hybrid	18	M	84	congenital	T3-S1	5	1950	380
9	hybrid	18	F	98	congenital	T3-L3	5	1350	330
10	screw	17	F	84	idiopathic	T3-L3	5	1350	330



**Figure-2.** Patient 2 **A.** Antero-posterior and lateral X-ray before surgery **B.** Antero-posterior and lateral X-ray after surgery **C.** Antero-posterior and lateral X-ray after follow-up period.

The coronal balance was 16 mm (range: 4–59) at the final follow-up. The preoperative mean sagittal balance was 7.56 mm (range: 0–51), and the postoperative value was 16.78 mm (range: 0–30). The mean sagittal balance was 11.2 mm (range: 0–48) at the final follow-up (Figure-2).

While the preoperative mean kyphosis angle was 60.6° (range: 6–100°), it was postoperatively measured to be 37° (range: 5–76°) (38.94% correction). The mean kyphosis angle was 39.8° (range: 9–76°) (34.32% correction) at the final follow-up.

The preoperative mean lumbar lordosis angle was 55.1° (range: 31–68°) and postoperatively it was 53.4° (range: 25–73°). The mean lumbar lordosis angle was 54° (range: 28–65°) at the final follow-up.

While there were coronal and sagittal balance disorders in five and three patients, respectively, before surgery, there was a coronal balance disorder in one patient and a sagittal balance disorder in one patient after surgery.

While a coronal balance disorder was still present in one patient at the final follow-up, a

sagittal balance disorder was detected in two patients at this time.

There were no major complications such as external or deep infection, neurological complications, cardiopulmonary complications and pseudoarthrosis in any of the patients.

## DISCUSSION:

The treatment of rigid and severe scoliosis or kyphoscoliosis is difficult. However, surgical treatment of these deformities provides cosmetic, self-confidence and cardiopulmonary benefits<sup>9</sup>. If we perform an approach only from the posterior, we can contribute to the correction of deformity using combinations of techniques such as halo traction, wide facet resection, transpedicle osteotomy, partial vertebrectomy and 360° osteotomy. The tolerance of the spinal cord to distraction is low when correcting rigid and severe scoliosis, and the neurological complication risk is higher if too much correction is performed<sup>10,12,17</sup>. Although osteotomy is useful for the correction of deformity, it causes some complications (neurological deficit, significant blood loss, pulmonary problems)<sup>9</sup>.

---

In our study, the treatment of patients with severe and rigid scoliosis or kyphoscoliosis was performed in two phases in a single session from the posterior. First, distraction was applied to the concave of the apex of the curve with a short rod, and then correction was performed with derotation and distraction with long rods. Improvement was obtained in a ratio similar to other studies in the last follow-up of our patients (the correction rate of major thoracic scoliosis was 43.37% and the correction rate of thoracic kyphosis was 34.32%), and there were no major complications in any of the patients. An important feature of this technique is that the patient does not require a second session of surgery.

Vialle et al. applied fusion with posterior instrumentation to ten of 18 patients using the three-rod technique, and they used a two-rod technique for eight patients with concave curvatures after halo-traction, and they did not encounter any major complications. They stated that they obtained 32% correction after surgery, and the coronal balance reverted to normal for all the patients, although 12 patients had had coronal imbalance before surgery<sup>15</sup>.

Suk et al. reported that they obtained 59.3% correction for 16 patients with severe scoliosis that were treated with posterior vertebral resection, and major complications (neurological deficit in one patient, 6.3%) developed in four patients (32%)<sup>10</sup>. In other studies where osteotomy was applied, it has been reported that the neurological deficit rates were 9.5%, 16.6%, and 30.8%, in the studies by Yamin<sup>17</sup>, Bradford<sup>2</sup>, and Berven<sup>1</sup>, respectively. These results show that osteotomy should be performed carefully in severe and rigid spinal deformities.

Anterior release is a technique applied by the removal of discs at the apex of the curve, in order to increase the flexibility of the curve. This is an invasive procedure, and its necessity has been questioned, as it can cause cardiopulmonary limitations<sup>11</sup>.

They obtained significant correction with this technique (59.7%). However, they also reported that they encountered important major complications in this study<sup>12</sup>.

Hamzaoglu<sup>5</sup> et al. applied wide facet resection and posterior instrumentation with halo-femoral traction during surgery on 15 patients with severe and rigid scoliosis or kyphoscoliosis. They stated that no complications related to the halo-femoral traction developed during surgery, and they obtained 51% correction. However, the use of halo-traction is not suitable for all patients (those with cervical instability, intra-spinal pathologies etc.) and can cause complications in long-term preoperative use<sup>7,8,16</sup>.

Buchowski et al. tried a different approach to a posterior approach for ten patients with severe scoliosis. In a first session, they applied distraction by placing a temporary internal rod after posterior and/or anterior release. In a second session, they applied permanent fusion with instrumentation after approximately 2.4 weeks.

In the second session, four patients did not receive distraction. They reported that they provided 80% correction of scoliotic deformity and encountered no neurological complications or infections<sup>3,4</sup>. This technique appears to be a successful method for the correction of spinal deformity.

---

However, as it is a two-phase surgery requiring the application of an anterior approach in some cases, we cannot ignore the complications that may occur.

Tan et al. operated on 15 patients with severe spinal deformities using a two-phase posterior approach. In the first phase, distraction was applied to the concave part with two rods, and then correction using posterior instrumentation with wide facet resection or pedicle removal, osteotomy and thoracoplasty was applied in the second phase, after 3–6 months.

Different techniques, as described above, can be used for the correction of severe and rigid deformities. The use of these techniques in severe and rigid deformities was described as a pyramid in an article by Sucato. For the correction of spinal deformities, the interspinous ligaments and ligamentum flavum should first be relaxed, and then wide facet resection, anterior release and costa resection, pedicle removal osteotomy, vertebral body decancellation and vertebral column resection should be performed, in order<sup>9</sup>. In short, the main aim of surgical treatment for scoliosis is to leave the maximum spinal segment, while providing safe and balanced correction and minimum fusion, without any major complications<sup>6</sup>.

The best treatment for patients with severe and rigid spinal deformities is treatment performed in the early periods before the progression of deformity. It seems that techniques presented in the literature only provide partial correction.

Deformities that can be corrected with many osteotomies were successfully treated with the three-rod technique in our study without any complications. For further clarification, more

comparative studies with a greater number and longer follow-up periods of patients are required.

In conclusion, it is shown here that the three-rod technique applied with a posterior approach is an effective and safe method for the treatment of rigid and severe spinal deformities.

## REFERENCES:

1. Berven SH, Deviren V, Smith JA, Emami A, Hu SS, Bradford DS. Management of fixed sagittal plane deformity: results of the transpedicle wedge resection osteotomy. *Spine* 2001; 26: 2036-2043.
2. Bradford DS, Tribus CB. Vertebral column resection for the treatment of rigid coronal decompensation. *Spine* 1997; 22: 1590-1599.
3. Buchowski JM, Bhatnagar R, Skaggs DL, Sponseller PD. Temporary internal distraction as an aid to correction of severe scoliosis. *J Bone Joint Surg* 2006; 88-A(9): 2035-2041.
4. Buchowski JM, Skaggs DL, Sponseller PD. Temporary internal distraction as an aid to correction of severe scoliosis. Surgical technique. *J Bone Joint Surg* 2007; 89-A (Suppl 2 Pt.2): 297-309.
5. Hamzaoglu A, Ozturk C, Aydogan M, Tezer M, Aksu N, Bruno MB. Posterior only pedicle screw instrumentation with intraoperative halo-femoral traction in the surgical treatment of severe scoliosis (>100 degrees). *Spine* 2008; 33: 979-983.
6. Lenke LG, Betz RR, Harms J, Bridwell KH, Clements DH, Lowe TG, Blanke K. Adolescent idiopathic scoliosis: a new classification to determine extent of spinal arthrodesis. *J Bone Joint Surg* 2001; 83-A (8): 1169-1181.
7. Ransford AO, Manning CW. Complications of halo-pelvic distraction for scoliosis. *J Bone Joint Surg* 1975; 57-B: 131-137.

- 
8. Sink EL, Karol LA, Sanders J, Birch JG, Johnston CE, Herring JA. Efficacy of perioperative halo-gravity traction in the treatment of severe scoliosis in children. *J Pediatr Orthop* 2001; 21: 519-524.
  9. Sucato DJ. Management of severe spinal deformity: scoliosis and kyphosis. Review. *Spine* 2010; 35(25): 2186-2192.
  10. Suk SI, Chung ER, Kim JH, Kim SS, Lee JS, Choi WK. Posterior vertebral column resection for severe rigid scoliosis. *Spine* 2005; 30(14): 1682-1687.
  11. Suk SI, Kim JH, Cho KJ, Kim SS, Lee JJ, Han YT. Is anterior release necessary in severe scoliosis treated by posterior segmental pedicle screw fixation? *Eur Spine J* 2007; 16: 1359-1365.
  12. Tan R, Ma HS, Zou DW, Wu JG, Chen ZM, Zhou XF, Zhou JW. Surgical treatment of severe scoliosis and kyphoscoliosis by stages. *Chin Med J* 2012; 125(1): 81-86.
  13. Wu ZK, Ye QB, Wang YP. Surgical treatment of severe scoliosis (above 100 degrees Cobb) [in Chinese]. *Zhonghua Wai Ke Za Zhi* 1988; 26(3): 132-135, 189.
  14. Vedantam R, Lenke LG, Bridwell KH, Haas J, Linville DA. A prospective evaluation of pulmonary function in patients with adolescent idiopathic scoliosis relative to the surgical approach used for spinal arthrodesis. *Spine* 2000; 25(1): 82-90.
  15. Vialle R, Mary P, Harding I, Tassin JL, Guillaumat M. Surgical treatment of severe thoracic scoliosis in skeletally mature patients. *Orthopedics* 2008; 31(3): 218.
  16. Victor DI, Bresnan MJ, Keller RB. Brain abscess complicating the use of halo-traction. *J Bone Joint Surg* 1973; 55-A: 635-639.
  17. Yamin S, Li L, Xing W, Tianjun G, Yupeng Z. Staged surgical treatment for severe and rigid scoliosis. *J Orthop Surg Res* 2008; 3: 26.