



## PYOGENIC SACROILIITIS

### PIYOJENİK SAKROİLEİT

İbrahim KAYA<sup>1</sup>,  
Akın UĞRAŞ<sup>2</sup>,  
İbrahim SUNGUR<sup>1</sup>,  
Musa KORKMAZ<sup>1</sup>,  
Ercan ÇETİNUS<sup>2</sup>

<sup>1</sup>Op Dr, Orthopedic and  
Traumatology Specialist, Haseki  
Training and Research Hospital,  
Orthopedic and Traumatology  
Clinic

<sup>2</sup>Assoc Prof, Orthopedic and  
Traumatology Specialist, Haseki  
Training and Research Hospital,  
Orthopedic and Traumatology  
Clinic

**Address:** Akın Uğraş,  
Haseki Training and Research  
Hospital, Orthopedic and  
Traumatology Clinic,  
Adnan Adıvar cad, 34073,  
Fatih, İstanbul.  
**Tel:** 0212 5294400-1346  
**Gsm:** 0532 6321844  
**E-mail:** akinugras@gmail.com  
**Received:** 20th November, 2012  
**Accepted:** 12th December, 2012

#### SUMMARY

**Purpose:** To evaluate the treatment and follow-up results of bacterial sacroiliitis cases, which are rare and hard to diagnose.

**Patients and Methods:** Five sacroiliitis cases were evaluated, consisting of three female and two male patients with a mean age of 56 years. One patient had pulmonary sarcoidosis and one had diabetes mellitus. Preoperative and postoperative X-rays, magnetic resonance imaging and test results were examined.

**Results:** The mean follow-up time was 22 months. Preoperative biopsies were performed for two patients. The preoperative mean leukocyte count was 9120 units/ $\mu$ L, the mean C-reactive protein level was 35.71 mg/dL, and the mean sedimentation rate was 83.2 mm/sc. One patient received a two-stage debridement procedure, in which antibiotic cement was used in the initial stage. One-stage debridement was performed for the other cases. The organism responsible for the sacroiliitis was defined as *Mycobacterium tuberculosis* in one case, *Staphylococcus aureus* in two cases, and in the other two cases the organism could not be defined. At the last follow-up, the mean Majeed score was 83.4.

**Conclusion:** Hip pain, antalgic gait and fever are important symptoms in the diagnosis of sacroiliac joint infections, which are difficult to identify. The most frequent organism responsible for sacroiliitis was shown to be *Staphylococcus aureus*. Tuberculosis must be kept in mind when sacroiliitis is suspected.

**Key Words:** Sacroiliac joint, pyogenic sacroiliitis, tuberculosis

**Level of evidence:** Case series, Level IV

#### ÖZET

**Amaç:** Sık rastlanmayan ve tanısı zor konulan bakteriyel sakroileit olgularının tedavi ve takip sonuçları irdelendi. Hastalar ve Yöntem: Ortalama yaşı 56 olan üçü bayan ikisi erkek beş sakroileit olgusu değerlendirildi. Hastalardan biri pulmoner sarkoidoz, biri diabetes mellitus hastasıydı. Ameliyat öncesi ve sonrası direkt radyografi, manyetik rezonans görüntüleme ve laboratuvar sonuçları incelendi.

**Sonuçlar:** Ortalama takip süresi 22 ay olan hastaların ikisine ameliyat öncesi biyopsi yapıldı. Ortalama ameliyat öncesi lökosit 9120 adet/ $\mu$ L, C-Reaktif protein düzeyi 35.71mg/dL, sedimantasyon hızı 83.2 mm/sa olarak saptandı. Bir hastaya antibiyotikli çimento konularak iki aşamalı, diğer olgulara tek aşamalı debridman yapıldı. Bir olguda etken ajan olarak *Mycobacterium tuberculosis*, iki olguda *Staphylococcus aureus* saptanırken diğer iki olguda etken üretilmedi. Olguların son takiplerinde ortalama Majeed skoru 83.4 saptandı.

**Sonuç:** Tanısı zor olan sakroiliak eklem enfeksiyonlarında kalçada ağrı, topallama ve ateş tanı konulmasında önemlidir. En sık etken olarak *Staphylococcus aureus* saptanmıştır. Sakroileitisten şüphe edildiğinde, tüberküloz akıldan çıkarılmamalıdır.

**Anahtar kelimeler:** sakroiliak eklem, piyojen sakroileit, tüberküloz

**Kanıt düzeyi:** Olgu serisi, Level IV

## INTRODUCTION

Bacterial sacroiliitis represents 1–2% of all septic arthritis cases<sup>1,2</sup>. Generally, signs of the disease are non-specific, and diagnosis is difficult and occurs late as it can mimic sciatica, acute abdomen and sepsis. This can result in destruction of the joint, formation of sequestration, various disabilities, and even death<sup>1-3</sup>. Early diagnosis is important in terms of preventing these complications.

In this study, we have examined the detection of cases of pyogenic sacroiliitis that we diagnosed and treated, and the clinical and radiological results.

## PATIENTS AND METHODS

In our clinic, five patients who were admitted due to pain radiating to the hip, limping and fever, and who were treated and followed up, were evaluated. Two patients were male and three patients were female. Three patients had symptoms on the right, and two on the left.

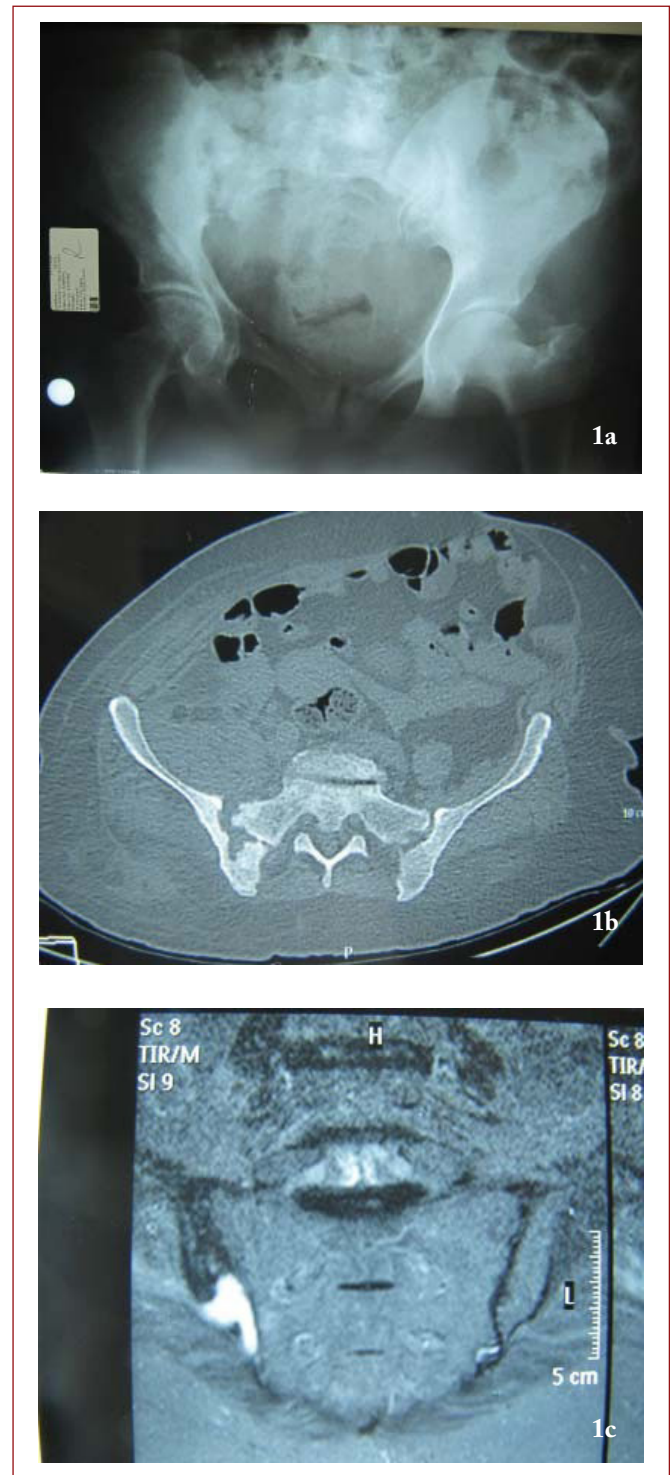
The mean age was 56 31–80 years and the mean follow-up was 22 months. The patients were evaluated with careful history, physical examination, radiographs, computed tomography, magnetic resonance imaging (MRI) (Figure-1), and laboratory findings, and the Majeed score was evaluated at the last follow-up<sup>4</sup>. In this scoring, patient functions are scored according to pain, standing, sitting, sexual function and work performance, and the total score is graded out of 100 and grouped into one of four groups: excellent, good, fair, or bad<sup>4</sup>.

## FINDINGS

In the biochemical examination of the patients with hip pain when walking, limping and fever, the mean leucocyte value was 9120 (7400–12900) units/ $\mu$ L, the mean C-reactive protein (CRP) value was 35.71 (5.05–75.2) mg/dl, and the mean sedimentation rate was 83.2 (69–97) mm/h. One patient had sarcoidosis with cortisone treatment and another patient had diabetes mellitus. Biopsy before surgery was applied to two patients. Surgical debridement was performed for all cases. After specific and non-specific cultures of the obtained debris, *Mycobacterium tuberculosis* was detected in one patient, *Staphylococcus aureus* was detected in two cases, and the organism could not be defined in two cases. A cement spacer saturated with antibiotic was placed in one case and removed after one month. Antibiotherapy was applied for one year to the case with tuberculosis, and for one month to the other cases. At the last follow-up, the mean Majeed score was 83.4 (64–99), and evaluated to be excellent.

## DISCUSSION

The early diagnosis of rarely-seen septic sacroiliitis is difficult, as it is commonly confused with diseases with complaints occurring in adjacent anatomical regions<sup>5,6</sup>.



**Figure-1.** (a) Direct radiograph (b) computerized tomography image and (c) magnetic resonance imaging of a case with sacroiliitis.

Anatomically, it progresses by crossing the superior gluteal and obturator nerve sacroiliac joint, and if hip joint pain, flexion deformity in the hip, and anterior capsule rupture are observed, peritoneal irritation can occur<sup>5,7</sup>. In a study by Wu et al. in which 11 children and 22 adults with pyogenic sacroiliitis were compared, symptoms including fever, lower back pain and no pressure on that side of the extremity were detected in 63.6% of adults (81.8% in children). This study stated that CRP was more sensitive than the number of leucocytes<sup>1</sup>.

Males are more frequently affected<sup>1,8</sup>. However, three of our patients were female and two were male. Generally, infection occurs due to the distribution of infection found in the adjacent bone and soft tissues, less frequently by a hematogenous route<sup>5,9</sup>. There was no adjacent tissue infection in any cases.

### Pyogenic Sacroiliitis

Generally, predisposing factors such as trauma, pregnancy, the use of intravenous drugs and diseases related to other organs are present<sup>5,10</sup>. In our study, pulmonary sarcoidosis treated with cortisone was present in one case and Type 2 diabetes mellitus in one case. Gluteal abscess, ilium osteomyelitis, sciatica, retroperitoneal abscess, tumors destructing this region, and ankylosing spondylitis in particular, should be considered for a differential diagnosis.

In septic sacroiliitis cases, the most common factor is *Staphylococcus aureus*. In some patients using intravenous drugs, *Pseudomonas aeruginosa* can be commonly seen<sup>11,12</sup>. While *Staphylococcus aureus* was detected in two cases, there was no bacterial growth in two other cases. 10% of all musculoskeletal tuberculosis adheres to the sacroiliac joint<sup>13,14</sup>. The patient in this study with tuberculosis sacroiliitis did not have lung tuberculosis.

In the early period, it is important to look for turbidity in the sacroiliac joint in direct radiographs, followed by joint destruction by computerized tomography in the later period, and abscess formation by MRI<sup>15</sup>. In all cases included in this study, we detected joint destruction and abscess formation in the examinations. Leucocyte, CRP and sedimentation are not specific, but they are important for tracking the disease<sup>11</sup>.

A tuberculin test of more than 15 mm in tuberculosis cases and a PCR test performed using a joint sample show high sensitivity<sup>15</sup>. It is easy to take a sample by sacroiliac joint puncture, although it is a difficult technique. However, it is easy to grow bacteria from a joint sample taken using aspiration after injection of 3–4 ml of serum to the joint under CT<sup>1,16</sup>.

The primary treatment is antibiotherapy against the bacteria. In one study, infection reduced in MRI controls after treatment and disappeared 59–149 days after the start of edema treatments of the bone marrow<sup>5</sup>. Surgical debridement is applied to patients who show no response to treatment and have an abscess<sup>1</sup>. In a pediatric patient group with eight cases, Akifusa reported that all of the patients showed a response to parenteral antibiotherapy, and there was no need for a surgical approach<sup>5</sup>.

In conclusion, sacroiliac joint infections should be considered in patients admitted due to hip pain, limping and fever. Although the most common causative agent is *Staphylococcus aureus*, tuberculosis arthritis should be also kept in mind.

### REFERENCES

1. Wu MS, Chang SS, Lee SH, Lee CC. Pyogenic sacroiliitis: a comparison between paediatric and adult patients. *Rheumatology* 2007; 46(11): 1684-1687.
2. Hodgson BF. Pyogenic sacroiliac joint infection. *Clin Orthop Relat Res* 1989; 246: 146-149.
3. Cohn SM, Schoetz DJ Jr. Pyogenic sacroiliitis: another imitator of the acute abdomen. *Surgery* 1986; 100(1): 95-98.
4. Majeed SA. Grading the outcome of pelvic fractures. *J Bone Joint Surg* 1989; 71-B(2): 304-306.
5. Wada A, Takamura K, Fujii T, Yanagida H, Surijamorn P. Septic sacroiliitis in children. *J Pediatr Orthop* 2008; 28(4): 488-492.
6. Doita M, Yoshiya S, Nabeshima Y, Tanase Y, Nishida K, Miyamoto H, Watanabe Y, Kurosaka M. Acute pyogenic sacroiliitis without predisposing conditions. *Spine* 2003; 28(18): E384-389.
7. Sandrasegaran K, Saifuddin A, Coral A, Butt WP. Magnetic resonance imaging of septic sacroiliitis. *Skeletal Radiol* 1994; 23(4): 289-292.
8. Abbott GT, Carty H. Pyogenic sacroiliitis, the misdiagnosis? *Br J Radiol* 1993; 66(782): 120-122.
9. Stürzenbecher A, Braun J, Paris S, Biedermann T, Hamm B, Bollow M. MR imaging of septic sacroiliitis. *Skeletal Radiol* 2000; 29(8): 439-446.
10. Klein MA, Winalski CS, Wax MR, Piwnicka-Worms DR. MR imaging of septic sacroiliitis. *J Comput Assist Tomogr* 1991; 15(1): 126-132.
11. Asavamongkolkul A, Keerasuntonpong A, Kuagoolwongse C. Pyogenic sacroiliitis and adult respiratory distress syndrome: a case report. *J Orthop Surg (Hong Kong)* 2007; 15(2): 226-229.

- 
12. Gordon G, Kabins SA. Pyogenic sacroiliitis. *Am J Med* 1980; 69(1): 50-56.
  13. Ramlakan RJ, Govender S. Sacroiliac joint tuberculosis. *Int Orthop* 2007; 31(1): 121-124.
  14. Babhulkar SS. Editorial comment [Report]. *Clin Orthop Relat Res* 2002; 398: 1-3.
  15. Keleş I, Aydın G, Kitay OL, Orkun S. Tuberculous sacroiliitis: a case report. *Rheumatol Int* 2004; 24(5): 312-314.
  16. Delbarre F, Rondier J, Delrieu F, Evrard J, Cayla J, Menkes CJ, Amor B. Pyogenic infection of the sacroiliac joint. Report of thirteen cases. *J Bone Joint Surg* 1975; 57-A (6): 819-825.