



VERTEBRAL HYDATID DISEASE AND ITS TREATMENT BY ANTERIOR-POSTERIOR RADICAL EXCISION, FUSION AND CHEMOTHERAPY WITH ALBENDAZOLE: CASE REPORT AND RESULTS OF AN ELEVEN YEAR FOLLOW-UP.

OMURGA KİST HİDATİĞİ VE ALBENDEZOL, ANTEROR VE POSTERİOR RADİKAL EKŞİZYON VE FÜZYON İLE TEDAVİSİ: OLGU SUNUMU VE 11 YILLIK TAKİP SONUÇLARI

Mehmet Nuri ERDEM¹,
Cem SEVER²,
Mehmet Fatih
KORKMAZ³,
İsmail OLTULU⁴,
Erkan GÜRGEN⁵,
Mehmet TEZER⁶

¹MD, Department of Orthopaedic Surgery, Şişli International Kolan Hospital, Istanbul

²MD, Department of Orthopaedic Surgery, Mevlana University, School of Medicine, Konya

³MD, Department of Orthopaedic Surgery, İnönü University, School of Medicine, Malatya

⁴MD, Department of Orthopaedic Surgery, Medipol University, School of Medicine, Istanbul

⁵MD, Department of Neurosurgery, Şişli International Kolan Hospital, Istanbul.

⁶Prof., MD, Department of Orthopaedic Surgery, Şişli International Kolan Hospital, Istanbul

Address: Mehmet Nuri Erdem,
Şişli International Kolan Hastanesi
Ortopedi ve Trav.
Darülaceze Cad. Gönen Sok. Şişli
İstanbul

Tel.: 0533 2215938

E-mail: mnerdem@yandex.com

Received: 4th July, 2013

Accepted: 14th September, 2013

SUMMARY

A hydatid cyst is a zoonosis caused by the larval form of the parasitic tapeworm *Echinococcus granulosus*. Here, we present a case of a vertebral hydatid cyst with paravertebral abscesses, operated 11 years ago. A 32-year-old woman presented with multiple giant paravertebral abscesses at the level of the T11–12 and L1 vertebrae, and a pathological fracture of the L1 vertebra, because of a vertebral hydatid cyst. Posterior instrumentation and fusion followed by anterior L1 corpectomy and fusion were carried out. The patient was pain-free after eleven years of follow-up. There was no radiological evidence of relapse. Hydatid disease of the spine is rare, and misdiagnosis, resulting in inadequate treatment and recurrence, is frequent. Maintaining the stability of the spine and achieving a fusion mass is important when deciding on a surgical technique for vertebral-type hydatidosis.

Key words: *Echinococcus granulosus*, hydatid cyst, corpectomy, anterior fusion.

Level of evidence: Case report, Level IV.

ÖZET

Hidatit kist *Echinococcus granulosus*'un larva formu ile oluşan bir zoonozdur. Bu çalışmada 11 yıl önce paravertebral apse ile birlikte vertebral hidatit kist nedeni ile ameliyat edilen olgu sunulmuştur. 32 yaşındaki kadın hastada T11-T12 ve L1 seviyelerinde yaygın paravertebral apse, L1 seviyesinde vertebral hidatit kiste bağlı patolojik kırık saptandı. Posterior enstrümantasyon ve füzyon, anterior L1 korpektomi ve füzyon uygulandı. Bir yıl sonraki kontrolde hastanın semptomları tamamen düzelmisti. Radyolojik tetkiklerde apse nüksü görülmedi. Oldukça nadir rastlanan vertebra kist hidatiği tanısı ve tedavisi zor bir enfestasyondur. Nüks ihtimali oldukça yüksektir. Omurganın stabilitesinin temin edilmesi ve füzyon kitesinin elde edilmesi vertebral hidatidozun cerrahi tedavi kararında oldukça önemlidir.

Anahtar Kelimeler: Ekinokokus granüloz, hidatit kist, korpektomi, anterior füzyon.

Kanıt Düzey: Olgu sunumu, Düzey IV.

INTRODUCTION:

A hydatid cyst is a zoonosis caused by the larval form of the parasitic tapeworm *Echinococcus granulosus*⁵. *E. granulosus* mostly involves the liver (50–60%) and lungs (20–30%); however, any organ in the body can be involved (10%)⁷. Hydatid cysts of the bone represent 1% of all cases, and 50% of these involve the vertebrae. They are most commonly localized to the thoracic spine and then, in decreasing order of frequency, to the lumbar, sacral, and cervical spine^{6,9}. Diagnosis and treatment of this rare disease is difficult. The patient history, echinococcal agglutination test, and MRI are important for diagnosis. Management of vertebral hydatid disease is much more difficult than for soft tissues. It has a very high rate of recurrence due to the difficulty of radical excision. We present a case of a vertebral hydatid cyst with paravertebral abscesses operated on 11 years previously with anterior corpectomy, total laminectomy, and posterior instrumentation.

CASE REPORT:

A 32-year-old woman presented with back and lower back pain in September 2000. She had had surgery three years previously in 1997 in another hospital, when partial laminectomy was applied on diagnosis of a hydatid cyst. Neurological examination, routine laboratory investigations and chest radiography findings were normal. Severe pain was the major complaint.

Recurrence of previous lesions was detected in the laminectomized site and the surrounding posterior soft tissue. The patient had multiple giant paravertebral abscesses at the level of the T11–12 and L1 vertebrae, and a pathological fracture of the L1 vertebra (Figure-1.a-b).

Total laminectomy, posterior instrumentation and posterolateral fusion, followed by an anterior approach with left thoracotomy, paravertebral abscess drainage and decompressive L1 corpectomy, were carried out.

Fibular and costal bone grafts were used for anterior fusion. In another session, right thoracotomy was carried out and the other paravertebral abscess was excised. The patient had intermittent albendazole medication for six months (Figure-2).

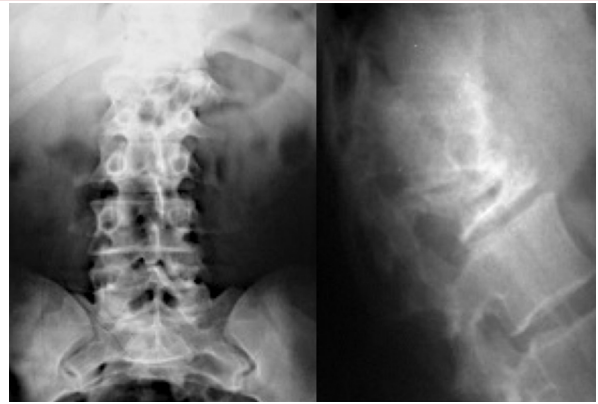


Figure-1.a. Preoperative radiographies showing pathological fracture of L1 vertebra

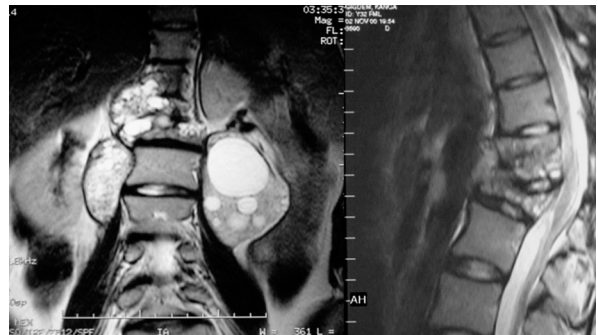

Figure-1.b. Preoperative MRI showing multiple giant paravertebral abscesses at the level of the T11–12 and L1 vertebrae.

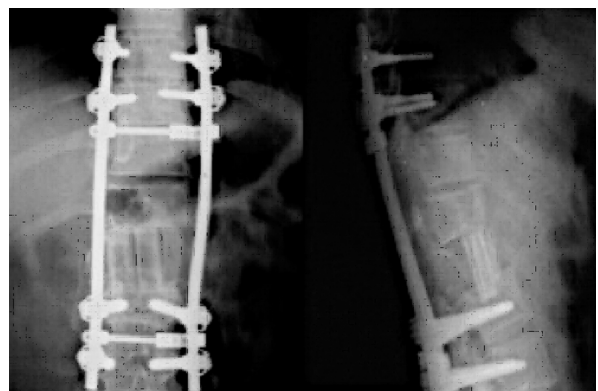


Figure-2. Early postoperative AP and lateral radiographies.

The patient was pain-free at the eleven year follow-up. There was no sagittal-frontal plain imbalance (Figure-3). Bone fusion was achieved antero-posteriorly. There was no radiological evidence of relapse.

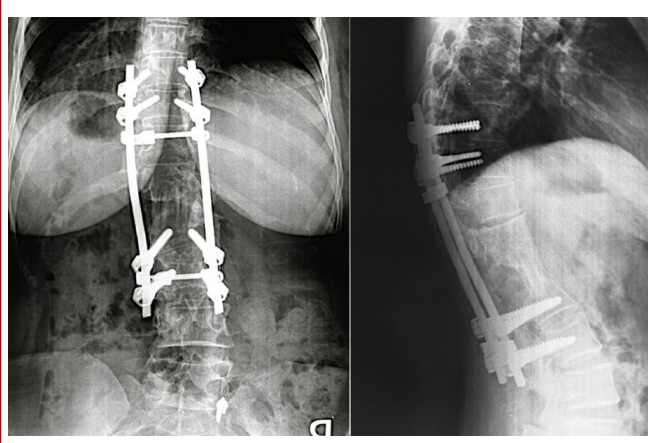


Figure-3. Radiographies after eleven years of follow-up showing fusion and maintenance of both sagittal and frontal balance without recurrence.

DISCUSSION:

Cystic hydatid disease is generally caused by a parasitic tapeworm, *Echinococcus granulosus*. Dogs are the definitive hosts, and humans become infected on ingesting eggs that are excreted by dogs. The liver and the lungs are involved in approximately 90% of cases, whereas bone involvement has been reported in only 0.5–4% of cases. Spinal involvement in hydatid disease is the result of portovertebral shunts. It usually starts in the vertebral body and grows slowly because of the resistant nature of bone. There are no pathognomonic signs or symptoms of spinal hydatid disease, other than symptoms related to compression^{1,6,8-9}. Generally, the first symptoms are backache and radicular pain⁶. Weakness of the limbs occurs in the later phase of the disease. Paraplegia, the most serious complication of the disease, is caused by compression of the spinal cord by the cysts. In our case, the initial symptoms were severe back and lower back pain with no neurological deficit.

Spinal involvement is seen in 50% of osseous cases. The thoracic and lumbar spine are involved in 75% of cases, and neurological deficit has been reported to occur in 25–84% of cases^{3,6}. Spinal involvement has been classified by Braithwaite and Lees³ into five types: 1) primary intramedullary hydatid cyst; 2) intradural extramedullary hydatid cyst; 3) extradural intraspinal hydatid cyst; 4) hydatid disease of the vertebrae; and 5)

paravertebral hydatid disease. With regard to prognosis, the condition has a reported mortality rate of 50%². Multiple vertebral involvements are unusual.

Diagnosis is usually difficult, and often is not made until the clinical signs and symptoms of spinal cord or nerve compression appear. Even then, spinal hydatidosis is often misdiagnosed. Accurate diagnosis can be confirmed by eosinophilia and by positive results of a complement fixation test, a Casoni skin test, and an enzyme-linked immunoassay. MRI characteristically shows an image resembling a bunch of grapes. The cyst walls are thin and regular, with no septation. The presence of a markedly hypointense cyst wall on T1-weighted and T2-weighted images, and the absence of wall enhancement with gadolinium, are characteristic of hydatid disease. In the present case, MRI showed severe bone destruction, kyphotic deformity, and multiple giant paravertebral abscesses with characteristic signals at the three affected levels.

Differential diagnoses include tuberculosis, mycoses, pyogenic abscesses, and benign or malignant neoplasm of the spine. A missed diagnosis is frequent, and can be devastating due to high mortality and morbidity⁴. The treatment of choice is total surgical removal of the cysts without perforation of the cyst wall, and anti-helminth therapy with albendazole or mebendazole. Radical excision is almost impossible in hydatid disease of the spine because of the absence of distinct anatomical planes and the existence of neural structures, so the local recurrence rate is high. Our case had a surgical procedure three years prior to our evaluation in another centre, and only partial laminectomy was applied. The choice of surgical technique is important, particularly for type 4 vertebral hydatidosis, to provide total removal of the cysts, correction of the deformity, and maintenance of the correction.

Surgical excision of the mass depends on the location and extent of the lesion. The site and extent of the cyst, the relationship with neurological structures, the presence of bone involvement and destruction, and spinal instability and deformity are important when deciding on the surgical procedure type. Laminectomy with simple decompression is used most frequently⁹. In subjects with spinal hydatidosis with involvement of one or more vertebrae accompanied by medium or severe kyphosis, decompression, fusion and instrumentation by simultaneous successive anterior and posterior surgery is

an effective and safe management method for removing the lesion, decompressing the spinal cord and nerve roots and effective kyphosis correction with a solid fusion mass. The combination of this surgical procedure with chemotherapy (albendazole) for at least six months seems to be the most effective treatment method that also decreases recurrence.

Hydatid cysts should be kept in mind as a differential diagnosis when a cystic lesion of the spine is encountered. Hydatid disease of the spine is rare, and misdiagnosis, resulting in inadequate treatment and recurrence, is frequent. Maintaining the stability of the spine and achieving a fusion mass is important when deciding on the surgical technique for vertebral types of hydatidosis. Combined anterior-posterior radical excision, correction of deformities in both the sagittal and frontal planes, stabilization with a strut graft and titanium instrumentation, and chemotherapy with albendazole for at least six months seems to be the most effective treatment method for vertebral hydatid disease, which also decreases recurrence.

REFERENCES

1. Berk C, Ciftci E, Erdogan A. MRI in primary intraspinal extradural hydatid disease: case report. *Neuroradiology* 1998; 40: 390–392.
2. Bhojraj SY, Shetty NR. Primary hydatid disease of the spine: an unusual cause of progressive paraplegia. Case report and review of the literature. *J Neurosurg* 1999; 91: 216–218.
3. Braithwaite PA, Lees RF. Vertebral hydatid disease: radiological assessment. *Radiology* 1981; 140: 763–766.
4. Celik C, Sasmaz MF, Oktay F, Ucan H, Kaptanoglu E. Paraplegia associated with spinal hydatid cyst. A case report. *Spine* 2010; 35: 356–358.
5. Chang KH, Han MH. MRI of CNS parasitic diseases. *J Magn Reson Imaging* 1998; 8: 297–307.
6. Charles RW, Govender S, Naidoo KS. Echinococcal infection of the spine with neural involvement. *Spine* 1988; 13: 47–49.
7. King CH. Cestodes. In: Mandell GL, Bennett JE, Dolin R, eds. *Mandell, Douglas and Bennett's Principles and Practice of Infectious Diseases*. 6th ed., Elsevier Churchill Livingstone Inc., Philadelphia 2005; pp: 3285–3293.
8. Morshed AA. Hydatid disease of spine. *Neurochirurgia* 1997; 20: 211–215.
9. Pamir MN, Akalan N, Özgen T, Erben A. Spinal hydatid cysts. *Surg Neurol* 1984; 21: 53–57.