



LONG-TERM RESULTS OF POSTERIOR SURGERY IN THORACOLUMBAR FRACTURES: SAGITTAL PLANE ANALYSIS

TORAKOLOMBER OMURGA KIRIKLARINDA POSTERİÖR CERRAHİNİN UZUN DÖNEM SONUÇLARI: SAGİTTAL PLAN ANALİZİ

M.Bülent BALİOĞLU¹,
Deniz KARGIN¹,
Yunus ATICI¹,
Akif ALBAYRAK¹,
M.Temel TACAL¹,
M.Akif KAYGUSUZ²

¹Orthopedics and Traumatology Specialist, Spine Diseases and Arthroplasty Clinic, S. B. Metin Sabancı Baltalimanı Bone Diseases Training and Research Hospital, İstanbul.

²Orthopedics and Traumatology Specialist, Prof. Dr., Training Specialist, Spine Diseases and Arthroplasty Clinic, S. B. Metin Sabancı Baltalimanı Bone Diseases Training and Research Hospital, İstanbul.

Address: M. Bülent Balioğlu, S. B. Metin Sabancı Baltalimanı Kemik Hastalıkları Eğitim ve Araştırma Hastanesi, Rumeli Hisarı Caddesi, No: 62, 34470, Baltalimanı / İstanbul.
Tel.: 0212 3237075
Fax: 0212 3237082
Gsm: 0532 2521483
Received: 4th January, 2014
Accepted: 4th March, 2014

SUMMARY

Introduction: The early and long-term postoperative results in the sagittal plane for thoracolumbar (TL) vertebral fractures that received only posterior instrumentation and fusion were examined.

Method: Between the years 1998–2004, 15 patients (11 males, 4 females) received surgery for a TL vertebral fracture. The average age was 34.6 (16–57) years. The average follow-up period was 8.43 (5–11) years. Fixation with posterior pedicle screws and rods, fracture distraction and fusion were applied to all patients. Sagittal plane measurements of the patients were taken radiologically preoperatively (Group 1), early postoperatively (Group 2), and late postoperatively (Group 3). The local kyphosis angle (LKA), anterior compression angle (ACA), anterior (F) and posterior (E) column heights of the fractured vertebrae were measured and compared.

Results: The average Group 1, 2 and 3 LKA measurements were 12.63°, 0.21° and 6.92°, respectively ($p < 0.001$), and the ACA measurements were 14.13°, 5.83° and 6.25°, respectively ($p < 0.001$). Significant differences were found between the average LKA, ACA and E/F scores of Group 1, Group 2 and Group 3 ($p < 0.001$). While there was a significant difference between the averages of the LKA and E/F measurements of Group 2 and Group 3 ($p < 0.05$), no statistical difference was found after comparing the average ACA angle ($p = 0.753$). While there was no significant change in E in any group ($p > 0.05$), the increase in F after surgery was considered significant ($p < 0.05$), and no difference was observed between the averages of Group 2 and Group 3 ($p > 0.05$). The VAS was 2.73 (0–5). While the neurological status showed obvious recovery in one case (from Frankel B to E), it remained the same in 14 cases. In the last follow-up, implant failure was seen at a rate of 70%. The VAS was 3.73 (0–5).

Conclusion: At the end of an average follow-up period of eight years for posterior TL fractures, no differences were found between the early and late period measurements of the ACA and anterior height. Although LKA showed a statistical loss, the degree of correction achieved in the late period was found to be significantly higher than in the preoperative period.

Key words: Thoracolumbar fracture, local kyphosis, sagittal plan analysis

Level of Evidence: Retrospective clinical study, Level III

ÖZET

Amaç: Torakolomber (TL) vertebra kırığı nedeniyle sadece posteriordan enstrümantasyon ve füzyon uygulanan hastaların sagittal planda erken ve geç postoperatif sonuçlarının değerlendirilmesi amaçlandı.

Yöntem: 1998-2004 yılları arasında TL vertebra kırığı nedeniyle 15 hasta (11 erkek, 4 kadın) opere edildi. Hastaların ortalama yaşı 34.6 (16-57) yıl idi. Tüm hastalara aynı seansta posterior pedikül vida ve rodları ile fiksasyon, kırık distraksiyonu ve füzyon uygulandı. Ortalama 8.43 (5-11) yıl takip edilen hastaların radyolojik olarak cerrahi öncesi (Grup 1), cerrahi sonrası erken (Grup 2) ve son kontrolde geç dönem (Grup 3) sagittal planda ölçümleri yapıldı. Kırık vertebra lokal kifoz açısı (LKA), anterior kompresyon açısı (AKA), kırık vertebra cismi anterior (F) ve posterior (E) yüksekliği ölçülüp karşılaştırıldı.

Bulgular: LKA sırası ile ortalama 12.63°, 0.21°, 6.92° ($p < 0.001$), AKA 14.13°, 5.83°, 6.25° ($p < 0.001$) ölçüldü. Her üç grupta LKA, AKA, E/F ortalamaları arasında anlamlı değişim gözlemlendi ($p < 0.001$). Grup 2 ve Grup 3 LKA, E/F ortalamaları arasında anlamlı fark varken ($p < 0.05$), AKA ortalamaları arasında anlamlı fark gözlemlenmedi ($p = 0.753$). E her üç grup arasında değişim göstermedi ($p > 0.05$). F de cerrahi sonrası artış anlamlı değerlendirilirken ($p < 0.05$), Grup 2 ve Grup 3 ortalamaları arasında fark gözlemlenmedi ($p > 0.05$). Nörolojik durum 1 olguda belirgin düzelleme gösterirken (Frankel B den E ye), diğer 14 olguda ilk hali ile kaldı. Son kontrolde implant yetmezliği %70 bulundu. GAC 3.73 (0-5) oldu.

Sonuç: TL vertebra kırıklarının posteriordan cerrahi tedavisinin ortalama 8 yıllık takibinin sagittal plan analizi sonucunda AKA ve vertebra anterior cisim yüksekliğinde cerrahi sonrası erken ve geç dönem arasında fark bulunmadı. LKA da ise kayıp oluşmasına rağmen geç dönemde sağlanan düzelleme derecesinin cerrahi öncesine göre anlamlı derecede yüksek olduğu gösterildi.

Anahtar kelimeler: Torakolomber kırık, lokal kifoz, sagittal planda analizi

Kant Düzeyi: Retrospektif klinik çalışma, Düzey III

INTRODUCTION:

Thoracolumbar (TL) spine traumas are the most common injuries affecting the musculoskeletal system¹¹. The treatment methods and surgery types for TL vertebral fractures are still controversial (1-2,15). Surgical treatment is not preferred for many compression and stable burst fractures in the TL region. 90% of all spine fractures are observed in the TL region, and many of them are observed at the T10–L4 levels. AO type A (compression) fractures are seen in about 66% of TL vertebral fractures. Flexion-distraction (type B) injuries are commonly observed in the TL region and they represent 1–16% of TL region fractures^{16,20}.

The treatment of TL vertebral fractures can be conservative or surgical. Surgical treatment can be required for unstable injuries to avoid post-traumatic kyphosis and neurological disruption. The surgical treatment of TL vertebral fractures aims to correct deformity, to prevent further deformities developing, to reduce the risk of neurological injury, to provide initial stability, and to decrease complications based on early mobilization and the use of orthosis. Surgical treatment can include posterior instrumentation, anterior decompression and instrumentation, or a combination of both. For neurologically robust unstable burst fractures, posterior vertebral fusion is recommended when there is $>25^\circ$ kyphosis, $>50\%$ vertebral height loss or $>40\%$ canal pressure¹³.

With posterior surgical treatment, fusion is classically performed using instrumentation with a posterior approach^{3,5,11,18}. It was demonstrated that the use of posterior transpedicular internal fixation and a transpedicular bone graft did not significantly affect the clinical and radiological

results^{3,11}. Short-segment surgery from the posterior and long-segment surgery were compared, and no significant differences were observed between the clinical results^{17,18}. In recent years, similar results have been obtained for the application of both minimally invasive percutaneous pedicle screws and open surgery for TL fractures⁹.

This study aims to retrospectively evaluate and analyze the early and late radiological changes in the sagittal plane for patients who received fusion from the posterior alone due to TL vertebral fractures.

MATERIALS AND METHODS:

15 patients (11 males, 4 females) received surgery from the posterior due to TL vertebral fractures between 1998 and 2004. The mean age of the patients was 34.6 ± 15.06 (16–57) years. For the patients who received internal fixation and fusion from the posterior with TL vertebral fractures, the changes in the sagittal plane were retrospectively evaluated. The mean follow-up period was 8.43 ± 2.99 (5–11) years. The fractures were classified according to the AO/ASIF (Magerl) system. TL vertebral fractures were investigated with preoperative anteroposterior and lateral X-rays, computerized tomography, and magnetic resonance imaging. The American Spinal Injury Association (ASIA)/Frankel classification was used to assess the neurological status. While deciding on surgery, whether the posterior ligamentous complex was robust was clinically and radiologically tested. Posterior pedicle screw fixation and fusion was applied to the patients who were receiving surgery as soon as possible. Fusion of a minimum number of mobile segments was the aim during surgery.

Titanium polyaxial pedicle screws were used as the implant, except for one case, and 30–60 cc of cancellous allografts were used for fusion.

After surgery, a TLSO brace was used for about 1.5 months. Implant failure was followed up in terms of infection and neurological status. The clinical satisfaction of the patients was evaluated according to the visual analog scale (VAS).

The radiological parameters measured in the sagittal plane included the local kyphosis angle (LKA = AD), the anterior compression angle (ACA = BC), the vertebral anterior height

(F) and the vertebral posterior height (E) (Table-1). The measurements in the sagittal plane were performed preoperatively (Group 1), and in the early (Group 2) and late (Group 3) postoperative period, and compared with each other. Descriptive statistical methods (mean, standard deviation) were used for statistical analyses (NCSS 2007) and evaluation of the data. The Friedman test was used for repetitive measurement of the groups and Dunn's multiple comparison test was used for subgroup comparisons. The results were evaluated according to $p < 0.05$.

Table-1. Radiological evaluation in the sagittal plane

Dunn's multiple comparison test	LKA (°)	ACA (°)	F (cm)	E/F (cm)
Preop/early postop	0.001	0.001	0.001	0.015
Preop/late postop	0.022	0.001	0.001	0.001
Early postop/late postop	0.011	0.753*	0.726*	0.002

RESULTS:

When the vertebral fracture levels were investigated, a total of 23 vertebral fractures were detected, between the T5–L4 vertebral levels (most commonly L1) in 15 cases. Nine fractures at the L1 vertebral level (39%), three fractures at T12 and L2 (13%), two fractures at the L3 and L4 vertebrae (9%) and one fracture at the T5–6–8–10 levels (4%) were observed. Fractures were observed at two consecutive levels in six of the patients, and at three different levels in one patient. Long-segment instrumentation and short-segment instrumentation were applied to nine and six patients, respectively. For the patients who received short-segment instrumentation, a pedicle screw was placed at

the fracture level if appropriate. No laminectomy was applied to any patients.

The fractures were evaluated according to the AO/ASIF classification⁽¹²⁾. Type A, type B and type C vertebral fractures were observed in 20 (87%), two (9%) and one (4%) vertebrae, respectively. When the reasons for trauma were considered, the most common reason was falling from a height (64%), then traffic accidents (29%) and work accidents (7%). The neurological status was evaluated with the ASIA/Frankel classification. In 13 patients, the neurological status was stable, as preoperative and postoperative Frankel E. One patient had preoperative Frankel D without any change

postoperatively and Frankel B neurological signs became Frankel E in one patient who received surgical intervention in the first six hours after trauma. The change of the LK and ACA in the sagittal plane was measured preoperatively and early and late postoperatively (Figure-1). In the fractured vertebrae, the change of the anterior and posterior vertebral height in the sagittal plane was evaluated (Figure-2). Comparative statistical analyses of the groups were performed with Dunn's multiple comparison test (Table-2). A significant change was observed between the LKA, ACA, F and E/F measurements of Group

1, Group 2 and Group 3 ($p < 0.001$) (Table-3, Figure 1). While there was a significant difference between the LKA and E/F average values of Group 2 and Group 3 ($p < 0.05$), no statistically significant difference was observed in terms of the ACA average values between both groups ($p = 0.05$). E did not show any significant differences between the three groups ($p > 0.05$), while the increase in F was significant after surgery between all groups ($p < 0.05$). There were no differences in the average values of Group 2 and Group 3 ($p > 0.05$).

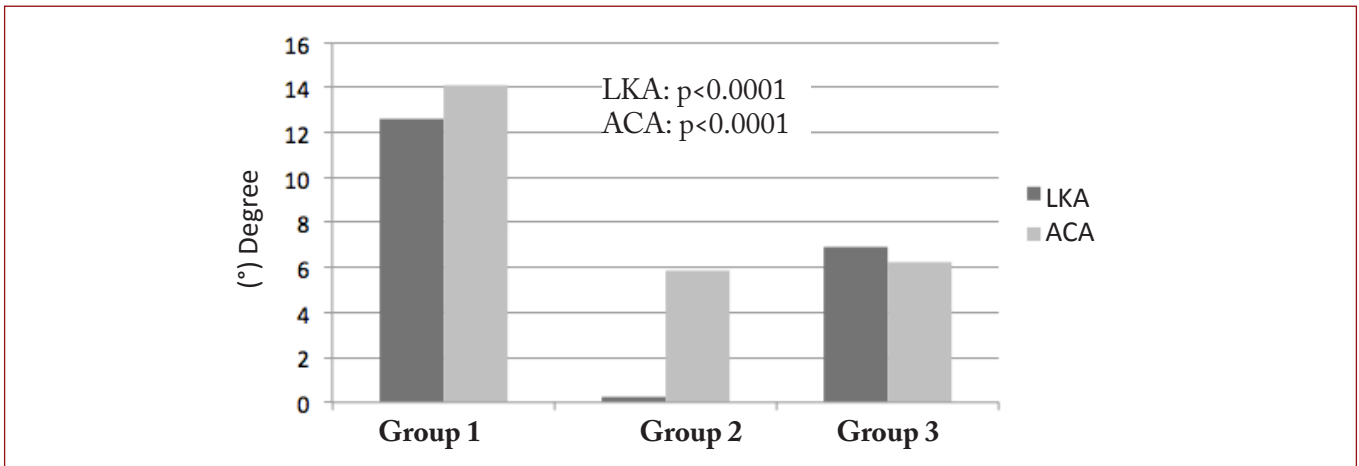


Figure-1. Preoperative (Group 1), and early (Group 2) and late (Group 3) postoperative changes of LK and ACA in the sagittal plane.

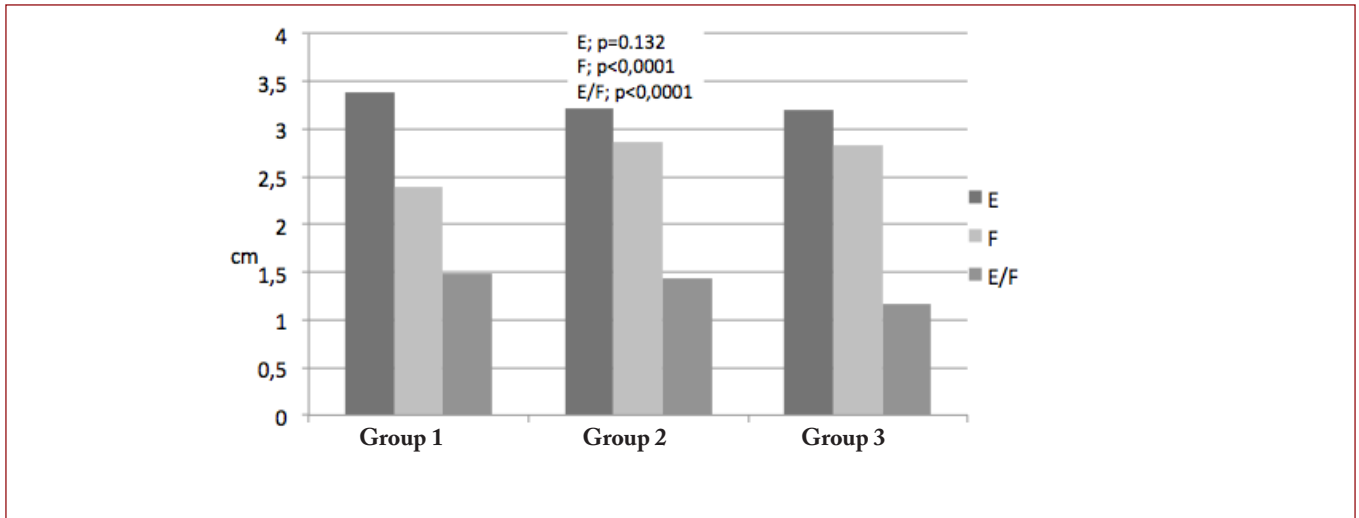


Figure-2. The distribution of changes of the anterior (F) and posterior (E) vertebral heights of fractured vertebrae in the sagittal plane.

Table-2. Comparative statistical analysis of the groups and Dunn's multiple comparison test.

Local kyphosis angle	Early Postop	Late Postop
Anterior compression angle	ACA° = BC	
Vertebral anterior height	F	
Vertebral posterior height	E	




Table-3. Significant differences between the LKA, ACA, F and E/F average values were observed between Group 1, Group 2 and Group 3 ($p < 0.001$). There was no change in the height of E ($p = 0.132$).

	Preop	Erken Postop	Geç Postop	Fr	p
AD (°)	12,63±9,87	0,21±12,53	6,92±15,84	29,93	0,0001
BC (°)	14,13±8,62	5,83±3,96	6,25±6,39	16,38	0,0001
E (cm)	3,38±0,52	3,21±0,44	3,2±0,7	4,05	0,132
F (cm)	2,4±0,68	2,87±0,49	2,83±0,78	19,85	0,0001
E/F (cm)	1,49±0,38	1,43±0,39	1,17±0,22	20,46	0,0001

There were no extra neurological complications or infections in any patients. In the last follow-up, 70% implant failure was observed, consisting of pedicle screw fracture in eight cases (54%) and rod fracture in five cases (33%), alone or together. Although a high rate of implant failure was present, all patients except one returned to work. The average VAS was found to be 3.73 ± 1.62 (0–5).

DISCUSSION:

Treatment of TL vertebral fractures is controversial. If there are no neurological deficits in TL burst fractures, it seems that neither conservative nor surgical treatment is superior. If there are neurological deficits, surgical treatment is suggested⁷. It has been reported that conservative treatment is safe and

effective for chosen patients⁶. In TL vertebral fractures, posterior surgical treatment options include short- or long-segment pedicle screw application from the posterior, pedicle screw to the fractured vertebra, minimally invasive pedicle screw, transpedicular graft application, or short-segment non-fusion fixation^{1-3,5,9-11,14,17,18}. For stabilization of TL vertebral burst compression injuries, posterior transpedicular internal fixation is accepted as a valid and standard procedure. However, the long-term results of this approach are still controversial^{3,5,11,18}.

In TL vertebral unstable burst fractures that are neurologically intact, posterior vertebral fusion is recommended when there is $>25^\circ$ kyphosis, $>50\%$ vertebral height loss and $>40\%$ canal pressure¹³.

Chance fractures and flexion-distraction injuries can cause distinct kyphosis. While many stable, neurologically robust compression fractures can be treated with conservative treatments, neurologically robust unstable burst fractures can be treated with short, rigid posterior fusion. If there is a burst fracture with an unstable neurological deficit, direct or indirect decompression is suggested¹³. Flexion-distraction injuries can cause disruption of the middle and posterior column of the vertebra due to distractive forces⁸. These fractures are often unstable with anterior column injuries such as compression fractures, and kyphosis can develop¹⁹. The posterior structures and posterior ligamentous complex are often injured⁽⁴⁾. Surgical treatment can be required for unstable injuries to avoid post-traumatic kyphosis and neurological disruption. Surgical treatment classically includes instrumented fusion with a posterior open approach. Especially for neurologically robust cases with no internal canal fragmentation, while percutaneous pedicle screw application provides sufficient stabilization, the aim is for minimal tissue damage and protection

of the normal anatomy. In a prospective study on flexion-distraction and posterior ligamentous complex injuries, Grossbach et al. applied open pedicle fixation and posterolateral fusion to 27 patients, and minimally invasive pedicle screw fixation to 11 patients. They observed recovery of the kyphosis angle in both groups in their last follow-up and in the postoperative early period. They did not find any significant differences between open and minimally invasive surgical procedures in terms of the neurological status and kyphosis angle degree⁹. When minimally invasive percutaneous pedicle screw fixation was compared with an open surgical technique for flexion-distraction injuries, it was suggested that a minimally invasive method can be used as an alternative, due to a similar outcome with less blood loss⁹. In our patients, we only applied an open surgical approach from the posterior. We observed that the posterior ligamentous complex, in particular, was moderately or severely damaged. We aimed for fusion of a minimum of mobile segments from the posterior according to the fracture level (Figure-3,4,5 and 6).

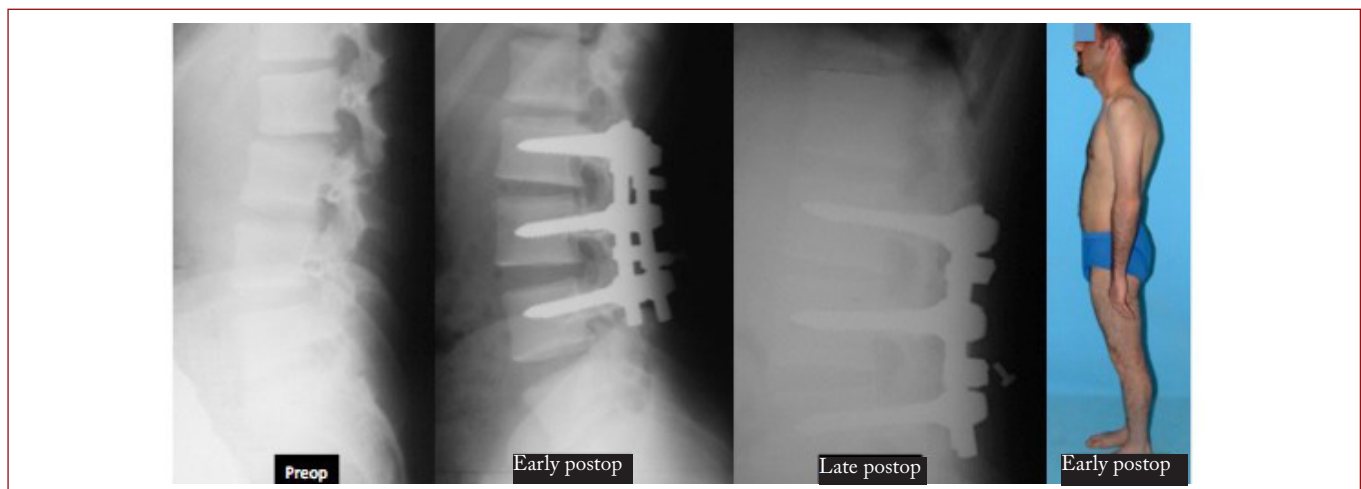


Figure-3. M aged 28; a fall from a height; follow-up period: 11 years; fracture level: L2–3; fracture type: Type B.1.1 (flexion/distraction); short segment fusion; VAS 4 in the last follow-up.

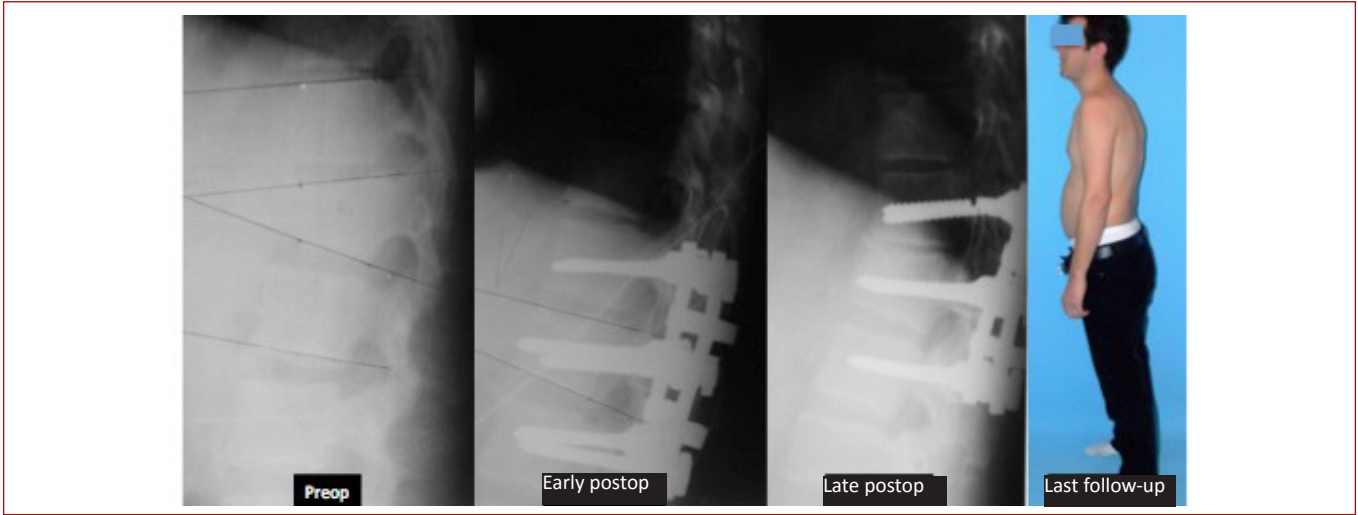


Figure-4. M aged 41; traffic accident; follow-up period: 11 years; fracture level T10–L1; fracture type: Type A 3.3 + A 1.3; short segment fusion; VAS 5 in the last follow-up.

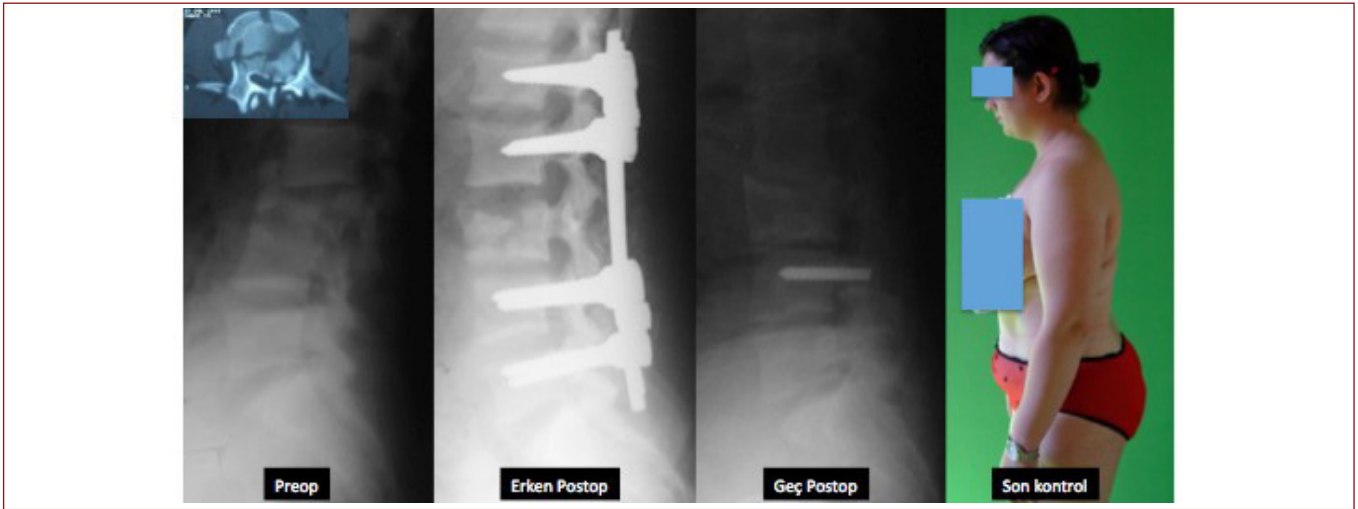


Figure-5. F aged 27; a fall from a height; follow-up period: 11 years; fracture level L3; fracture type: Type C 1.3 (rotation) + A 3.3 (burst); long segment fusion; VAS 3 in the last follow-up.

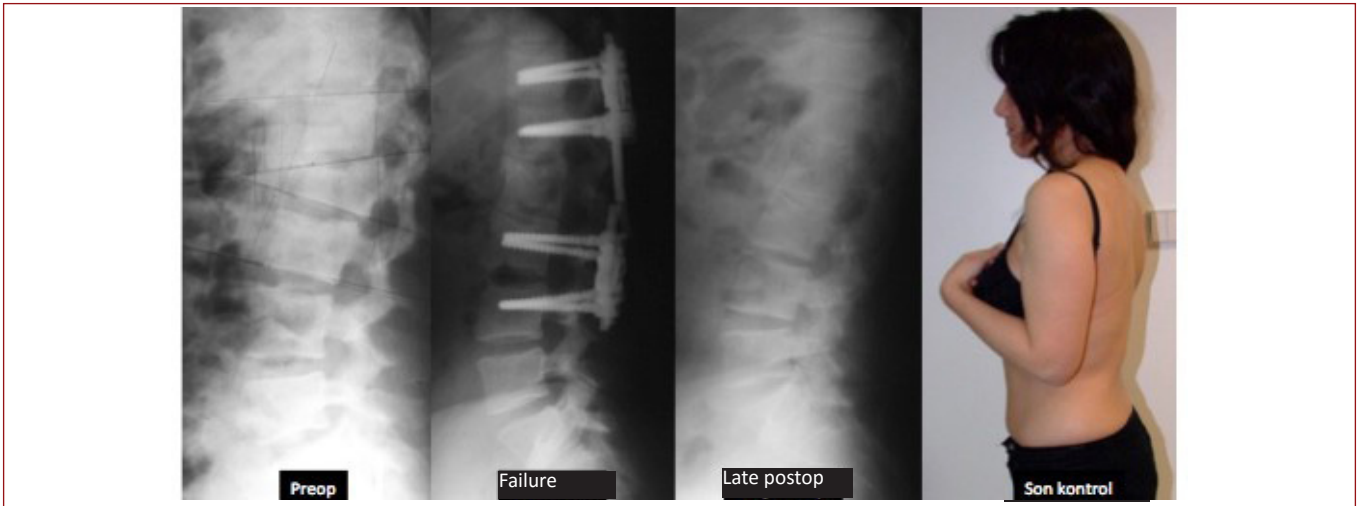


Figure-6. F aged 26; a fall from a height; follow-up period: 9 years; fracture level L1–2; fracture type: type B 2.3 (flexion-distraction) + Type A 1.1 (compression-endplate impaction); long segment fusion; VAS 3 in the last follow-up.

There have been many studies investigating the radiological and clinical results of TL vertebral fractures in the sagittal plane. In a study in which Cotrel-Dubousset pedicle screw instrumentation was applied to 38 patients with unstable TL and lumbar (T12–L5) vertebral fractures, the canal compression, compression index, kyphosis correction, satisfaction, use of drugs for pain, and return to work were evaluated. In the follow-up, only 1° of correction was present with 6° loss of kyphosis after corrective surgery. While screw fracture or bending was observed in the TL region of nine patients, successful surgical results were obtained for 32 of 33 patients, and 27 patients returned to work⁵. In the long-term follow-up, our patients also returned to work, except for one patient who received surgery from the posterior due to a TL vertebral fracture, and there was no regular use of drugs for the pain.

For TL fractures, pedicle screw fixation with the application of transpedicular fusion is accepted as controversial. For TL vertebral fractures, posterior transpedicular internal fixation and transpedicular bone grafting were first defined by Daniaux to provide fusion between vertebral bodies. According to a study by Knop et al., transpedicular cancellous bone grafting between vertebral bodies after posterior stabilization for complete or incomplete vertebral burst fractures was shown not to decrease the correction loss as a fusion technique¹¹. Knop found no relationship between the Magerl classification and the radiological results, but he found a significant relationship between the preoperative kyphosis angle of the vertebra and the postoperative reduction loss¹¹. In a retrospective study by Andress et al., internal fixation or internal fixation with a transpedicular

spongiosis graft were applied to 50 patients with unstable compression-burst fractures in the TL region. They showed that transpedicular grafting did not affect the clinical or radiological results significantly³. Alanay et al. published a randomized, prospective study in which they compared patients who received short-segment fixation for TL burst fractures with or without transpedicular grafting for fusion.

They did not find any differences in terms of the sagittal index (SI), anterior vertebral height ratio, or LKA correction loss between the groups. It was also emphasized that there was a high rate of failure with short-segment transpedicular instrumentation for TL burst fractures, and the addition of transpedicular intercorporeal grafting had no effect on reducing the failure rate¹. For our patients, we applied fusion alone with corticospinous allografts from the posterior, and did not apply transpedicular grafts to any patients. In the last follow-ups of the cases with TL vertebral fractures who received a posterior approach alone, although we encountered a high rate of implant failure, the patient satisfaction was better and a higher correction was present in the sagittal plane when compared to the preoperative period (Figures-4,5,6).

Although short-segment pedicle fixation has been a popular treatment option in recent years, a high rate of implant failure has been reported¹⁻². In a study by Tezeren and Kuru, they compared short- and long-segment pedicle fixation for TL fragmented fractures, and showed better results for LKA, SI and anterior vertebral height compression on application of long-segment instrumentation ($p < 0.05$). While 55% implant failure was observed for patients with short-segment instrumentation, a prolonged operation duration and increased bleeding amount were

observed for the patients with long-segment instrumentation. There was no difference in the clinical evaluation between the groups. According to the radiological parameters, it was shown that long-segment instrumentation was more effective for TL burst fractures¹⁸. Altay et al. compared long- and short-segment fixation for Magerl Type A unstable TL burst fractures, and found more significant correction of the SI and canal compression for patients who received long-segment instrumentation than for patients with short-segment fixation. Although the radiological results were better with long-segment fixation, the clinical results were found to be the same, except for Magerl Type A33 fractures². Üzümcügil et al. retrospectively compared long- and short-segment posterior fusion for patients who received pedicle screws to the fracture level and to one lower and two upper levels. In the final follow-up, improved anterior vertebral height, LKA and SI were observed for both groups, but there was no difference between the two groups clinically or radiologically. In the group who received short-segment instrumentation, although the local kyphosis loss was found to be significant in the postoperative and last follow-ups, no implant failure was encountered, unlike previously published studies, and satisfactory results were clinically obtained despite radiological correction loss¹⁷. Jindal et al. carried out a prospective study in which they compared patients who received short-segment pedicle screw fixation for TL burst fractures with or without fusion. While perioperative blood transfusion was found to be significantly higher in the group with fusion, no significant differences were found between the two groups in terms of the clinical and radiological results, and fusion was found to be unnecessary with short-segment pedicle screw

fixation for TL vertebral burst fractures¹⁰. In our patients, the late postoperative LKA, ACA and F showed significant improvement when compared to the preoperative period. Although a decrease in the LKA was observed in the late postoperative period, significant improvement occurred when compared to the period before the fracture. In our patients, implant failure was observed at a rate 20–50% higher than that seen in the literature (70%).

The limitations of our study are the low patient numbers, there was no comparison between short- and long-segment instrumentation, there was no comparison between groups with or without the placement of screws into the fractured vertebrae, the patients were not in the same age range, no standard instrumentation was used for all of the patients, and updated fracture classification and patient satisfaction surveys were not used. Therefore, there is a need for standardized, comparative studies on TL region fractures that include a large patient number. As a result, although we observed a loss of kyphosis angle in the sagittal plane of patients who received posterior fusion for TL fractures, a significant improvement was observed when compared to the preoperative period. Early posterior surgery can be effective for correction in the sagittal plane in the long-term, especially in the presence of instability, neurological damage, kyphosis development risk and injury of the posterior ligamentous complex.

In conclusion, when the local kyphosis angle, anterior kyphosis angle and anterior vertebral height were compared for TL vertebral fractures treated with posterior surgery in the preoperative, early, and late postoperative periods, a significant improvement was observed. No significant difference was found

between the early and late postoperative period in terms of the anterior kyphosis angle and the anterior vertebral height. Although there was a decrease in the local kyphosis angle in the late postoperative period relative to the early period, the improvement degree was found to be significantly higher than the preoperative measurements.

Early surgery seems to be necessary for TL vertebral fractures, in terms of the neurological improvement and stability. Although a high rate of implant failure (70%) was observed with posterior surgical treatment of TL vertebral fractures in the long term, a significant improvement in the sagittal plane deformity was obtained.

REFERENCES

1. Alanay A, Acaroglu E, Yazici M, Oznur A, Surat A. Short-segment pedicle instrumentation of thoracolumbar burst fractures: does transpedicular intracorporeal grafting prevent early failure? *Spine* 2001; 26(2): 213-217.
2. Altay M, Ozkurt B, Aktekin CN, Ozturk AM, Dogan O, Tabak AY. Treatment of unstable thoracolumbar junction burst fractures with short or long-segment posterior fixation in magerl type a fractures. *Eur Spine J* 2007; 16(8): 1145-1155.
3. Andress HJ, Braun H, Helmberger T, Schürmann M, Hertlein H, Hartl WH. Long-term results after posterior fixation of thoracolumbar burst fractures. *Injury* 2002; 33(4): 357-65.
4. Beringer W, Potts E, Khairi S, Mobasser JP. Percutaneous pedicle screw instrumentation for temporary internal bracing of nondisplaced bony Chance fractures. *J Spinal Disord Tech* 2007; 20: 242-247.
5. Carl AL, Tromanhauser SG, Roger DJ. Pedicle screw instrumentation for thoracolumbar burst fractures and fracture-dislocations. *Spine* 1992; 7(8 Suppl): S317-S324.
6. Dai LY, Jiang LS, Jiang SD. Conservative treatment of thoracolumbar burst fractures: a long-term follow-up results with special reference to the load sharing classification. *Spine* 2008; 33(23): 2536-2544.
7. Dai LY, Jian SD, Wang XY, Jiang LS. A review of the management of thoracolumbar burst fractures. *Surgical Neurology* 2007; 67(3): 221-231.
8. Denis F. The three column spine and its significance in the classification of acute thoracolumbar spinal injuries. *Spine* 1983; 8: 817-831.
9. Grossbach AJ, Dahdaleh NS, Abel TJ, Woods GD, Dlouhy BJ, Hitchon PW. Flexion-distraction injuries of the thoracolumbar spine: open fusion versus percutaneous pedicle screw fixation. *Neurosurg Focus* 2013; 35(2): E2.
10. Jindal N, Sankhala SS, Bachhal V. The role of fusion in the management of burst fractures of the thoracolumbar spine treated by short segment pedicle screw fixation: A prospective randomised trial. *J Bone Joint Surg* 2012; 94-B: 1101-1106.
11. Knop C, Fabian HF, Bastian L, Blauth M. Late results of thoracolumbar fractures after posterior instrumentation and transpedicular bone grafting. *Spine* 2001; 26(1): 88-99.
12. Magerl F, Aebi M, Gertzbein SD, Harms J, Nazarian S. A comprehensive classification of thoracic and lumbar injuries. *Eur Spine J*. 1994; 3(4): 184-201.
13. Mark MR, Stchur RP, Graziano GP. Posterior instrumentation for Thoracolumbar Fractures. *J Am Acad Orthop Surg* 2004; 12: 424-435.

-
14. Parker JW, Lane JR, Karaikovic EE, Gaines RW. Successful short segment instrumentation and fusion for thoracolumbar spine fractures: a consecutive 41/2-year series. *Spine* 2000; 25(9): 1157-1170.
 15. Patel AA, Vaccaro A. Thoracolumbar spine trauma classification: review article. *J Am Acad Orthop Surg* 2010; 18: 63-71.
 16. Patel AA, Vaccaro AR, Albert TJ, Hilibrand AS, Harrop JS, Anderson DG, et al. The adoption of a new classification system: time-dependent variation in interobserver reliability of the thoracolumbar injury severity score classification system. *Spine* 2007; 32: E105-E110.
 17. Üzümcügil O, Doğan A, Yetiş M, Yalçinkaya M, Caniklioğlu M. Results of 'two above- one below approach' with intermediate screws at the fracture site in the surgical treatment of thoracolumbar burst fractures. *Kobe J Med Sci* 2010; 56(2): E67-E78.
 18. Tezeren G, Kuru İ. Posterior Fixation of Thoraco- lumbar Burst Fracture: Short-Segment Pedicle Fixation Versus Long-Segment Instrumentation. *Journal of Spinal Disorders & Techniques* 2005; 18(6): 485-488.
 19. Vaccaro AR, Lehman RA Jr, Hurlbert RJ, Anderson PA, Harris M, Hedlund R, Harris M, Hedlund R, Harrop J, Dvorak M, Wood K, Fehlings MG, Fisher C, Zeiller SC, Anderson DG, Bono CM, Stock GH, Brown AK, Kuklo T, Oner FC. A new classification of thoracolumbar injuries: the importance of injury morphology, the integrity of the posterior ligamentous complex, and neurologic status. *Spine* 2005; 30: 2325-2333.
 20. Verlaan JJ, Diekerhof CH, Buskens E, van der Tweel I, Verbout AJ, Dhert WJ, Oner FC. Surgical treatment of traumatic fractures of the thoracic and lumbar spine: a systematic review of the literature on techniques, complications, and outcome. *Spine* 2004; 29: 803-814.

