



DECISION MAKING FOR SAGITTAL IMBALANCE CORRECTION WITH COMPUTER ASSISTANCE

SAGİTTAL DENGESİZLİĞİN DÜZELTİLMESİNDE BİLGİSAYAR YARDIMLI KARAR VERME

Akif ALBAYRAK¹,
Yunus ATICI¹,
Mehmet Bülent
BALIOĞLU¹,
Deniz KARGIN¹,
Mehmet Nurullah ERMIŞ¹,
Evren AKPINAR¹,
Abdul Fettah BÜYÜK¹

¹Department of Orthopaedic
Surgery Metin Sabancı
Baltalimanı Bone Diseases
Education and Research Hospital,
İstanbul, Turkey.

Address: Yunus Atıcı,
S.B. Metin Sabancı Baltalimanı
Kemik Hastalıkları Eğitim ve
Araştırma Hastanesi, Ortopedi
ve Travmatoloji Kliniği, Omurga
Hastalıkları Cerrahisi ve Protez
Cerrahisi Grubu, Baltalimanı,
Sarıyer / İSTANBUL
Tel.: 0505 4921945
E-mail: yunatici@hotmail.com
Received: 1st January, 2014
Accepted: 30th January, 2014

SUMMARY

Objective: To document surgical techniques in a virtual environment in a variety of scenarios, considering their applications and consequences, and to determine the usefulness of computer-assisted osteotomy planning for spinal deformities.

Summary of Background Data: Computer-assisted surgical planning of sagittal plane deformity corrections allows operative maneuvers to be simulated on a computer to develop insight before application in the operating room. Image-guided surgical planning of deformity correction improves the surgical accuracy and can help to translate a virtual surgical plan into a real operation.

Methods: We used the Surgimap Spine program to determine the optimal corrective osteotomy for sagittal plane deformity for 11 patients. The program guided us through planning the osteotomy level, the osteotomy number, and osteotomy type (whether Smith-Petersen osteotomy (SPO), pedicle subtraction osteotomy (PSO), or both combined).

Results: After virtual osteotomy, the surgical plan was translated into a real plan in the operating room, and osteotomy including instrumentation was performed safely in all cases, resulting in the anticipated results with statistical significance ($p>0.01$).

Conclusion: We advocate the application of virtual surgical planning to improve safety and efficiency in complex spinal deformity corrections.

Keywords: Computer-assisted osteotomy, spinal osteotomy, sagittal imbalance, ankylosing spondylitis

Level of Evidence: Retrospective clinical study, Level III

ÖZET

Amaç: Omurga deformiteleri için bilgisayar yardımlı osteotomi planlamanın çeşitli senaryolar üzerinden sanal ortamda uygulama ve planlamanın tanımlanması.

Özet: Sagittal plan deformitelerinin ameliyat öncesi bilgisayar yardımlı planlanması ameliyatta uygulanacak manevraların sanal ortamda uygulanarak sonuçların öngörülebilmelerini sağlamaktadır. Görüntü destekli ameliyat planlama sayesinde cerrahinin doğruluğu artırılırken sanal cerrahi planların gerçek ameliyatlarda uygulanırlığı sağlanmış olur.

Gereç ve Yöntem: Sagittal düzlem omurga deformitesi bulunan on bir hastanın osteotomi planlaması için Surgimap Spine programını kullandık. Program bize osteotomi seviyesi, sayısı ve tipi (Smith-Petersen Osteotomisi (SPO) veya Pedikül Substraction Osteotomisi (PSO)) konusunda yol gösterdi.

Sonuçlar: Sanal osteotomiden sonra cerrahi planla ameliyatlara uygulandı, osteotomi ve enstrümantasyon sonrası beklenenle istatistikî olarak benzer sonuçlar elde edildi ($p>0.01$).

Sonuç: Kompleks omurga deformite düzeltme ameliyatlarında sanal cerrahi planlamayı hasta güvenliği ve ameliyat etkinliğini arttırmak adına önermekteyiz.

Anahtar Sözcükler: Bilgisayar destekli osteotomi, omurga osteotomisi, sagittal balans kaybı, ankilozan spondilit

Kanıt Düzeyi: Retrospektif klinik çalışma, Düzey III

INTRODUCTION:

The SRS describes positive sagittal balance as the condition where the sagittal vertical axis (SVA) goes through the anterior to the L5–S1 disc in an upright long cassette film. In principle, any deviation of the SVA anterior to the normal position of the C7 plumb line by greater than 5 cm is considered positive sagittal imbalance.

Large deviations in the anterior-posterior or lateral planes require greater effort to maintain a standing position.

Once a spinal deformity causes a marked loss of function that deteriorates the quality of life, surgery is often recommended⁴.

A substantial imbalance in the sagittal plane sometimes cannot be individually corrected using only arthrodesis with instrumentation, especially when the deformity is very rigid. In these rare cases, spinal osteotomy must be performed to achieve balance in the sagittal plane.

A Smith-Petersen osteotomy (SPO) provides a small degree of correction, but it can be used at multiple levels with minimal blood loss and a lower operative risk. A pedicle subtraction osteotomy (PSO) is generally used for patients with a greater imbalance in the sagittal plane and when a minimum of 30° of correction is needed.

The goal of surgery is to restore both the patient's gaze and the sagittal balance of the spine.

Preoperative forecasting of the effect of an osteotomy is crucial in terms of the correction it will provide to the sagittal balance of the spine. However, the effect depends simultaneously on both the angle and the level of the osteotomy. The correction of the sagittal balance is maximal when the intervention is performed at the lowest possible level of the lumbar spine^{6,7}.

Recently, biomechanical methods founded on mathematical principles have been developed to assess the deformity before sagittal plane corrective osteotomies of the spine in ankylosing spondylitis.

These can be expressed as a form of mathematical equation, but neither the crucial mathematical equations nor the outcome are easy to use in daily practice⁶.

We used Surgimap Spine, a free computer program (<http://www.surgimap.com>; Nemaris Inc, New York, NY), to determine the optimal corrective osteotomy level, type, and number of recursion.

The program analyses the input and visualizes the planning procedure, which can be used easily in daily practice.

MATERIALS AND METHODS:

From May 2012 to January 2013, 11 patients (7 female, 4 male, mean age: 55) with sagittal imbalance who underwent spinal osteotomy (PSO or SPO) of the spine for correction of a kyphotic deformity were studied. Standard full-length anterior-posterior and lateral radiographs covering the whole spine were taken from the PACS system and saved in JPEG, DICOM or PNG format on a standard USB memory stick.

The program is able to open all medical image formats in a single interface. It runs directly on a memory stick, without requiring any installation. Measurements were made on radiographs obtained before surgery, six months after surgery, and at the last follow-up at a minimum of two years after surgery.

RESULTS:

After starting the program, we first browsed and loaded the images. For calibration of the program, we marked two points on the grid of the film and defined the distance in millimeters. After calibration we defined the sagittal Cobb angles from T2–12, T10–12 and L1–S1, and the pelvic parameters and the sagittal vertical axis (SVA) as the horizontal distance between the posterior corner of the sacrum and the plumb line from C7, using spine measurement tools. After determining these parameters, a virtual osteotomy plan was made, based on these values.

The total amount of correction required in the spine was determined by simulation of the osteotomy at the apex and at levels adjacent to the apex of the deformity.

After the virtual osteotomy, the program automatically calculated the Cobb angle, pelvic parameters and SVA changes.

To achieve a particular decrease in the SVA abnormality, a smaller correction angle is needed if the osteotomy is performed at a lower spinal level.

Preoperative lumbar lordosis was seen at an average of 5° (range: -23°-+25°) and improved to 35° (range: 26-46°) at the final follow-up. The thoracic kyphosis averaged 30° (range: 4-112°) before surgery and increased to 36° (range: 9-55°) at the final follow-up ($p<0.05$). The sagittal balance improved from 11 cm (range: 0-30 cm) preoperatively to 3 cm (range: -3-9 cm), resulting in 9 cm of correction at the final follow-up ($p<0.05$). All patients demonstrated postoperative changes in preoperative radiographic parameters, including decreased pelvic tilt (PT) (30° to 11°) and sagittal vertical axis (SVA) (18 cm to 7 cm), and increased sacral slope (SS) (16° to 35°) ($p<0.05$).

All postoperative sagittal contours and parameters of the sagittal trunk balance were statistically similar to the findings of the Surgimap program ($p>0.01$).

All 11 patients completed outcome questionnaires. A significant improvement in the back pain score was noted. The mean back pain score was 65 before surgery, and 13 at the time of the final follow-up ($p<0.05$).

Case sample 1:

The patient was 59 years old with ankylosing spondylitis. These patients typically present with lumbar hypolordosis and thoracolumbar kyphosis or cervicothoracic kyphosis. For this patient, the initial parameters were thoracic kyphosis of 39° and lumbar lordosis of 12°. The pelvic parameters were sacral slope of 20°, pelvic tilt of 50°, and pelvic incidence of 70°, as seen in Figure-1.a. This patient

had no thoracic hyperkyphosis, and so we only tried to correct the deformity of the lumbar area.

The initial osteotomy planning, a one-level L3 pedicle subtraction, is shown in Figure-1b.

After virtual osteotomy, the plumb line was seen to be corrected from 12 cm to 7 cm.

The program makes these parametric changes automatically; the user simulates the osteotomy and the program outputs the new lordosis, kyphosis and pelvic angles.

When evaluating the pelvic parameters, we observed the sacral slope increase and return to the normal value, but the pelvic tilt and pelvic incidence still remained pathological.

The second scenario planned, an L4-level osteotomy, is shown in Figure-1.c.

The same values are observed for the pelvic parameters and lumbar lordosis but there is better balance correction, and the plumb line is corrected from 12 cm to 5 cm.

The third alternative planned, an L1-3 two-level pedicle subtraction osteotomy, is shown in Figure-1.d. The lumbar lordosis is now 50°, the pelvic parameters are nearly normal, and the plumb line is +4 cm.

The last scenario, an L2-4 PSO, is shown in Figure-1.e, which returns exactly the same lordosis and pelvic parameters but shows a better plumb line correction.

Therefore we decided to carry out the combined L2-4 osteotomy due to the better plumb line correction. The postoperative clinical picture and X-ray are shown in Figure-1.f. The patient has a good gaze but the postoperative correction of the plumb line is less than expected. Case sample 2:

The patient was a 48-year-old female who had been operated on for congenital kyphosis three years previously, and had complaints of pain and weakness in both lower extremities and disability in walking.

Implant failure of the previous posterior instrumentation and pseudoarthrosis could be seen on X-rays. Her pelvic parameters were also abnormal (Figure-2.a).

In the program, we applied one-level asymmetric PSO at the apex and two-level SPO at the adjacent levels.

The program automatically made the pelvic parametric changes seen in Figure-2.b.

We also had the chance to simulate osteotomies in the coronal plane.

First, an asymmetric PSO affecting the coronal plane, and a three-level SPO at the adjacent upper levels are shown (Figure-2.c,d,e,f,g).

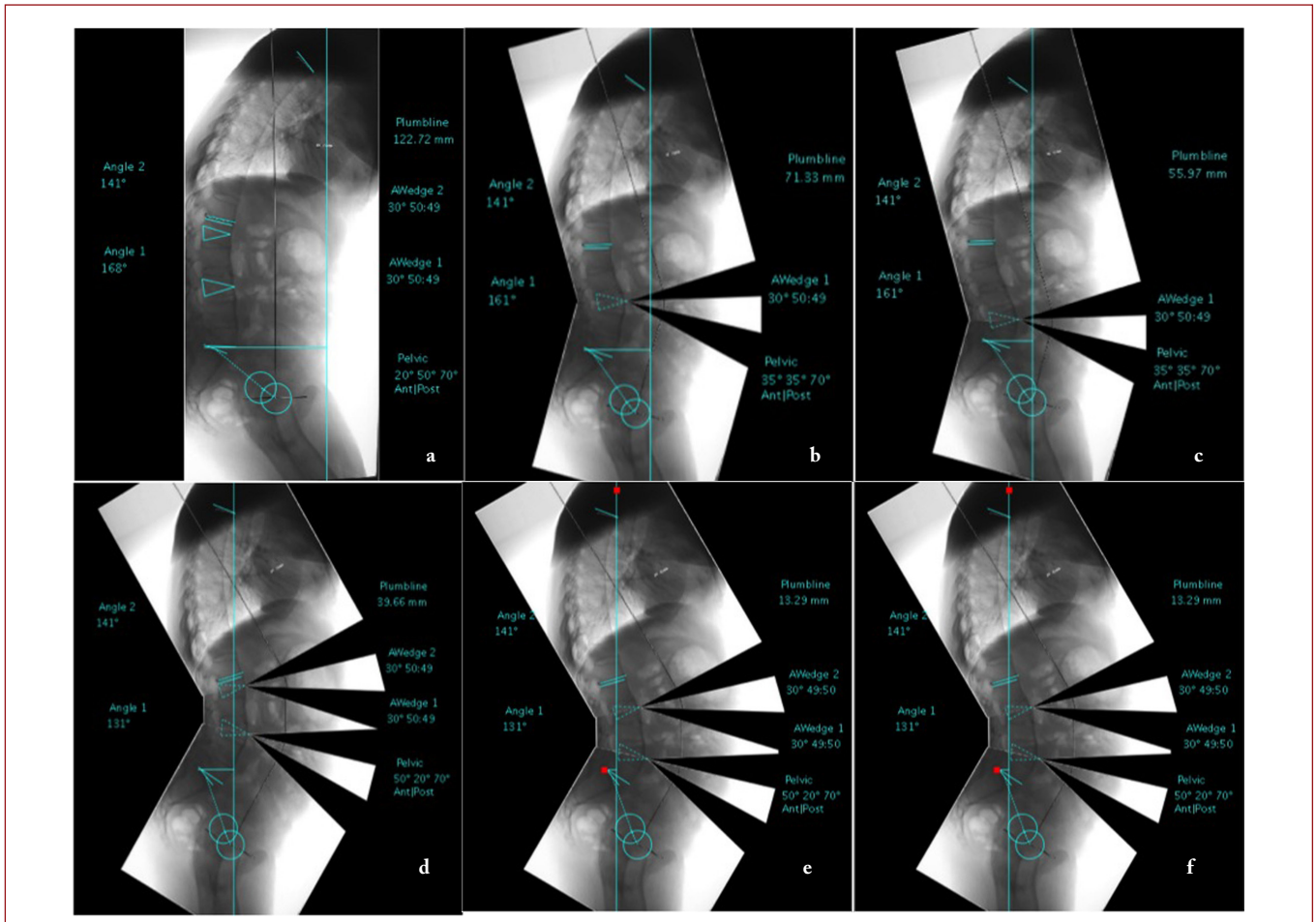


Figure-1.a) X-ray of a 59-year-old patient showing ankylosing spondylitis, lumbar hypolordosis and thoracolumbar kyphosis; **b)** One-level L3 pedicle subtraction osteotomy planning, showing correction of the osteotomy plumb line from 12 cm to 7 cm; **c)** L4 osteotomy planning, showing the same values for the pelvic parameters and lumbar lordosis but better balance correction, as the plumb line is corrected from 12 cm to 5 cm; **d)** L1-3 two-level pedicle subtraction osteotomy planning, showing the lumbar lordosis is now 50°, the pelvic parameters are nearly normal, and the plumb line is +4 cm; **e)** L2-4 PSO scenario, showing exactly the same lordosis and pelvic parameters but a better plumb line correction; **f)** The postoperative clinical picture and X-ray, showing the patient has a good gaze, but the postoperative correction should be better.

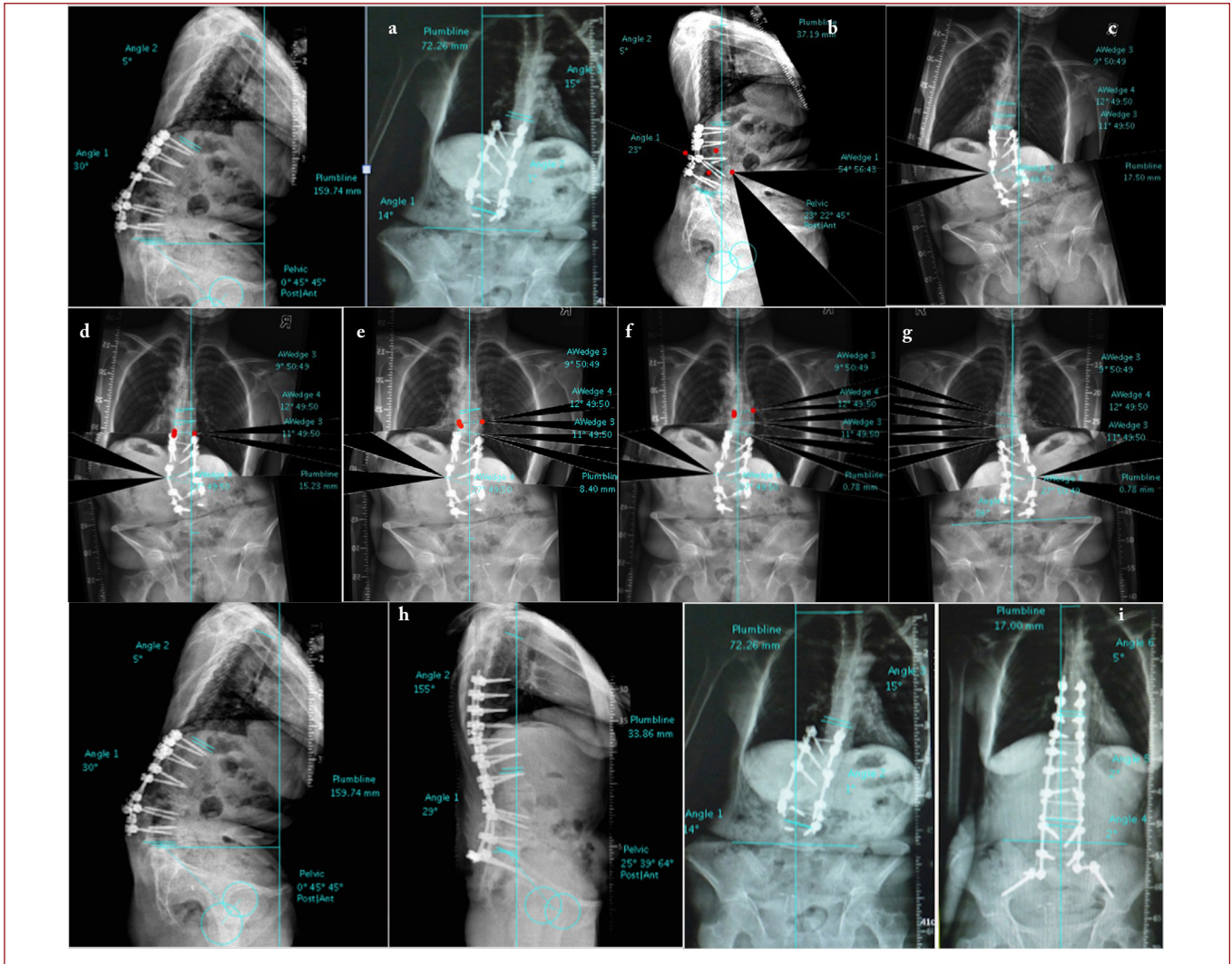


Figure-2.a) X-ray of 48-year-old female, who had been previously operated on for congenital kyphosis. Implant failure of the previous posterior instrumentation and pseudoarthrosis could be seen on X-rays, and the pelvic parameters were also abnormal; **b)** Simulation of one-level asymmetric PSO at the apex and two-level Smith-Petersen osteotomies at the adjacent levels, the program automatically makes the pelvic parametric changes; **c)** Simulation of osteotomies at the coronal plane, showing the effect of asymmetric PSO on the coronal plane; **e,f)** Three-level SPO at the adjacent upper levels; **g)** Scenario showing good coronal balance with these osteotomies; **h)** Postoperatively, excellent sagittal balance and ideal lordosis and kyphosis angles, but the pelvic parameters did not fully meet expectations; **i)** A good coronal balance can be seen here.

These osteotomies should obtain a good coronal balance.

After virtual osteotomy, the surgical plan was translated to the operating room, the osteotomy was performed and instrumentation was carried out.

The patient had excellent sagittal balance postoperatively and the lordosis and kyphosis angles were ideal, but the prediction of the pelvic parameters did not fully meet expectations (Figure-2.h,j).

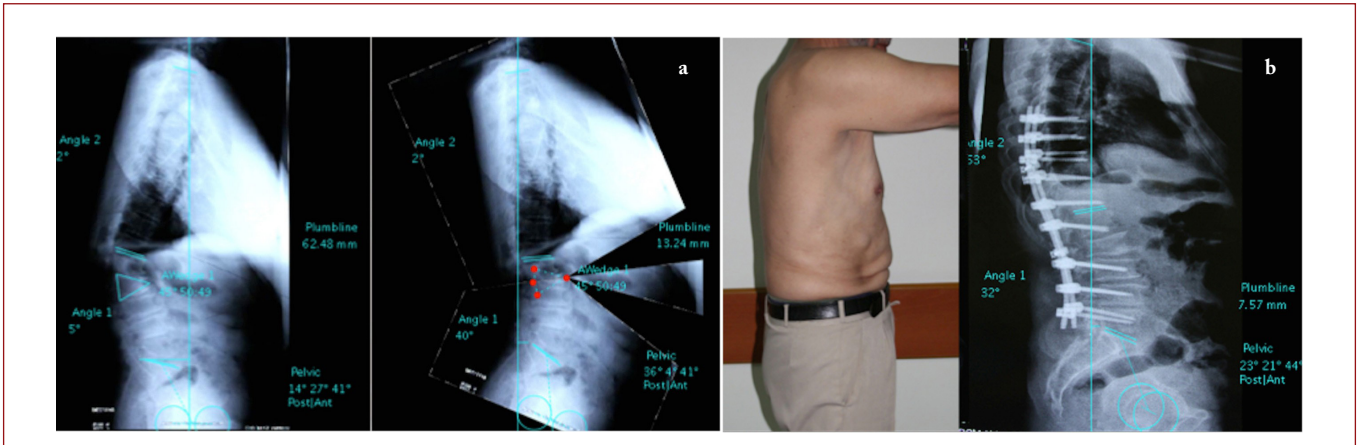


Figure-3.a) 65-year-old man, sequelae of a thoracolumbar fracture, the plan of an apical PSO and adjacent single or two-level SPO can be seen, showing that with three-level osteotomy, the pelvis and sagittal balance will be overcorrected; **b)** Postoperative X-rays showing the outcome after one PSO and one SPO.

Case sample 3:

The last patient was a 65-year-old male with sequelae of a thoracolumbar fracture. He had hypokyphosis and hypolordosis due to thoracolumbar junctional kyphosis.

The apex of the deformity was obviously visible so we planned a one-level PSO at the apical level and two SPOs at adjacent levels.

As seen on the X-rays of the virtual osteotomies, with a three-level osteotomy, the pelvis and sagittal balance seemed to be over-corrected (Figure-3.a)

However, we know that non-instrumented proximal levels of the spine are flexible, so this overcorrection should be compensated by the kyphosis of this part. Therefore, we performed one-level PSO and one-level SPO. The postoperative X-rays and clinical view of the patient are shown in Figure-3.b.

DISCUSSION

The balance of the body essentially depends on how far the head is to the midline.

Bridwell classified sagittal imbalance into type-1 and type-2². In type-1 imbalance, the patient has a segmental problem. Part of the spine is considerably hyperkyphotic, but the patient is able

to sustain balance by hyperextending the segments above and below. In type-2 imbalance, the regional hyperkyphosis is so great that the patient cannot achieve balance by hyperextending the segments above and below⁵.

Preoperative planning of osteotomies on sagittal plane deformities is crucial to predict the outcome of the surgery.

Osteotomy planning can be done in several ways. One way is to use paper templates of the long cassette X-rays for determining the appropriate place for wedge resection.

Simulation can also be performed computationally, using a program such as ASKyphoplan that was used by Van Royen for treating ankylosing spondylitis, or Surgimap Spine, which we used here. Both programs analyze and visualize the relationship between the angle and level of the osteotomy and the sagittal balance⁷.

In addition, the Surgimap Spine program can be used to simulate coronal plane osteotomies (Figure-2. c,d,e,f,g,h).

When the sagittal deformity is rigid, spinal osteotomies must be performed to balance the sagittal plane¹. There are several types of osteotomy available to obtain correction.

PSO offers nearly three times the correction at each level than SPO, but is burdened with increased technical demands, longer operative time, and greater blood loss and associated morbidity. Cho et al. reported that when comparing three or more SPOs with a single PSO, the kyphosis correction was nearly identical, but the improvement in the C7 plumb line was significantly better in the PSO group³.

They recommended the consideration of one or two SPOs in cases with a C7 plumb line that is in the range of +6 – +8 cm; however, for patients displaying a positive range of 12 cm or more, they recommended PSO.

They considered this large amount of balance correction by the PSO group as being due to such significant preoperative deformity. We favor PSO over SPO, as deformities were not seen to recover in fulcrum radiographs.

In both virtual and real osteotomy, we observed that the lower the level of the osteotomy performed in the lumbar region, the greater the impact on the sagittal vertical axis. As shown in the sample cases, moving an osteotomy to a lower level resulted in turn in increased improvement in the global balance (Figure-1.d,e).

Van Royen et al. stated that the effect of a spinal osteotomy on the correction of the horizontal gaze was directly proportional to the osteotomy angle, irrespective of the osteotomy level; however, this rule is only valid for ankylosing spondylitis patients⁶.

If all the segments of the spine were rigid, this rule would be valid for all patients; however, for most patients the deformity is flexible above and below the apex, and so the effect of the vertebral osteotomy is compensated by these moving segments, reducing the expected impact on the patient's gaze.

Considering the sample cases where the patients had flexible regions outside the apex, if the spinal regions outside the deformity were not instrumented, each of these segments compensated for the post-osteotomy condition proportionally to their

individual capacity for movement. This situation is demonstrated by the second sample case, when 5° of thoracic kyphosis improved to 25°, and in the third sample case, when 2° of thoracic kyphosis improved spontaneously to 27°.

For patients with ankylosing spondylitis, all the segments excluded from the spinal fusion related to the osteotomy showed a kyphosis condition in postoperative X-rays that was unchanged from the preoperative condition, and so computer-assisted planning became easier.

For patients that are flexible at the regions outside of the apex, the preoperative flexibility of the spine should be evaluated using the lateral bending on the AP radiograph and the fulcrum on the LAT radiograph, and the effects on the postoperative results should be anticipated accordingly.

We deduce that a program of this kind is useful in simulating the correction in an overall rigid spine, but cannot foresee the postoperative secondary flexibilities in regions outside of the deformity.

For spines with flexible segments, we saw that making an osteotomy simulation on the bending and traction radiographs allowed us to predict the movements at the adjacent segments that would occur in the post-osteotomy period.

In conclusion, the Surgimap Spine program is a useful tool for deformity correction planning and osteotomy simulation in a virtual environment.

REFERENCES

1. Atici Y, Sokucu S, Uzumcugil O, Albayrak A, Erdoğan S, Kaygusuz A. The results of closing wedge osteotomy with posterior instrumented fusion for the surgical treatment of congenital kyphosis. *Eur Spine J* 2013; 22(6): 1368–1374.
2. Bridwell KH. Decision making regarding Smith-Petersen vs. pedicle subtraction osteotomy vs. vertebral column resection for spinal deformity. *Spine* 2006; 31(19): 171–178.
3. Cho K J, Bridwell K H, Lenke G L, Berra B A, Baldus C. Comparison of Smith-Petersen versus pedicle subtraction osteotomy for the correction of fixed sagittal imbalance. *Spine* 2005; 30(18): 2030–2037.
4. Schwab F, Patel A, Ungar B, Farcy J P, Lafage F. Adult spinal deformity postoperative standing imbalance assessing alignment and planning corrective surgery *Spine* 2010; 35(25): 2224–2231.
5. Toyone T, Shioi R, Ozawa T, Inada K, Shirahata T, Kamikawa K, Watanabe A, Matsuki K, Ochiai S, Kaiho T. Asymmetrical pedicle subtraction osteotomy for rigid degenerative lumbar kyphoscoliosis. *Spine* 2012; 37(21): 1847–1852.
6. Van Royen BJ, De Gast A, Smith TH. Deformity planning for sagittal plane corrective osteotomies of the spine in ankylosing spondylitis *Eur Spine J* 2000; 9: 492–498.
7. Van Royen BJ, Scheerder FJ, Jansen E, Smith TH. ASKyphoplan. A program for deformity planning in ankylosing spondylitis. *Eur Spine J* 2007; 16(9): 1445–1449.