



Doğaç KARAGÜVEN<sup>1</sup>,  
İ. Teoman BENLİ<sup>2</sup>,  
Mehmet AYDOĞAN<sup>3</sup>

<sup>1</sup>Orthopedics and Traumatology Specialist, Ufuk University Medical School, Orthopedics and Traumatology Department, Ankara.

<sup>2</sup>Prof. Dr., Orthopedics and Traumatology Specialist, Hisar Intercontinental Hospital, Orthopedics and Traumatology Specialist Department Chief, İstanbul.

<sup>3</sup>Assoc. Dr., Orthopedics and Traumatology Specialist, Bosphorus Spinal Surgery Center, İstanbul.

**Address:** İ. Teoman Benli, Ortopedi ve Travmatoloji Uzmanı, Hisar Intercontinental Hospital, Ortopedi ve Travmatoloji Bölüm Başkanı, Siteyolu Sokak, No:7, İstanbul.

**Tel:** 0216 5241300 / 3175

**E-mail:** cutku@ada.net.tr

**Received:** 1st December, 2013

**Accepted:** 1st March, 2014

## RESULTS OF COMPLETE HEMIVERTEBRA EXCISION WITH A POSTERIOR APPROACH ALONE, FOLLOWED BY CIRCUMFERENTIAL FUSION AND POSTERIOR INSTRUMENTATION, IN PATIENTS WITH FULLY SEGMENTED AND UNINCARCERATED HEMIVERTEBRAE

### TAM SEGMENTE VE KİLİTLENMEMİŞ HEMİVERTEBRALI HASTALARDA SADECE POSTERİOR YAKLAŞIMLA TAM HEMİVERTEBREKTOMİ, SİRKÜMFERENSİYAL FÜZYON POSTERİOR KISA ENSTRÜMANTASYON SONUÇLARI

#### SUMMARY

**Objective:** To evaluate the results of surgical treatment of patients with an unincarcerated fully-segmented hemivertebra treated with hemivertebrectomy by a posterior approach alone, circumferential fusion and posterior segmental pedicular screw instrumentation.

**Study Design:** Twelve patients with a mean age of  $9.4 \pm 5.4$  (2–14) years were included in the study (6 girls and 6 boys). The mean duration of follow-up was  $59.4 \pm 39.6$  (24–132) months. Diagnosis of a Type-IA hemivertebra was established by clinical, radiological, CT and MRI evaluation. For all patients, hemivertebrectomy with a posterior approach alone, circumferential fusion and posterior segmental pedicular screw instrumentation were applied. Analysis of the frontal and sagittal planes using radiograms obtained preoperatively, postoperatively, and after a minimum period of two years was performed. The balance was analyzed clinically and radiologically by measurement of the lateral trunk shift (LT).

**Results:** The mean preoperative Cobb angle was  $5.5 \pm 23.4^\circ$ , and postoperatively a mean correction rate of  $89.4 \pm 14.4\%$  was obtained for the main curves ( $p=0.00$ ). The mean preoperative Cobb angle of the secondary curves was  $38.9 \pm 16.1^\circ$ , and postoperatively a mean correction rate of  $88.9 \pm 11.1\%$  was obtained for the secondary curves ( $p=0.00$ ). In the final follow-up, the mean loss of correction was  $3.2 \pm 3.3^\circ$ . The local segmented kyphosis decreased from  $24.4 \pm 14.9^\circ$  to  $7.7 \pm 5.7^\circ$ . The trunk shift (LT) of the patients was corrected for all patients (preoperative mean LT:  $3.3 \pm 2.1$  cm; postoperative mean LT:  $0.7 \pm 0.4$  cm). Circumferential fusion was achieved in all cases. No neurological complications developed, the only complication seen was delayed wound healing.

**Conclusion:** In the light of these data, we conclude that hemivertebrectomy by a posterior approach alone, circumferential fusion and posterior segmental pedicular screw instrumentation is an effective and safe technique for the treatment of unincarcerated fully-segmented hemivertebrae in all vertebral regions.

**Key words:** Congenital scoliosis, surgical treatment, and hemivertebra excision.

**Level of Evidence:** Retrospective clinical study, Level III

#### ÖZET

**Amaç:** Sadece posterior girişimle total hemivertebra eksizyonu ve segmenter pediküler vidalarla posterior enstrümantasyonunun etkinliği ve güvenliliğini araştırılması amaçlanmıştır.

**Hastalar ve Metot:** Bu çalışmada ortalama yaşları  $9,4 \pm 5,4$  (2-14) olup 6'sı erkek, 6'sı kız 12 hemivertebra hastaya sadece posterior girişimle total hemivertebra eksizyonu ve segmenter pediküler vidalarla posterior enstrümantasyon ve sirküferansiyel füzyon uygulanmış ve ortalama  $59,4 \pm 39,6$  (24-132) ay takip edilmiştir. Hastaların tamamına intraoperatif nöral monitorizasyon kullanılmıştır. Hastaların ana ve kompenzatuvar eğriliği ile lokal kifoz açıları ve lateral gövde kayması değerlendirilerek, preoperatif, postoperatif ve son kontrol değerleri karşılaştırılmıştır.

**Sonuçlar:** Ana eğriliğin ortalama preoperatif Cobb açıları  $55,5^\circ \pm 23,4^\circ$  olup, postoperatif istatistikî olarak anlamlı olarak şekilde  $\% 89,4 \pm 14,4$  korreksiyon sağlanarak ortalama  $15,5^\circ \pm 11,4^\circ$ 'e indiği belirlenmiştir ( $p:0,00$ ,  $t:7,1$ ). Kompenzatuvar eğriliği preoperatif ortalama  $38,9^\circ \pm 16,1^\circ$  iken  $\% 88,9 \pm 11,1$  düzelme sağlanarak  $9,3^\circ \pm 8,8^\circ$ 'ye düşmüştür. Lokal kifoz açısı ortalama  $24,4^\circ \pm 14,9^\circ$  iken  $7,7^\circ \pm 5,7^\circ$ 'ye inmiştir. Hem kompenzatuvar eğriliği hem de lokal kifoz açısındaki düzelme istatistikî olarak anlamlı bulunmuştur ( $p < 0.05$ ). Ana eğriliği ortalama 59,4 ay sonraki son kontrollerinde ortalama  $3,2^\circ \pm 3,3^\circ$  korreksiyon kaybı olduğu final korreksiyon oranları ile postoperatif korreksiyon oranlarının istatistikî olarak benzer olduğu belirlenmiştir ( $p > 0,05$ ,  $t:1,2$ ). Ortalama preoperatif LT değeri  $3,3 \pm 2,1$  cm iken postoperatif  $0,7 \pm 0,4$  cm'ye inmiş ( $p:0,00$ ) ve tüm hastalarda postoperatif denge tam olarak sağlanmıştır. Son kontrollerde gövde kayma değerlerinin değişmediği ve dengenin tüm hastalarda korunduğu belirlenmiştir. Hastaların hiç birinde nörolojik defisit olmamıştır. Ayrıca postoperatif erken ve geç komplikasyona rastlanmamıştır. Hastaların tamamında sirküferansiyel füzyon oluştuğu belirlenmiştir.

**Sonuç:** Bu çalışmanın verileri ışığı altında sadece posterior girişimle total hemivertebra eksizyonu ve segmenter pediküler vidalarla posterior enstrümantasyonunun uygulanması ile yüksek oranda düzeltme ve sirküferansiyel füzyonun sağlandığı, yöntemin etkin ve güvenli olduğu fikri elde edilmiştir.

**Anahtar Kelimeler:** Konjenital skolyoz, cerrahi tedavi, hemivertebrektomi

**Kanıt Düzeyi:** Retrospektif klinik çalışma, Düzey III

---

## INTRODUCTION

Hemivertebrae are the most common type of deformity and cause serious deformation and balance disturbances. Hemivertebrae at the lumbosacral joint, in particular, can cause pelvic tilting<sup>19</sup>. The growth pattern of hemivertebrae is unknown, and there have not been many studies. Generally, a cross-positioned hemivertebra results in a balanced deformity, but a single-sided fully-segregated and unincarcerated hemivertebra can result in progressive deformity. For patients with this type of deformity, progression peaks at the age of 2 and in the pre-adolescent period<sup>19,20</sup>.

As for most cases of congenital scoliosis, the gold standard for treatment is *in situ* fusion. Hemivertebrectomy was first implemented in 1928 by Royle, and has become popular again in the last few decades. Surgery must be performed before the development of compensatory thoracolumbar and thoracic deformities and pelvic tilt, especially in cases of lumbosacral and lumbar hemivertebrae<sup>1, 3, 17, 19, 29-32</sup>.

Hemivertebrectomy is performed by total removal of the 'Y'-shaped discs from the anterior and consecutive removal of the half vertebra from the posterior. Initially, correction of defects in young children after the removal of hemivertebrae was hard, as no suitable implants were available and so correction of the defect was attempted using positioning with body casts. Recently, by using the appropriate instrumentation for the appropriate ages, residual defects can be closed by instrumentation and high degrees of deformity correction can be achieved<sup>4,17,27</sup>. Initially, these processes were performed in two separate surgeries, but recently both interventions have been performed in the same session, either in two

steps or together<sup>1-3,7,8,9,16,28</sup>. In 2006, Benli et al., one of the authors of this paper, performed two-step surgery in the same session for 14 of 26 patients. During this surgical procedure, they first removed the anterior hemivertebral body by an anterior approach and the posterior hemivertebral body by a posterior approach, and then they performed circumferential fusion and correction using posterior instrumentation. 12 patients received surgery using a unique technique that had not before been published, in which first the posterior parts of the hemivertebra were removed using a posterior approach, and then the anterior parts of the hemivertebrae were removed by an anterior approach, followed by correction with anterior instrumentation and circumferential fusion<sup>1</sup>.

After pedicular segmented screws became available for all spinal deformities, it has recently become possible to remove the hemivertebra by a posterior approach alone, and to achieve better filling of the residual defect cavity and better correction rates without any neurological deficit<sup>27</sup>. Nakamura et al. compared the results of hemivertebrectomy by anterior and posterior intervention in a single session and total hemivertebrectomy with a posterior approach alone, and reported that correction rates and clinical results are statistically similar<sup>21</sup>.

In this study, the most commonly used technique, hemivertebrectomy by a posterior approach, circumferential fusion and short segmental instrumentation using posterior pedicular screws, was employed in the treatment of 12 patients with fully-segmented locked hemivertebrae, the clinical results were evaluated retrospectively, and the effectiveness and safety of the method was estimated.

---

## PATIENTS AND METHODS:

12 patients with a fully-segmented unincarcerated hemivertebra who were operated on by two of the authors of this article (T.B. and M.A.) were included in this study. The average age of the patients was  $9.4 \pm 5.4$  (2–14) years, and six patients were male and six were female.

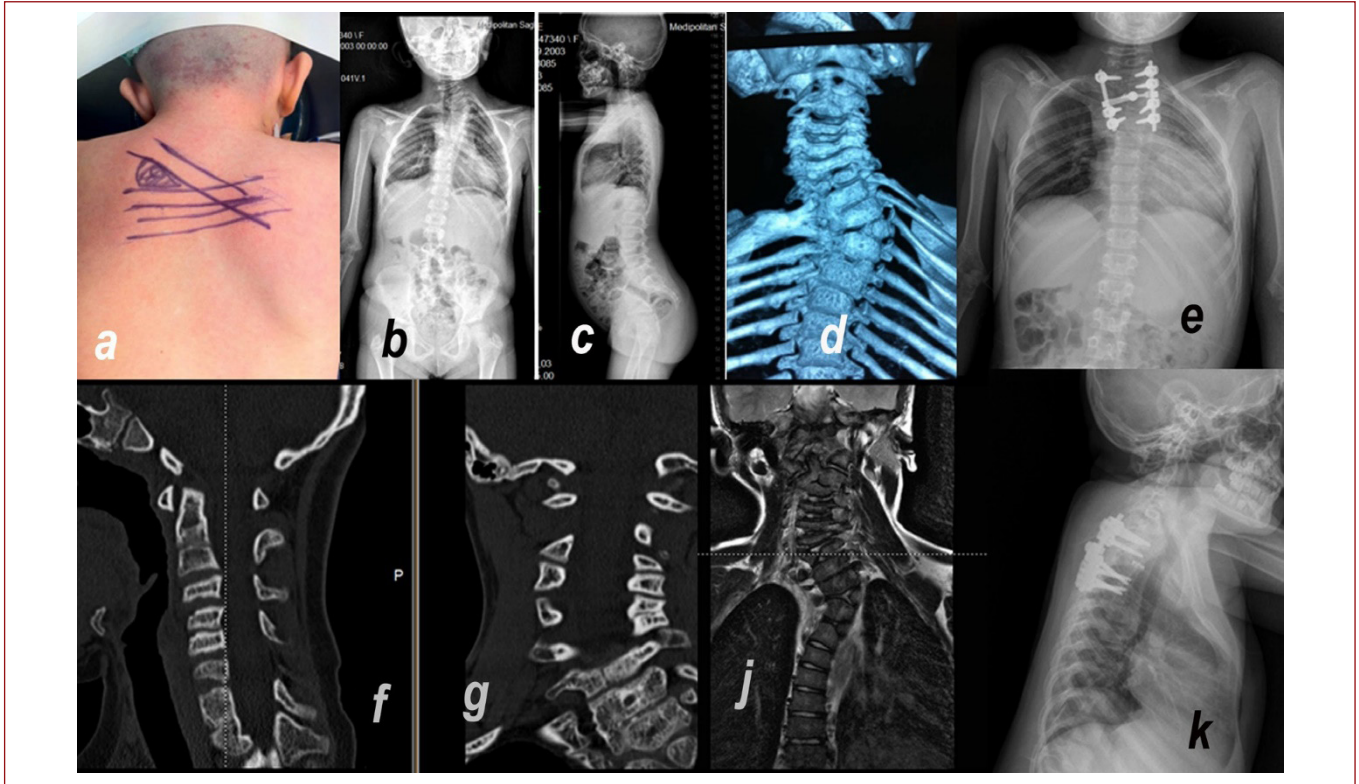
The patients were clinically evaluated, and standing postero-anterior, lateral, bending, and traction X-rays, and 3D computerized tomography of the affected region were performed. To detect the presence of additional vertebral abnormalities, a whole vertebral MRI was performed. To detect any cardiac and urinary system abnormalities, the appropriate studies and consultations were also demanded. For patients with a pure fully-segmented and unincarcerated hemivertebra, a total hemivertebrectomy from the posterior with circumferential fusion and posterior instrumentation was planned.

Surgery was performed in prone position by making an incision from the previously marked hemivertebral site, and neural monitorization was employed during surgery. First, pedicular screws were placed freehand to the consecutive upper and lower vertebrae bilaterally, and then the posterior parts were removed using a Kerrison rongeur, the roots were separated to reach the anterior, and the discs were completely excised until the adjacent vertebral spongy bones were reached. In five of the cases, where accompanying kyphotic deformities were present, supportive grafts were placed at the anterior part of the body. After that, the temporary screw below the hemivertebra was removed, and a screw one size larger was placed. Rods were placed, compression from the concave side and distraction from the convex side were performed gradually, and the defect at

the hemivertebral site was slowly and gradually corrected.

After the final correction, rods were placed and a rigid window was created with two cross bridges. After decortication, posterior fusion was performed using local autografts and circumferential fusion was established. On the second day postoperatively the patients were mobilized and no external support was used. Complications were only observed in a single patient, and there was no neurological deficit development.

The patients were followed up for a minimum of two years, for an average of  $59.4 \pm 39.6$  (24–132) months. The final follow-ups were performed in January 2014. The Cobb angles of the compensatory deformation and the local kyphosis angles were measured, preoperatively, postoperatively, and at the last follow-up. The lateral body shift (LT) at the apex of the deformity at the hemivertebral site was also calculated from X-rays taken preoperatively, postoperatively, and at the final follow-up. The averages of these values were analyzed using the SPSS 11.0 for Windows program, using a paired sample correlation test and a student t-test with  $p=0.05$ .



**Figure-1.** Patient Ş.A., a 10-year-old male, had an upper thoracic hemivertebra and a resulting upper thoracic 45° major deformity. **a)** Posterior view of the patient and planning, **b)** PA X-ray of the patient standing, **c)** lateral X-ray, **d)** 3D computerized tomography, **e,f)** computerized tomography images, **g)** frontal MRI, **j,k)** postoperative PA and lateral X-rays.

## RESULTS:

Two of the hemivertebra patients (16.7%) had an upper thoracic, seven (58.3%) had a lower thoracic, and three (25%) had a lumbar location. Major deformities were seen in the thoracic, thoracolumbar and lumbar regions with the given rates.

The average preoperative Cobb angle of the major deformity of the patients was  $55.5 \pm 23.4^\circ$ , and postoperatively the average Cobb angle reduced to  $15.5 \pm 11.4^\circ$ , showing that a correction of  $89.4 \pm 14.4\%$  was obtained, which had statistical significance ( $p=0.00$ ,  $t=7.1$ ). The preoperative average angle of compensatory deformity was  $38.9 \pm 16.1^\circ$ , and this reduced to  $9.3 \pm 8.8^\circ$ , showing  $88.9 \pm 11.1\%$  correction. Both the compensatory deformity and local

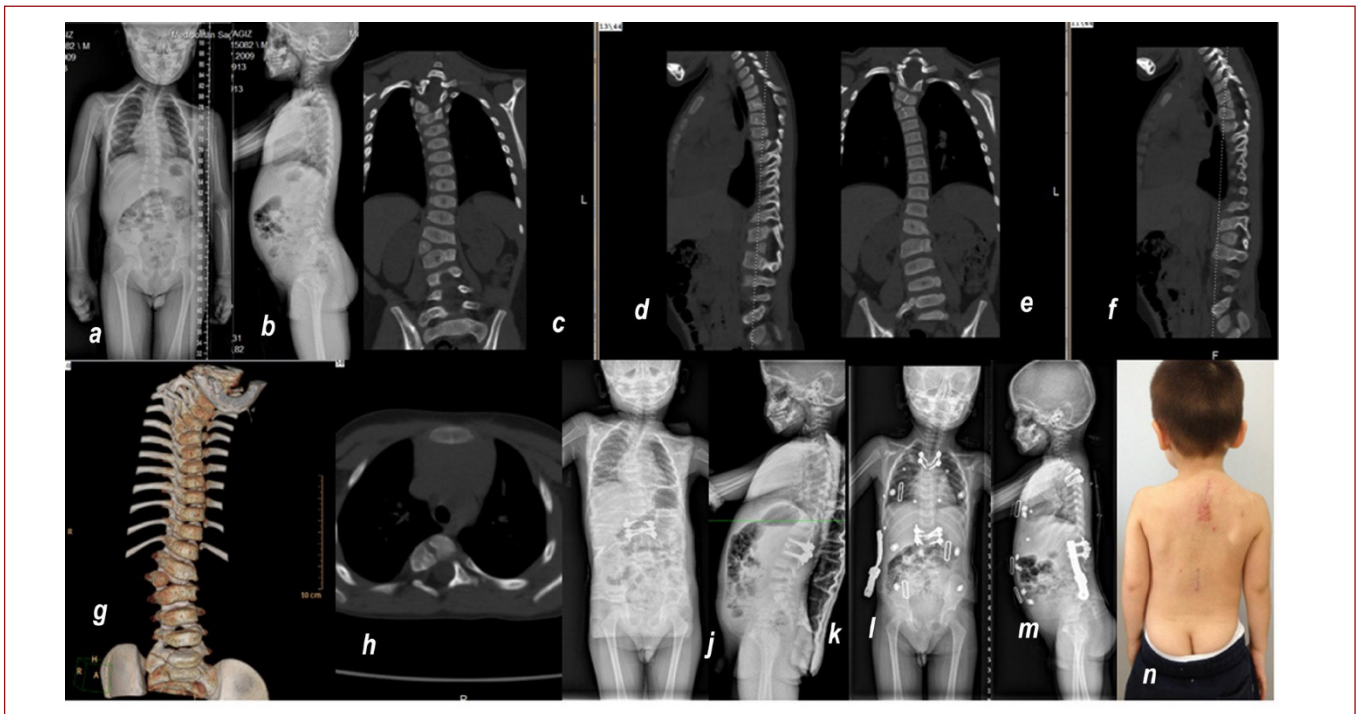
kyphosis angle reductions were statistically significant ( $p<0.05$ ). The loss of correction of the major deformity in the final follow-up, 59.4 months after surgery, was  $3.2 \pm 3.3^\circ$ , which was not found to be statistically significant ( $p>0.05$ ,  $t=1.2$ ). The average preoperative LT value was  $3.3 \pm 2.1$  cm, which reduced postoperatively to  $0.7 \pm 0.4$  cm ( $p=0.00$ ), and balance was obtained for all patients postoperatively. At the final follow-up, it was determined that the body shift values had not changed and the balance was preserved for all patients.

None of the patients developed neurological deficits, and no postoperative early or late complications were observed. It was observed that circumferential fusion developed in all of the patients.

## DISCUSSION:

One of the surgical treatment options for scoliosis resulting from a hemivertebra is hemivertebrectomy. This was first described by Royle in 1928<sup>19</sup>. Compere published the first results of hemivertebrectomy in 1932<sup>5</sup>. This method was abandoned for a long time due to high morbidity rates, the development of

neurological deficits, and an inability to correct defects that occurred after hemivertebrectomy and non-fusion<sup>8,29-32</sup>. A few decades ago, Leatherman and Dickson re-popularized the method<sup>17</sup>, and many studies have subsequently reported good results of anterior and posterior hemivertebra excision, in either a single or two separate sessions<sup>3,10,15,21</sup>.



**Figure-2.** Patient Y.A., a 4-year-old male, had upper thoracic and thoracolumbar hemivertebrae. Both hemivertebrae were resected in two different sessions by a posterior approach. **a)** Standing PA X-ray of the patient, **b)** lateral X-ray, **c,d,e,f)** computerized tomography images, **g)** 3D tomography images, **h)** axial MRI, **j,k)** postoperative PA and lateral X-rays, **l,m)** last follow-up AP and lateral X-rays, **n)** posterior image of the patient at the last follow-up.

Holte et al. reported the application of posterior instrumentation to 28 of the 38 patients that they operated on, and for the patients who received instrumentation, the deformities were reduced to an average of 33° from 54°, and all patients attained body balance<sup>10</sup>. In a ten-patient series by Deviren et al., a 59% correction rate was published,<sup>7</sup> and Callahan et al. showed 45% reduction with a single-step and 55%

reduction with a two-step procedure<sup>4</sup>. Klemme et al. reported the follow-up of six children treated with combined hemivertebrectomy with an anterior and posterior approach in a single session, and showed that there was a 70° reduction in the major deformity, and with the use of appropriate instrumentation this technique can be used for small children<sup>15</sup>.

---

Bradford and Boachie-Adjei showed that with combined anterior-posterior hemivertebrectomy, an average correction of 70% can be obtained, and during an average of 45.6 months follow-up, an average of 1° of correction was lost<sup>3</sup>. King and Lowery, in a seven-patient series, reported that a preoperative major deformity of 29.7° was reduced to an average of 18° at the last follow-up<sup>14</sup>. Lazar and Hall, in an 11-patient series, reduced an average preoperative major deformity of 47° to 14° postoperatively using a combined anterior-posterior hemivertebrectomy approach; Hall et al. also used the same method and observed the reduction of deformity from 54° to 33°<sup>8,16</sup>.

Benli et al., one of the authors of this paper, performed combined anterior and posterior hemivertebrectomy in the same session for 26 patients. Nearly half of these patients were treated with anterior instrumentation with the Cotrel-Dubouset-Hopf (CDH) double rod technique after hemivertebrectomy instead of posterior instrumentation, for the first time in the literature. The remaining patients were treated with regular posterior instrumentation. For the groups receiving anterior and posterior instrumentation, 60.7% and 67.5% correction was obtained, respectively, with statistical significance, and less segments were instrumented during the anterior approach. After surgery, 80.8% of the patients were totally balanced and had clinically balanced vertebrae<sup>1</sup>.

Recently, after segmental pedicular systems have become available, total hemivertebrectomy with a posterior approach, circumferential fusion and posterior pedicular fixation have become popular. Shono et al. published the first posterior hemivertebrectomy<sup>27</sup>. In 2001, Shono et al. reported a series of 12 patients who received

hemivertebrectomy with a posterior approach, and they reported 64% correction without neurological deficits or pseudoarthrosis, and at the final follow-up an average loss of correction of 2° was observed. They proposed that this method was an efficient and safe method. They also pointed out that the preoperative average body shift was reduced from 23 mm to 3 mm postoperatively, and that all patients had balanced vertebrae<sup>27</sup>. Ruf and Harms (24-25) and Nakamura et al.<sup>19</sup> published their results with this technique in 2002.

In 2008, Liu et al. performed posterior hemivertebrectomy for 24 patients with an average age of 9.4 years, and reported 61.5% correction without any neurological deficits<sup>18</sup>. In 2009, Hedequist et al. reported a decreased Cobb angle, from an average of 44° to 8°, for ten patients who received hemivertebrectomy with a posterior approach and double rod application to the concave side<sup>9</sup>. In 2009, Ruf et al. reported a decrease in the major deformity from 69° to 23° in 41 congenital scoliosis patients, and also a spontaneous decrease in the caudal secondary deformity from 15° to 3° and a decrease in the local kyphosis angle from 22° to 8°<sup>26</sup>.

In 2011, Zhang et al., in a study including 59 hemivertebra patients aged from 1.5–1.7 years showed 72.9% correction, the local kyphosis angle decreased from 42° to 14.5°, and a residual defect was only observed in five patients<sup>34</sup>. In the same year, Peng et al. published the use of the same method for two patients, and reported correction of the major deformity, compensatory deformity and segmental kyphosis by 65.9%, 62.8%, and 78.1%, respectively<sup>23</sup>. In the same year, Yazsay et al. reported the results of 66 cases over two years in a multicentric study. When in situ fusion and convex epiphysiodesis were

---

compared, they proposed that hemivertebra excision had a higher complication rate<sup>33</sup>.

In 2012, Jerzenksy et al. reported very good results after 16 years of surveillance for a fusion-less hemivertebrectomy patient<sup>11</sup>. In the same year, Sun et al., in a study including 44 hemivertebra patients aged 2–17 years, compared hemivertebrectomy with posterior approach alone and stepwise anterior-posterior hemivertebrectomy with instrumentation, and showed that they have similar clinical results, although in rigid cases, in particular, hemivertebrectomy with an anterior-posterior approach must be preferred<sup>28</sup>.

Karami et al. published a clinical series of ten patients from Iran in 2013. They performed hemivertebrectomy with a posterior approach, and in the major deformity and local kyphosis saw 72.5% and 90% correction, respectively<sup>12</sup>. Obeid et al. published a study in the same year stating that hemivertebrectomy with a posterior approach alone could be safely employed in the thoracic region<sup>22</sup>. In our study, this technique is safely and successfully implemented in the thoracic and cervicothoracic regions.

Finally, at the beginning of 2014, Crostelli et al. published a series that included 15 children under the age of 10 who were surveyed for at least three years. They reported 75% correction of the major deformity with no major complications in any of the patients<sup>6</sup>. In another study in 2014, Zhu et al. published the results of 60 hemivertebra patients treated with hemivertebrectomy with a posterior approach alone. They reported correction of 87.3%, a decrease in body tilt and 70.1% correction of segmental local kyphosis, with no neurological deficits<sup>35</sup>.

In our study, the major deformity correction was 89.4%, with statistical significance ( $p=0.00$ ), and the compensatory deformity correction was  $9.3^\circ$ , which is 88.9%. The local segmental kyphosis angle decreased from an average of  $24.4^\circ$  to  $7.7^\circ$ . The corrections of both the local kyphosis and compensatory deformity were statistically significant ( $p<0.05$ ). An average of 59.9 months after surgery, the loss of correction of the major deformity was  $3.2^\circ$ , and the final and postoperative correction rates were statistically similar ( $p>0.05$ ). The average postoperative LT values decreased to 0.7 cm from 3.3 cm ( $p=0.00$ ), and for all patients balance was fully established postoperatively. At the final follow-up, the body tilt values had not changed and the balance was preserved. None of the patients developed neurological deficits, and no postoperative early or late complications were observed.

Crankshaft phenomenon are not observed on hemivertebrae excision, as this process allows circumferential fusion<sup>19,31</sup>. Kesling et al. and Winter reported pseudoarthrosis occurring in small children due to residual cavities that could not be filled<sup>13,29-32</sup>. However, after correction with instrumentation and use of segmental pedicular screws, in particular, there were cases of pseudoarthrosis in all of the studies<sup>3,4,7,8,10,15,16,21-27</sup>. In our study, in the final follow-up, solid fusion was observed in all of the 12 patients.

In some studies, use of a concave single rod has been reported<sup>23</sup>. However, in this study, the development of a rigid window by connecting two rods crosswise was preferred. We also believe that distractive movements on the convex rod are helpful for filling the defect cavity left after hemivertebrectomy.

Based on the results of this study, total

hemivertebra excision with a posterior approach, together with posterior instrumentation using segmental pedicular screws, shows high rates of correction and circumferential fusion. We conclude that this method is efficient and safe.

## REFERENCES

1. Benli IT, Aydın E, Üzümcügil O, Büyükgöllü O, Kış M. Results of complete hemivertebra excision followed by circumferential fusion and anterior or posterior instrumentation in patients with type-IA formation defect. *Eur Spine J* 2006; 15(8): 1219-1229.
2. Bergoin M, Bollini G, Taibi L, Cohen G. Excision of hemivertebrae in children with congenital scoliosis (Abstract). *Ital J Orthop Traumatol* 1986; 12(2): 179 –184.
3. Bradford DS, Boachie-Adjei O. One stage anterior and posterior hemivertebral resection and arthrodesis for congenital scoliosis. *J Bone Joint Surg* 1990; 72-A: 536–540.
4. Callahan BC, Georgopoulos G, Ellert RE (1997). Hemivertebral excision for congenital scoliosis. *J Pediatr Orthop* 1997; 17: 96 – 99.
5. Compere EL. Excision of hemivertebrae for correction of congenital scoliosis. *J Bone Joint Surg* 1932; 14 – A: 555 – 560.
6. Crostelli M, Mazza O, Mariani M. Posterior approach lumbar and thoracolumbar hemivertebra resection in congenital scoliosis in children under 10 years of age: results with 3 years mean follow up. *Eur Spine J* 23(1): 209-215.
7. Deviren V, Beveren S, Smith JA, Emami A, Hu SS, Bradford DS. Excision of hemivertebrae in the management of congenital scoliosis involving the thoracic and thoracolumbar spine. *J Bone Joint Surg* 2001 ; 83-B: 496–500.
8. Hall JE, Herndon WA, Levine CR. Surgical treatment of congenital scoliosis with or without Harrington instrumentation. *J Bone Joint Surg* 1981 63 A: 608 – 619.
9. Hedequest D, Emans J, Proctor M. Three technique facilities hemivertebra wedge excision in young children through a posterior only approach. *Spine* 2009; 34(6): E225-229.
10. Holte DC, Winter RB, Lonstein JE, Denis F. Excision of hemivertebrae and wedge resection in the treatment of congenital scoliosis. *J Bone Joint Surg* 1995; 77-A: 159-164.
11. Jeszenszky D, Fekete TF, Kleinstueck FS, Haschtmann D, Bognar L. Fusionless posterior hemivertebra resection in a 2-years-old child with 16 years follow-up. *Eur Spine J* 2012; 21(8): 1471-1476.
12. Karami M, Esmailiajah MKAA, Kazami MKM, Safdari F. The outcome of hemivertebrectomy through a posterior only approach in lumbar congenital scoliosis. *Iranian J Orthop Surg* 2013; 11(2): 43-50.
13. Kesling KL, Lonstein JEA, Denis F, Perra JH, Schwender JD, Transfeldt EE, Winter RB. Crankshaft phenomenon after posterior spinal arthrodesis for congenital scoliosis: a review of 54 patients. *Spine* 2003; 28(3): 267–271.
14. King JD, Lowery GL. Results of lumbar hemivertebral excision for congenital scoliosis. *Spine* 1991; 16: 778 – 782.
15. Klemme WR, Polly DW, Urchowski JR. Hemivertebral excision for congenital scoliosis in very young children. *J Pediatr Orthop* 2001; 21 (6): 761 – 764.
16. Lazar RD, Hall JE (1999). Simultaneous anterior and posterior hemivertebra excision. *Clin Orthop* 364: 76 – 84.
17. Leatherman KD, Dickson RA. Two stage correction surgery for congenital deformities of the spine. *J Bone Joint Surg* 1979; 61-B (3): 324-328.
18. Li X, Luo X, Tao H, Du J, Wang Z. Hemivertebra resection for the treatment of congenital lumbar spinal scoliosis with lateral-posterior approach. *Spine* 2008; 33(18): 2001-2006.



- 
19. Lubicky JP. Congenital scoliosis. In: Bridwell K, DeWald RL (eds) *The Textbook of Spinal Surgery*. 2<sup>nd</sup> Ed., Lippincott – Raven Publishers, Philadelphia, 1997; pp: 345–364.
  20. McMaster MJ, Singh H. Natural history of congenital kyphosis and kyphoscoliosis. A study of one hundred and twelve patients. *J Bone Joint Surg* 1999; 81-A(10): 1367–1383.
  21. Nakamura H, Matsuda H, Konishi S, Yamano Y. Single-stage excision of hemivertebrae via the posterior approach alone for congenital spine deformity: follow-up period longer than ten years. *Spine* 2002; 27(1): 110115.
  22. Obeid I, Bourghli A, Vital JM. Thoracic hemivertebra resection by approach for congenital scoliosis. *Eur Spine J* 2013; 22(3): 678–680.
  23. Peng X, Chen L, Zou X. Hemivertebra resection and scoliosis correction by a unilateral posterior approach using single rod and pedicle screws instrumentation in children under 5 years old. *J Pediatr Orthop* 2011; 20(6): 397–403.
  24. Ruf M, Harms J. Hemivertebra resection by a posterior approach innovative operative technique and first results. *Spine* 2002; 27 (10): 116 – 1123.
  25. Ruf M, Harms J. Posterior hemivertebra resection with transpedicular instrumentation: early correction in children aged 1 to 6 years. *Spine* 2003; 28(18): 2132–2138.
  26. Ruf M, Jansen R, Letko L, Harms J. Hemivertebra resection and osteotomies in congenital spine deformity. *Spine* 2009; 34(17): 1791–1799.
  27. Shono Y, Abumi K, Kaneda K. One-stage posterior hemivertebra resection and correction using segmental posterior instrumentation. *Spine* 2001; 26: 752–757.
  28. Sun W, Zhang JG, Qiu GX, Wang SR, Zhao YJ, Zjao LJ. Comparison of two techniques in hemivertebra resection: anterior-posterior approach versus posterior approach. *Zhonghua Yi Xue Za Zhi* 2012; 92(11):756– 759 (İngilizce abstract).
  29. Winter RB, Moe JH, Lonstein JE. Posterior spinal arthrodesis for congenital scoliosis. An analysis of the cases of two hundred and ninety patients five to nineteen years old. *J Bone Joint Surg* 1984; 66 – A: 1188 – 1197.
  30. Winter RB, Lonstein JE, Denis F, Sta – Ana de la Rosa H. Convex growth arrest for progressive congenital scoliosis due to hemivertebrae. *J Pediatr Orthop* 1988; 8: 633–638.
  31. Winter RB. Congenital scoliosis. *Orthop Clin North Am* 1988; 19: 395–408.
  32. Winter RB. Congenital Scoliosis: the role of anterior and posterior fusion. *J Turk Spine Surg* 1994; 5(3): 81.
  33. Yazsay B, O’Brein M, Shufflebarger HL, Betz RR, Lonner B, Shah SA, Boachie-Adjei O, Crawford A, Letko L, Harms J, Gupta MC, Sponseller PD, Abel MF, Flynn J, Macagno A, Newton PO. Efficacy of hemivertebra resection for congenital scoliosis: a multicenter retrospective comparison of the three surgical techniques. *Spine* 2011; 36(24): 2052–2060.
  34. Zhang J, Shengru W, Qiu G, Yu B, Yipeng W, Luk KD. The efficacy and complications of posterior hemivertebra resection. *Eur Spine J* 2011; 20(10): 1692–1702.
  35. Zhu X, Wei X, Chen J, Li C, Li M, Qiao Y, Ran B. Posterior hemivertebra resection and monosegmental fusion in the treatment of congenital scoliosis. *Ann R Coll Surg Engl* 2014; 96(1): 41–44.
-

