



MEASUREMENT OF ANTERIOR ATLANTODENTAL INTERVAL IN ADULTS WITH COMPUTERIZED TOMOGRAPHY

ERİŞKİNLERDE ÖN ATLANTODENTAL MESAFENİN BİLGİSAYARLI TOMOGRAFİ İLE ÖLÇÜMÜ

Selçuk ÖZDOĞAN¹,
Murat KÖKEN²,
Yusuf Emrah GERGİN³,
Serdar Onur AYDIN³,
Ebru YÜCE⁴,
Mehmet TİRYAKI¹,
Necati TATARLI¹,
Hikmet Turan SÜSLÜ¹,
Tufan HİÇDÖNMEZ⁵

¹Neurosurgery Specialist, Kartal Dr.Lütfi Kırdar Training and Research Hospital, İstanbul,

²Orthopedics and Traumatology Specialist, Gazi State Hospital, Samsun,

³Neurosurgery Assistant Dr., Kartal Dr.Lütfi Kırdar Training and Research Hospital, İstanbul,

⁴Private Akropol Hospital, Ankara.

⁵Assoc. Dr., Neurosurgery Specialist, Kartal Dr.Lütfi Kırdar Training and Research Hospital, İstanbul,

Address: Selçuk ÖZDOĞAN,
Beyin ve Sinir Cerrahisi
Uzmanı, Kartal Dr.Lütfi Kırdar
Eğitim ve Araştırma Hastanesi,
Cevizli, Kartal / İstanbul.

Tel: 0506 7637173

Fax: 0216 5784965

E-mail: drselcukozdogan@hotmail.com

Received: 12nd May, 2014

Accepted: 14th July, 2014

SUMMARY

Objective: The aim of this study is to determine the normal value range of the anterior atlantodental interval in adults.

Materials and Methods: 100 adult patients (50 females and 50 males), who had no trauma in the craniocervical junction and no rheumatological or infectious diseases affecting this region, were selected for this study by reviewing their files retrospectively. Sagittal cervical computerized tomography images were used for measurement of the midline anterior atlantodental interval. Numerical data were presented as mean and standard deviation. The Mann-Whitney U test was used for comparisons between independent groups. The PASW Statistics v18 program was used for statistical analysis.

Results: The mean age was 39.31 ± 11.55 years for male patients and 41.0 ± 13.17 years for females. There were no statistically significant differences between the genders in terms of age. The mean anterior atlantodental interval was 1.47 ± 0.29 mm for males and 1.51 ± 0.25 mm for females. Comparisons between the groups revealed no statistically significant differences in the anterior atlantodental interval between men and women.

Conclusion: If the anterior atlantodental interval is measured as >2 mm, pathologies must be investigated and precautions must be taken for craniocervical junction stability.

Key words: Atlantodental interval, craniocervical junction, atlantodental morphometric measurement

Level of evidence: Retrospective clinical study, Level III

ÖZET

Amaç: Erişkinlerde ön atlantodental mesafenin normal değer aralığının belirlenmesidir.

Materyal-metod: Kranioservikal bileşke veya kafa travması geçirmemiş, bu bölgeyi etkileyecek romatolojik veya enfeksiyon hastalıkları olmayan 50 erkek ve 50 kadın erişkin hasta, çalışma için dosya taraması ile retrospektif olarak seçilmiştir. Servikal bilgisayarlı görüntüleme kayıtlarından sagittal kesitte atlantodental aralığın orta hat en geniş mesafeleri ölçüldü. İstatistiksel veriler ortanca değerler ve standart sapmalar ile sunulmuştur. Gruplar arasındaki karşılaştırmalarda Mann-Whitney U testi kullanılmıştır. İstatistikî analizde PASW Statistics v18 programı kullanılmıştır.

Sonuçlar: Yaş ortanca değeri erkekler için 39.31 ± 11.55 , kadınlar için ise 41.0 ± 13.17 olarak hesaplanmıştır. Cinsiyetler arasında yaş bakımından anlamlı bir fark yoktur. Ön atlantodental mesafe ortanca değeri erkekler için 1.47 ± 0.29 mm, kadınlar için 1.51 ± 0.25 mm olarak hesaplanmıştır. Cinsiyetler arasında Ön atlantodental mesafe değeri yönünden istatistiksel anlamlı bir fark bulunamamıştır.

Çıkarım: Bu çalışmanın verilerine göre ön atlantodental mesafe erişkinlerde 2mm den fazla ölçülmüş ise kranioservikal bileşke patolojileri yönünden araştırılması ve bu yönde tedbirlerin alınması gerektiği fikri elde edilmiştir.

Anahtar Kelimeler: Atlantodental mesafe, kranioservikal bileşke, atlantodental morfometrik ölçüm

Kant Düzeyi: Retrospektif klinik çalışma, Düzey III

INTRODUCTION:

Although the craniocervical junction is the most mobile segment of the spine, it is the least stable region¹. In this region, fractures, dislocations, and fractured dislocations are frequently observed after trauma^{7,13}. The atlantodental distance was defined by Hinck and Hopkins in 1960⁶. Direct X-rays are often used to

evaluate the atlantodental distance for anterior and lateral distances¹⁵. If there is a suspicion of pathology, computerized tomography (CT) is used. CT is the most valuable method for measurement of the atlantodental distance. Ligament and spinal cord injuries with atlantodental pathologies can be observed clearly with magnetic resonance imaging (MRI)¹⁴.

While the atlantodental distance was being measured, the anterior and lateral distances were also measured. However, evaluations were mostly performed from the anterior distance, as the lateral distances can be asymmetrical without any pathology². The normal adult anterior atlantodental distance (ADI) values have been reported as ≤ 3 mm in males and ≤ 2.5 mm in females⁶. It has been stated that values greater than these values should be evaluated pathologically and patients should be strictly monitored and treated.

In our study, the ADI was measured using CT in 100 adult patients that were admitted due to reasons other than cervical or head trauma, and the values were evaluated.

MATERIALS AND METHODS:

50 male and 50 female patients were included in this study. The patients had no cervical or head trauma, or rheumatic diseases. The patient data were obtained retrospectively by screening patient files and radiological data.

Midline sagittal sections were evaluated in CT examinations of the patients, and the widest midline ADI value was taken as the base value (Figure-1). It is possible to observe the 3D atlantodental distance by processing thin-section CT images (Figure-2).

Statistical results were presented as the mean and standard deviation. Comparisons between the groups were carried out with the Mann-Whitney U test. Statistical analysis was performed with the PASW Statistics v18 program. P-values less than 0.05 were accepted as statistically significant for between-group comparisons.

RESULTS:

The mean age was 39.31 ± 11.55 years in males and 41.0 ± 13.17 years in females. There was no significant difference between the genders in terms of age ($p=0.344$) (Table-1). The mean

ADI value was 1.47 ± 0.29 mm in males and 1.51 ± 0.25 mm in females. There was no statistically significant difference between the genders in terms of the ADI value ($p=0.585$) (Table-1).

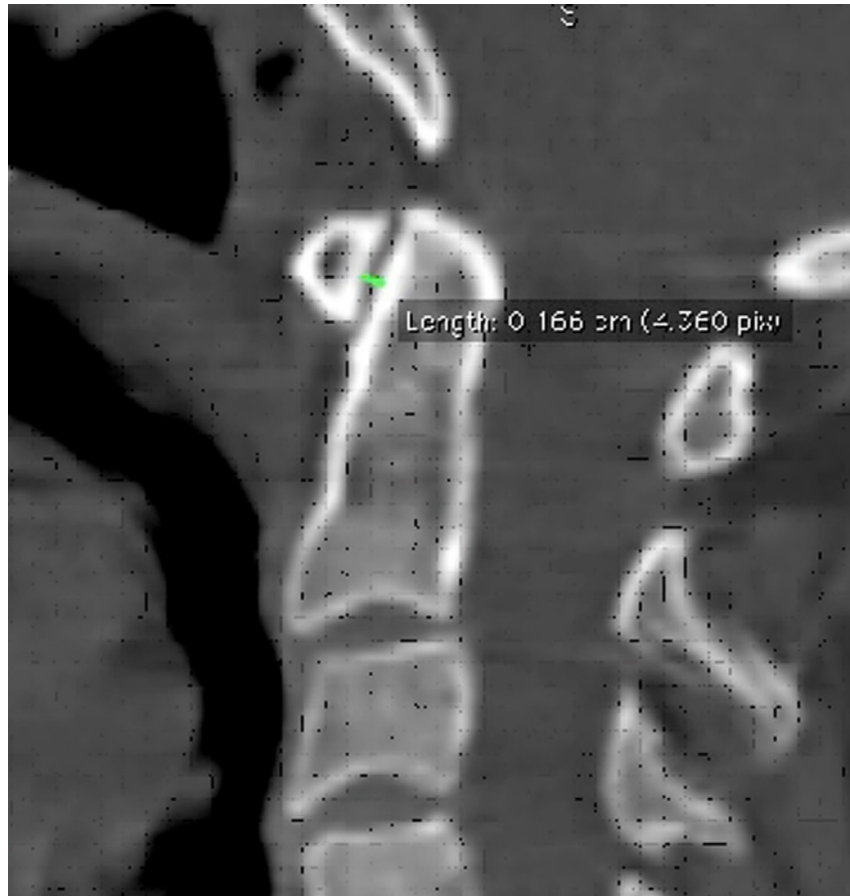

Figure-1. Measurement of the atlantodental distance in cervical CT sagittal images

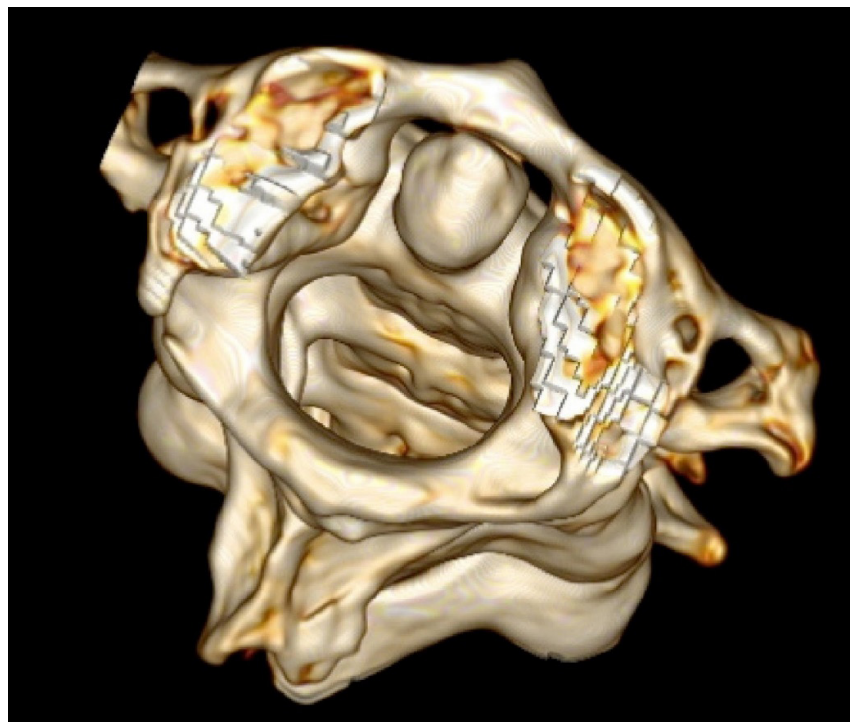


Figure-2. 3D image of the atlantodental distance in a thin-section CT

Table-1. Statistical data analysis of the anterior atlantodental distance

	Male		Female		p
	Mean	Standard dev.	Mean	Standard dev.	
AGE	39.31	11.55	41.00	13.17	0.344
ATLANTODENTAL DISTANCE (mm)	1.47	0.29	1.51	0.25	0.585

DISCUSSION:

The craniocervical junction is a complicated structure formed by the connection of the occipital bone, occipital condyles, and the cervical first and second vertebrae⁵. Ligaments in this region provide stability of the junction¹⁴. Mortality can occur due to compression caused by fractures and dislocations that develop as a result of trauma to this region, as it is adjacent to the brain stem and spinal cord^{7,13}. Although many dense fractures can be treated by conservative methods with a halo and cervical collar, some require surgical treatment^{5,8}. Therefore, thorough evaluation of the atlantodental distance, acquisition of anamnesis, and the performance of a detailed neurological examination are required. Radiological evaluations should be carefully examined in addition to these data, and then the treatment option should be selected.

The atlantodental distance was first defined by Hinck and Hopkins in 1960⁶. The ligaments holding the atlantodental structure in place were described as the atlantodental ligaments, dental ligaments, alar ligaments, and transverse ligaments. There are four measurement values of the atlantodental distance: anterior, posterior, and right and left lateral. In radiological evaluations, the anterior distance is easily observed in lateral sections. The right and left laterals can be observed as openings in anterior-

posterior X-rays. The best measurements are performed using thin-section cervical CT, as many structures in the atlantodental region can be observed in direct X-ray images¹². MRI can be also used for measurement, and ligamentous structures are clearly observed. One of the most commonly used distances is the anterior atlantodental distance. Many variations can be observed, as the right and left laterals can be asymmetric without pathology. The normal ADI values are ≤ 3 mm in males and ≤ 2.5 mm in females.

In a study using CT that included 500 Chinese adults, Chen et al. reported the ADI value as 1.83 ± 0.46 mm in males and 1.63 ± 0.43 mm in females. They also stated that the distance was significantly lower in females than in males⁴. In addition, it was emphasized that the atlantodental distance could be asymmetric without any pathology. In a study using CT that included 200 adult patients, Rojas et al. measured the ADI in the sagittal plane and found the normal value to be < 2 mm¹¹. No difference between the genders was found in the study. We also obtained similar results in our study.

Studies have evaluated the atlantodental distance using direct radiographs. Osmotherly et al. measured the atlantodental distance according to gender age groups in 269 lateral cervical X-rays^{9,10}.

As a result, they reported that the distance decreased with age and there was no relationship between the distance length and gender.

In a morphometric study, Çapar et al. measured ADI using MRI, and found a mean measurement of 1.40 ± 0.29 mm³. That study also stated that the distance was significantly higher in males.

In conclusion, the ADI measurement is no more than 3 mm in males or females, according to the literature. Statistically different studies are available, in terms of age and gender. According to the results of our study, the ADI measurement was found to be <2 mm, regardless of gender, and this shows parallels with the literature. If the anterior atlantodental distance is measured as >2 mm in adults, caution should be taken.

REFERENCES

1. Banerjee A, Clayton-Jolly A, Mbamalu D. The radiological assessment of injuries to the atlantoaxial occipital complex (C1 and C2 vertebrae). *Trauma* 2008; 10: 231-238.
2. Borders HL, Jenwick JJ, Sherwood JM, Macke MR. Pediatric lateral atlantodental interval: How much asymmetry is normal? *J Comput Assist Tomogr* 2011; 35: 557-559.
3. Capar B, Benli İT, Güclü B, Camuscu S, Ozsecen CT. Erişkinde MR görüntüleme ile odontoid çıkıntı morfometrisi ve atlantoaksiyel mesafe değerlendirilmesi. *The Journal of Turkish Spinal Surgery* 2011; 22(3): 165-172.
4. Chen Y, Zhuang Z, Qi W, Yang H, Chen Z, Wang X, Kong K. A three-dimensional study of the atlantodental interval in normal Chinese population using reformatted computed tomography. *Surg Radiol Anat* 2001; 33: 801-806.
5. Goel A, Phalke U, Cacciola F, Muzumdar D. Atlantoaxial instability and retroodontoid mass – two case reports-. *Neurol Med Chir* 2004; 44: 603-606.
6. Hinck VC, Hopkins CE. Measurement of the atlantodental interval in the adult. *Am J Roentgenol Radium Ther Nucl Med* 1960; 84:945-51.
7. Jiang LS, Shen L, Wang W, Wu H, Dai LY. Posterior atlantoaxial dislocation without fracture and neurologic deficit: a case report and the review of literature. *Eur Spine J* 2010; 19 (Suppl. 2): 118-123.
8. Moon MS, Choi WT, Moon YW, Moon JL, Kim SS. Brook's posterior stabilisation surgery for atlantoaxial instability: review of 54 cases. *J Orthop Surg* 2002; 10(2): 160-164.
9. Osmotherly PG, Farrell SF, Digby SD, Rowe LJ, Buxton AJ. The influence of age, sex, and posture on the measurement of atlantodental interval in a normal population. *J Manipulative Physiol Ther* 2013; 36: 226-231.
10. Osmotherly PG, Rivett DA, Rowe LJ. The anterior shear and distraction tests for craniocervical instability. An evaluation using magnetic resonance imaging. *Manual Therapy* 2012; 17: 416-421.
11. Rojas CA, Bertozzi JC, Martinez CR, Whitlow J. Reassessment of the craniocervical junction: Normal values on CT. *Am J Neuroradiol* 2007; 28: 1819-1823.
12. Sanke SS, Kumar SKS. Neuroimaging in crani-overtebral anomalies as seen in the tropics. *Neuroimage Clin North Am* 2011; 21: 879-895.
13. Seo SJ, Kim HR, Choi EJ, Nahm FS. Unrecognized C1 lateral mass fracture without instability; the origin of posterior neck pain. *Korean J Pain* 2012; 25: 258-261.
14. Tubbs RS, Mortazavi MM, Louis RG, Loukas M, Shoja MM, Chern JJ, Benninger B, Cohen-Gadol AA. The anterior atlantodental ligament: Its anatomy and potential functional significance. *World Neurosurg* 2012; 77 (5/6): 775-777.
15. Westaway MD, Hu YW, Stratford PW, Maitland ME. Intra and interrater reliability of the anterior atlantodental interval measurement from conventional lateral view flexion/extension radiographs. *Man Ther* 2005; 10: 219-223.