



## COMPREHENSIVE MANAGEMENT OF TRAUMATIC THORACOLUMBAR VERTEBRAL FRACTURE

### TRAVMATİK TORAKOLOMBER OMURGA KIRIĞININ KAPSAMLI YÖNETİMİ

Mehmet Fatih KORKMAZ<sup>1</sup>,  
Mehmet KARATAS<sup>2</sup>,  
Resit SEVİMLİ<sup>3</sup>,  
Mehmet Nuri ERDEM<sup>4</sup>

<sup>1</sup>Assistant Professor in  
Department of Orthopaedics and  
Traumatology, Inonu University  
School of Medicine, Malatya.

<sup>2</sup>Assistant Professor in  
Department of History of  
Medicine and Ethics, Inonu  
University School of Medicine,  
Malatya.

<sup>3</sup>Doctor in Department of  
Orthopaedics and Traumatology,  
Inonu University School of  
Medicine, Malatya.

<sup>4</sup>Doctor in Department of  
Orthopaedics and Traumatology,  
Kolan International Hospital,  
Istanbul.

**Address:** Mehmet Fatih Korkmaz,  
MD; Department of Orthopaedics  
and Traumatology, Inonu  
University School of Medicine,  
Malatya / Turkey  
**E-mail:** fatih.korkmaz@inonu.edu.tr  
**Tel:** 0422 3410660-5103  
**Fax:** 0422 3410036  
**Received:** 1st July, 2014  
**Accepted:** 26th August, 2014

#### SUMMARY

The middle section of the vertebral spine is composed of three-dimensional trabecular networks of rods and plates. This trabecular structure ensures 90% of the compressive strength, particularly in the lumbar vertebrae. Moreover, bone marrow inside the trabecular network increases the compressive strength and energy absorption. Anterior components of the vertebral column (cylindrical vertebral bodies and discs) resist compressive forces, while posterior ligamentous elements resist tensile forces. Anterior and posterior elements also enable resistance to diagonal and rotational forces and bending moment.

**Key words:** Thoracolumbar fractures, ossification, vertebrae

**Level of evidence:** Review article, Level V

#### ÖZET

Vertebral omurganın orta bölümü çubuk ve plakaların oluşan üç boyutlu trabeküler ağından oluşur. Bu trabeküler yapı özellikle bel omurları içinde basınç dayanımının %90'ı sağlar. Ayrıca, trabeküler ağ içindeki kemik iliği basınç dayanımı ve enerji emilimini artırır. Bel kemiğinin anterior bileşenleri (silindirik vertebral gövde ve disk) sıkıştırıcı kuvvetlere karşı direnç sağlarken, posterior ligamentöz elemanlar gerilme kuvvetlerine karşı direnç sağlar. Anterior ve posterior elemanlar diyagonal ve rotasyonel kuvvetlere ve eğilme momentinde direnç sağlar.

**Anahtar Kelimeler:** Torakolomber bölge kırıkları, kemikleşme, omurga

**Kanıt Düzeyi:** Derleme, Düzey V

## INTRODUCTION:

The middle section of the vertebral spine is composed of three-dimensional trabecular networks of rods and plates<sup>32</sup>. Thoracolumbar ossification starts at the lower thoracic area and spreads to the proximal and distal areas. The thoracolumbar vertebrae develop to adult levels of biomechanics and fracture risk between 8 and 10 years of age. At the age of 15, the vertebrae gain adult morphological characteristics<sup>18,28</sup>.

Thoracolumbar fractures are seen more frequently in males between 20 and 40 years of age compared to females<sup>12,21,31</sup>. In the USA, approximately 16,000 patients per year suffer from spinal column injuries<sup>14</sup>. In a multi-center study conducted by the Scoliosis Research Society, it was reported that 52% of thoracolumbar fractures were between T11–L1, 32% between L2–5, and 16% between T1–10. In a study on 1,446 thoracolumbar fractures, Magerl and Engelhardt showed that 28% of the fractures were seen at L1, 17% were at T12, and 14% were at L2<sup>31</sup>.

Only 1–10% of all vertebral traumas are seen in children<sup>15</sup>. Considering that at least 50% of mild and moderate traumas are not referred to hospital, and the proportion of vertebral traumas detected after autopsy is 12%, the actual incidence of vertebral trauma in children is likely to be higher. Vertebral injuries are mostly observed in children younger than 5 years of age and older than 10 years of age.

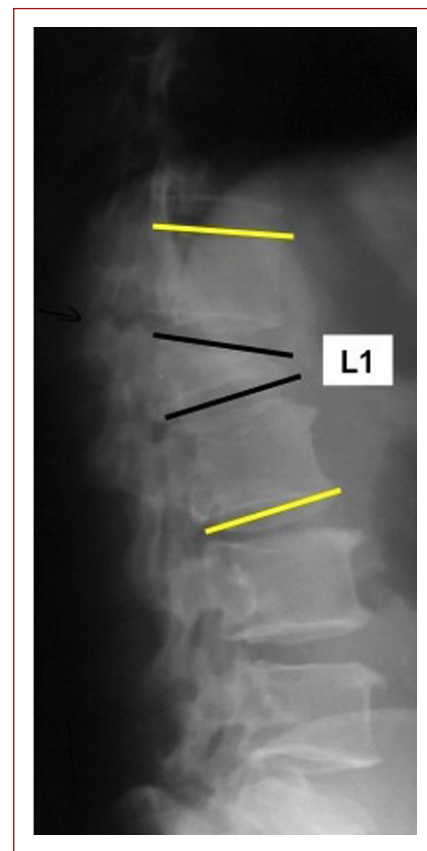
Spinal cord injury with no radiological findings represents 5–70% of all vertebral injuries. Two thirds of cases are seen in children eight years old or younger. Patient examination shows instability in the vertebral column, epidural hematoma, cord rupture, necrosis, atrophy, edema, infarction, and contusion, with 20% of these symptoms being treatable<sup>50</sup>. Late development of the lesions following trauma and progression are signs of poor prognosis.

Studies have reported that the most frequent reason for thoracolumbar fractures is traffic accidents (50%). Other reasons include falling from a height (21%), injuries by sharp objects or gunshots (11%), sports-related injuries (10%) and other reasons (8%)<sup>38,43</sup>.

## EXAMINATION FINDINGS:

On examination of vertebral traumas, ecchymosis, skin abrasion, open wounds, swelling, hematoma, displacement of the vertebral line, and gaps between

the spine disc protrusions should be inspected. Most patients with vertebral injuries are often polytraumatic, therefore vertebral injuries may be overlooked at the initial examination<sup>13</sup>. Anderson et al. reported that 23% of thoracolumbar fractures were diagnosed after patients left the emergency clinic<sup>5</sup>. Dai et al. also reported that in 19% of polytraumatic patients, the diagnosis of thoracolumbar fractures was delayed<sup>10</sup>. Thoracolumbar fractures are often overlooked due to a requirement for other examinations before thoracolumbar radiography in emergency patients<sup>34</sup>. More recently, with the routine use of computed tomography (CT) for polytraumatic patients, the delayed diagnosis of vertebral fractures is very rare<sup>19,40</sup>.



**Figure-1.** The preoperative sagittal index at the L1 vertebral segment was 25°.

Neurological examination of the patient should be performed and recorded carefully otherwise changes in the neurological condition may not be appreciated, resulting in inaccurate treatment. The American Spinal Cord Injury Association registry form is widely used for neurological evaluation<sup>13</sup>.

## RADIOLOGICAL EVALUATION:

The sagittal index is significant for the evaluation of kyphotic deformity seen in vertebral fractures. This is calculated on lateral X-rays. The sagittal index angle is obtained by subtracting the normal kyphosis angle from the measured kyphotic angle (sagittal index = kyphotic angle - normal physiological angle). It is important to know the normal physiological angles to measure the sagittal index. These angles are 5° between T1–11 in the dorsal region; 0° at T12 and L1, and 10° between L2–5 in the lumbar region. A sagittal index up to 15–20° is considered normal (Figure-1).

In spine trauma patients, radiological evaluation is performed using standard anteroposterior (AP) and lateral radiographs obtained from both sides. In AP X-rays, loss of lateral vertebral body height, changes in the vertical and horizontal interpeduncular fossa, asymmetry in the posterior structures, luxation in the costovertebral joints, perpendicular or oblique fractures in the dorsal structures, and irregularity between the spinous protrusions should be evaluated, and in lateral X-rays the sagittal image, degree of compression of the vertebral body, deformation of the posterior line of the vertebral body, dislocation of the dorsoapical fragments, and the height of the intervertebral gap should be evaluated<sup>8</sup>.

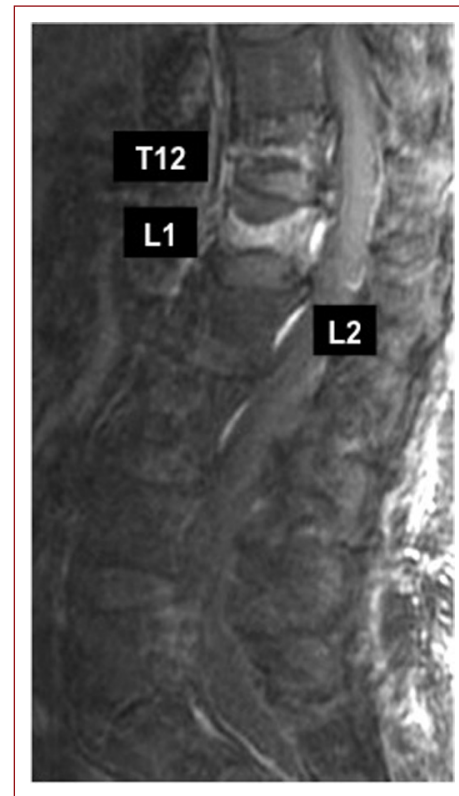The sensitivity and specificity of CT is higher than radiography, therefore CT or multi-slice CT should be preferred after the general condition of the patient has been stabilized<sup>48</sup>. Myelography on its own, or with CT, may identify the compression forces in the channel.

MRI is important in the evaluation of soft tissues<sup>35</sup>. If there is no neural deficit, MRI is not essential in the acute phase, but, in the presence of a neural deficit, MRI may be used to visualize a cord lesion or epidural hematoma and compression due to the disc or fracture fragments. In T2-weighted MRI, increased signal in the spine indicates edema, while decreased signal is indicative of a hematoma (Figure-2).

## CLASSIFICATION:

In vertebral injuries, different classifications have been defined according to the fracture morphology and stability, using the Holdsworth classification, Ferguson-Allen classification, Denis classification, and AO classification. The Denis classification and AO

classification, defined by Magerl, are the most commonly used classifications today<sup>12,17,30</sup>.



**Figure-2.** Acute T12–L1 and chronic L2 osteoporotic vertebral compression fractures are shown in the same MRI. In acute fractures, there is typically abnormal contrast enhancement seen on T1-weighted scans with fat saturation.

In the Denis classification, each vertebra is examined as a three-column model. The anterior column is comprised of 2/3 of the anterior vertebral corpus, 2/3 of the intervertebral disc, and the anterior longitudinal ligament. The middle column is comprised of 1/3 of the posterior vertebral corpus, 1/3 of the posterior intervertebral disc, and the posterior longitudinal ligament. The posterior column is comprised of the arcus vertebral region from the pedicles and the posterior ligamentous complex (ligamentum flavum, interspinous and supraspinous ligaments). In the classification, the middle column is accepted as the central structure and classification is made according to the middle column<sup>12</sup>.

The AO classification was described by Magerl based on two-column theory, and further defined by Holdsworth, Kelly and Whitesides<sup>17,47</sup>. According to this theory, the anterior column consists of the vertebral corpus and intervertebral disc, and the posterior column is

composed of the pedicles, laminae, facet joints, and posterior ligamentous complex. The anterior column carries weight and the posterior column bears tension. In a study by Leibl et al, the AO classification was found to be superior to the Denis classification for the choice of treatment<sup>27</sup>.

## **TREATMENT:**

Stabilization of the fractured spine is crucial for treatment<sup>3</sup>. In the literature, these types of fractures have been treated with different procedures, such as conservative treatment and early surgical treatment. Factors affecting the treatment results are the fracture type, fracture location, and the presence of neurological loss. The severity of thoracolumbar injuries is scored by the TLISS scale, which was described by Vaccaro et al.

The questions that need to be answered before starting the treatment of thoracolumbar vertebral fractures are:

1. Is there a neurological defect?
2. Is the neurological defect progressive?
3. Is there spinal instability due to the fracture?
4. Is there damage at the posterior ligaments?
5. Is there disc damage?

## **Conservative treatment:**

Fast radiological image loss has been detected in a conservative group in the first year, so there is therefore a risk of mechanical instability within the first twelve months. This should be considered during the follow-up of cases. Nonetheless, orthopedists have suggested conservative treatment for thoracolumbar burst fractures<sup>33,46</sup>.

According to Krompinger, a lack of neurological deficit, a channel intrusion less than 50%, and a kyphotic angle smaller than 30° are necessary for conservative treatment<sup>25</sup>. According to Reid, patients with a kyphotic angle smaller than 25°, without any pathological condition preventing replacement device use, and patients who could adapt to the conservative treatment protocol, qualified for conservative treatment<sup>39</sup>. However, for Denis and Alici, all burst fractures are unstable, and therefore they should all be treated surgically<sup>4,11</sup>.

There are complications with conservative treatment, such as neurological loss, progressive channel intrusion, progressive body collapse, and progressive kyphotic changes.

## **Surgical Treatment:**

There are some advantages of surgical treatment, including early mobilization, anatomical reduction of the fracture, maintenance of spinal alignment, and quick recovery of neurological functions<sup>2,4,11,22</sup>.

With surgical treatment, the aim is to ensure the decompression of the spine and cord, the restoration of the physiological and topological interaction of the spinal channel, mono/oligo-segmental correction/reconstruction of the anterior and posterior vertebral columns, the management of immediate and postoperative long-term stability of the corrected areas without disturbing neighboring undamaged segments, and the achievement of durable, reliable and fast bone fusion<sup>7</sup>.

## **Common Surgical Procedures:**

1. Anterior decompression + anterior fusion (costa/fibular allograft)
2. Anterior decompression + anterior fusion (autograft/allograft) + anterior instrumentation (+/- vertebral spacer/cage)
3. Anterior decompression and anterior fusion (autograft/allograft) + anterior instrumentation (+/- vertebral spacer/cage) + posterior instrumentation + posterior fusion (autograft/allograft) in the same session
4. Two-stage anterior-posterior approach
5. Anterior decompression + posterior decompression + anterior instrumentation + anterior fusion
6. Dorso-ventro-dorsal approach (posterior decompression + temporal posterior stabilization + anterior decompression + anterior fusion (costa/fibular allograft) + posterior fusion (autograft/allograft) + posterior instrumentation
7. Posterior egg-shell method
8. Posterior closing wedge osteotomy<sup>7</sup>.

There are studies suggesting the anterior approach is the best method and that successful results may be obtained by using anterior instrumentation alone<sup>23,24</sup>. With an anterior approach, it is easier to access the anterior and middle column and the structural anterior supports, compared to the posterolateral or transforaminal approaches, which enables the deformity to be appropriately corrected and fused<sup>1,9,24</sup>. The most significant advantage of anterior instrumentation is the

inclusion of less mobile segments in the fusion area, therefore avoiding iatrogenic damage to the adjacent vertebrae<sup>6</sup>.

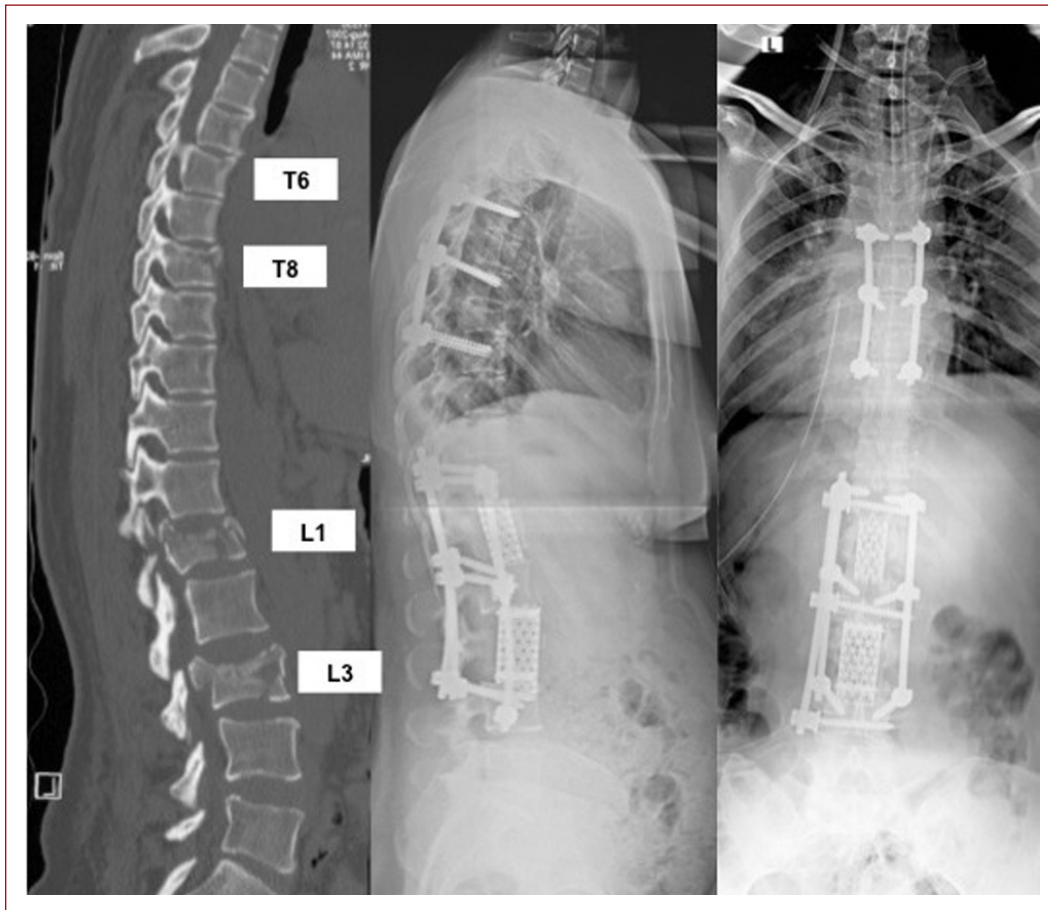
Posterior instrumentation after an anterior procedure is a common method for protecting the grafts placed from the anterior aspect and the vertebral instability<sup>36,41</sup>. Complications of anterior surgery may be related to the surgical procedure, decompression of the neural structures, and stabilization of the spine<sup>23,26,29</sup>.

Pneumothorax or hemopneumothorax may occur. Insufficient repair of the diaphragm might result in postoperative respiratory problems with hernia and atelectasis. Urethral injury, thoracic lymph channel injury, and spleen rupture may be seen. During dissection of the lumbar vertebra, the spacing and tension of the psoas muscle may result in compression of the lumbar plexus

and neuropraxia.

The main advantages of a posterior closing wedge osteotomy are that a posterior approach is single stage, has a short operation time without the need for an anterior surgical approach, less intraoperative blood loss, decreased postoperative morbidity, good recovery in the sagittal axis, solid spinal stabilization and fusion with the use of a transpedicular spinal system, sufficient bone graft for fusion, and the lack of anterior column insufficiency<sup>7</sup>.

The disadvantages of a closing wedge osteotomy include indirect neural decompression, damage of healthy posterior elements, difficulty in supporting the anterior column, the necessity of long-term posterior instrumentation, and the possible need for an additional anterior procedure (Figure-3)<sup>7</sup>.



**Figure-3.** Multiple thoracolumbar vertebral fractures after a fall from a great height treated with anterior L1 and L3 lumbar corpectomy and fusion with thoracic and lumbar posterior instrumentation.

The placement of an anterior interbody graft support increases the fusion rate with load sharing and helps the restoration of lordosis. An interbody graft could be placed by a conventional anterior, a posterior transforaminal, or a posterior lumbar interbody fusion approach<sup>37</sup>. One of the new methods, XLIF (Extreme Lateral Interbody Fusion), has begun to be used for this purpose<sup>36</sup>.

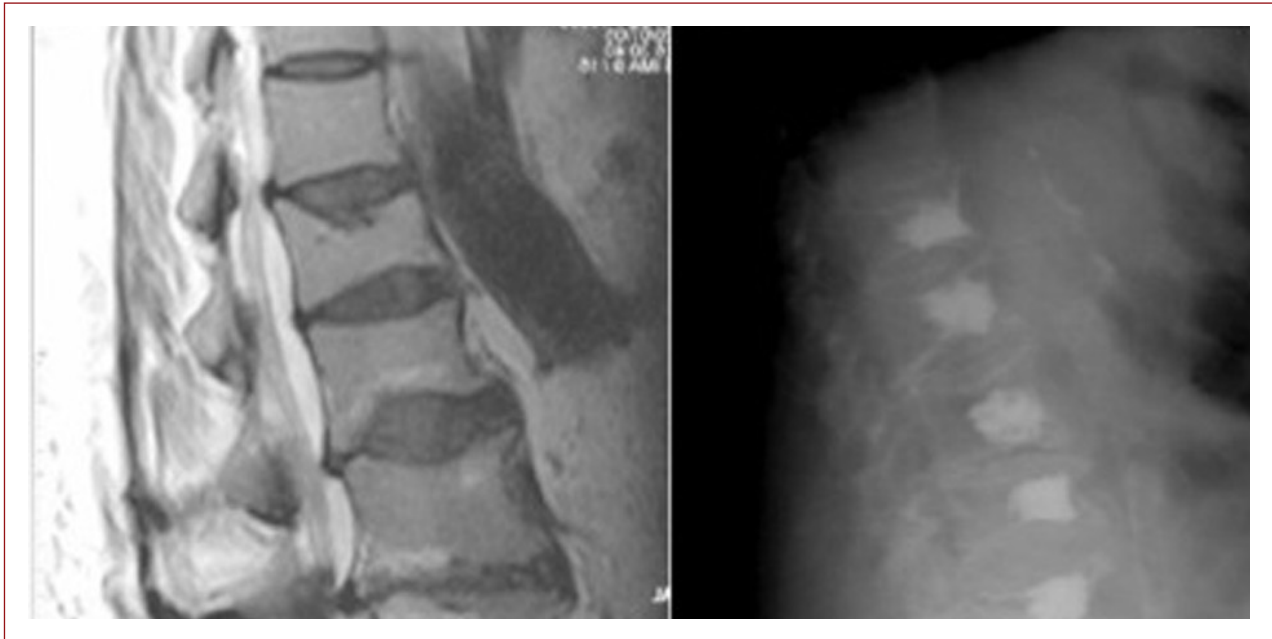Channel decompression is not required for fractures in children with no neural deficit. Short-term resting and early mobilization in a cast is performed. In cases with a neural deficit, compression on the spinal channel should be removed by an anterior or posterolateral approach, stability should be ensured by posterior instrumentation, and fusion should be performed.

There is no major difference in the treatment procedure

during pregnancy. Pregnant women show good prognosis after certain diagnosis and appropriate treatment<sup>16</sup>.

In recent years, alternative treatment methods such as vertebroplasty (VP) and kyphoplasty (KP) have been developed for the treatment of collapse fractures<sup>49</sup>. VP and KP were developed as alternative procedures to stabilization surgery that enable anatomic-functional restoration of vertebrae with less damage, and are preferred for quick recovery of the symptoms and to enable patients to return to their social life in a short time (Figure-4)<sup>42,44,45</sup>.

The general health condition and age of the patient, the trauma type, the time between trauma and surgery, and the experience of the surgeon, all significantly affect the success rate of treatment<sup>20,39</sup>.



**Figure-4.** Sagittal T2-weighted MRI of lumbar vertebrae showing acute L1–5 and chronic T12 osteoporotic vertebral compression fractures. Vertebroplasty for acute fractures with prophylactic vertebroplasty at the L2, L3, and L4 levels, and kyphoplasty for the chronic compression fracture at the T12 level were carried out.

## REFERENCES

1. Abel R, Gerner HJ, Smit C, Meiners T. Residual deformity of the spinal canal in patients with traumatic paraplegia and secondary changes of the spinal cord. *Spinal Cord* 1999; 37: 14-19.
2. Akbarnia BA, Crandall DG, Burkus K, Matthews T. Use of long rods and short arthrodesis for burst fractures of the thoracolumbar spine. A long - term follow - up study. *J Bone Joint Surg* 1994; 76-A: 1629-1635.
3. Alici E, Berk H, Karakasli A, Gocen S. Instability of the spine fracture. *Turkish J Spine Surgery* 1992; 3: 25- 30.
4. Alici E, Kininca M, Gocen S, Berk H, Aksu G. Neurological deficit in relation in the canal encroachment. Level and type of the thoracolumbar fractures. *J Turkish Spinal Surg* 1997; 8: 39 -42.
5. Anderson S, Biros MH, Reardon RF. Delayed diagnosis of thoracolumbar fractures in multiple-trauma patients. *Acad Emerg Med* 1996; 3: 832-839.
6. Been HD, Poolman RW, Ubags LH. Clinical outcome and radiographic results after surgical treatment of post-traumatic thoracolumbar kyphosis following simple type A fractures. *Eur Spine J* 2004; 13: 101-107.
7. Bilgic S, Yildiz C, Sehirlioglu A. Posttraumatic Kyphosis. *J Clin Anal Med* 2011; 2(3): 135-143.
8. Blauth M, Knop C, Bastian L. In: Tscherne H, Blauth M (eds.) *Tscherne Unfallchirurgie*, vol 3. Springer, Berlin, 1998, pp: 241-381.
9. Bohlman HH, Freehafer A, Dejak J. The results of treatment of acute injuries of the upper thoracic spine with paralysis. *J Bone Joint Surg* 1985; 67-A: 360-369.
10. Dai L-Y, YaoW-F, Cui Y-M, Zhou Q. Thoracolumbar fractures in patients with multiple injuries: diagnosis and treatment – a review of 147 cases. 2004, 56: 348-355.
11. Denis F, Armstrong GWD, Scarls K, Malla L. Acute thoracolumbar burst fractures in the absence of neurologic deficit. A comparison between operative and nonoperative treatment. *Clin Orthop* 1984; 189: 142-149.
12. Denis F. The three column spine and its significance in the classification of acute thoracolumbar spinal injuries. *Spine* 1983; 8: 817-831.
13. Ditunno JF Jr, Young W, Donovan WH, Creasy G. International standarts booklet for neurological and functional classification of spinal cord injury. American Spinal Cord Injury Association. *Paraplegia* 1984; 32: 90-80.
14. El-Khoury GY, Whitten CG. Trauma to the upper thoracic spine: anatomy, biomechanics, and unique imaging features. *AJR Am J Roentgenol* 1993; 160: 95-102.
15. Hadley MN, Zabramski JM, Browner CM, ReKate H, Sonntag VK. Pediatric spinal trauma. *J Neurosurg* 1988; 68: 18-24.
16. Han IH. Pregnancy and spinal problems. *Curr Opin Obstet Gynecol* 2010; 22(6): 477-481.
17. Holdsworth F. Fractures, dislocations, and fracture-dislocations of the spine. *J Bone Joint Surg* 1970; 52-A: 1534-1551.
18. Hubbard DD. Injuries of the spine in children and adolescents. *Clin Orthop* 1975; 100: 56-65.
19. Inaba K, Munera F, McKenneyM, Schulman C, deMoya M, Rivas L, Pearce A, Cohn S. Visceral torso computed tomography for clearance of the thoracolumbar spine in trauma: a review of the literature. *J Trauma* 2006; 60: 915-920
20. KeeneJS, Lash EG, Kling TF Jr. Undetected posttraumatic instability of “stable” thoracolumbar fractures. *J Orthop Trauma* 1988; 2: 201-211.
21. Kelly RP, Whitesides TE. Treatment of lumbodorsal fracture-dislocations. *Ann Surg* 1968; 167: 705-717.
22. Knop C, BlauthM, Bühren V, Hax PM, Kinzl L, Mutschler W, Pommer A, Ulrich C, Wagner S, Weckbach A, Wentzensen A, Wörsdörfer O. Surgical treatment of injuries of the thoracolumbar transition. 1: Epidemiology. *Unfallchirurg* 1999; 102: 924-935.
23. Koroyesis PG, Baikousis A, Stamatakis M. Use of the Texas Scottish Rite Hospital instrumentation in the treatment of thoracolumbar injuries. *Spine* 1997; 12: 882-888.
24. Kostuik JP. Anterior Kostuik-Harrington distraction systems for the treatment of kyphotic deformities. *Spine* 1990; 15(3): 169-180.
25. Kostuik JP, Matsusaki H. Anterior stabilization, instrumentation, and decompression for post-traumatic kyphosis. *Spine* 1989; 14(4): 379-386.
26. Krompinger WJ, Fredrickson BE, Mino DE, Yuan HA. Conservative treatment of fractures of the thoracic and lumbar spine. *Orthop Clin North Am* 1986; 17: 161-170.
27. Lange U, Knop C, Bastian L, Blauth M. Prospective multicenter study with a new implant for thoracolumbar vertebral body replacement. *Arch Orthop Trauma Surg* 2003; 123(5): 203-208.
28. Lewandrowski K-U, McLain RE. Thoracolumbar fractures: Evaluation, classification and treatment. Frymoyer JW, Wiesel SW (Eds.). *The Adult and Paediatric Spine*. Third Ed., Vol 2., Lippincott Williams and Wilkins, 2004; pp: 817-843.
29. Lonstein JE, Bradford DS, Winter RB (eds.). *Moë's Textbook of Scoliosis and Other Spinal Deformities*. 3rd Edition, WB Saunders, Philadelphia, 1995; 6-22.

30. Lonstein JE, Winter RW. Long multiple struts for severe kyphosis. *Clin Orthop* 2002; 394: 130-138.
31. Magerl F, Aebi M, Gertzbein SD, Harms J, Nazarian S. A comprehensive classification of thoracic and lumbar injuries. *Eur Spine J* 1994; 3: 184-201.
32. Magerl F, Engelhardt P. Brust und Lendenwirbelsäule. In: Witt AN, Rettig H, Schlegel KF (eds), *Orthopädie in Praxis und Klinik, Spezielle Orthopädie (Wirbelsäule-Thorax - Becken)*. Thieme, Stuttgart, 1994; pp: 3.82-3.13.
33. Marco RW, An HS. Anatomy of the spine. *Orthopaedic Knowledge Update Spine 2* (eds), American Academy of Orthopedic Surgeons, Illinois, 2002; 7-14.
34. Mumford J, Weinstein JN, Spratt KE, Goel YK. Thoracolumbar burst fractures - The clinical efficacy and outcome of nonoperative management. *Spine* 1993; 18: 955-970
35. Norbert Boos, Max Aebi. *Spinal Disorders Fundamentals of Diagnosis and Treatment*, Spingers, New York, 2008.
36. Oner FC, van Gils APG, Faber JAJ, Dhert WJA, Verbout AJ. Some complications of common treatment schemes of thoracolumbar spine fractures can be predicted with magnetic resonance imaging. Prospective study of 53 patients with 71 fractures. *Spine* 2002; 27: 629-636.
37. Ozgur BM, Aryan HE, Pimenta L, Taylor WR. Extreme Lateral Interbody Fusion (XLIF): a novel surgical technique for anterior lumbar interbody fusion. *Spine J* 2006; 6(4): 435- 443.
38. Polly DW Jr, Klemme WR, Shawen S. Management options for the treatment of posttraumatic thoracic kyphosis. *Semin Spine Surg* 2000; 12: 110-116.
39. Price C, Makintubee S, Herndon W, Istree GR. Epidemiology of traumatic spinal cord injury and acute hospitalization and rehabilitation charges for spinal cord injuries in Oklahoma, 1988-1990. *Am J Epidemiol* 1994; 139: 37-47.
40. Reid OC, Hu R, Davis LA, Saboc LA. The nonoperative treatment of burst fractures of the thoracolumbar junction. *J Trauma* 1988; 28: 1188-1194.
41. Sheridan R, Peralta R, Rhea J, Ptak T, Novelline R. Reformatted visceral protocol helical computed tomographic scanning allows conventional radiographs of the thoracic and lumbar spine to be eliminated in the evaluation of blunt trauma patients. *J Trauma* 2003; 55:665-922.
42. Suk SI, Kim JH, Lee SM, Chung ER, Lee JH. Anterior-posterior surgery versus posterior closing wedge osteotomy in posttraumatic kyphosis with neurologic compromised osteoporotic fracture. *Spine* 2003; 28(18): 2170-2175.
43. Theodorou DJ, Theodorou SJ, Duncan TD, Garfin SR, Wong WH. Percutaneous balloon kyphoplasty for the correction of spinal deformity in painful vertebral body compression fractures. *Clin Imaging* 2002; 26: 1-5.
44. Thurman DJ, Burnett CL, Jeppson L, Beaudoin DE, Sniezek JE. Surveillance of spinal cord injuries in Utah, USA. *Paraplegia* 1994; 32:665-669
45. Trumees E. The roles of vertebroplasty and kyphoplasty as parts of a treatment strategy for osteoporotic vertebral compression fractures. *Curr Opin Orthop* 2002; 13:193-199.
46. Watts NB, Harris ST, Genant HK. Treatment of painful osteoporotic vertebral fractures with percutaneous vertebroplasty or kyphoplasty. *Osteoporos Int* 2001; 12: 429-437.
47. Weinstein JN, Collalto P, Lehmann TR. Thoracolumbar burst fractures treated conservatively: a long - term follow - up. *Spine* 1988; 13: 33-38.
48. Whitesides TE. Traumatic kyphosis of the thoracolumbar spine. *Clin Orthop* 1977; 128: 78-92.
49. Woltmann A, Bühren V. Emergency room management of the multiply injured patient with spine injuries. A systematic review of the literature. *Unfallchirurg* 2004; 107: 911-919.
50. Wong W, Reiley MA, Garfin S. Vertebroplasty/kyphoplasty. *J Women's Imaging* 2000; 2: 117-124.
51. Yngve DA, Harris WP, Herndon WA. Spinal cord injury without osseous spine fracture. *J Pediatr Orthop* 1988; 8: 153-159.