



## CLAY-SHOVELER'S FRACTURE FOLLOWING A FALL FROM HEIGHT

### YÜKSEKTEN DÜŞME SONRASI GÖRÜLEN "KUM KÜREYİCİLERİN KIRIĞI"

Gökşin ŞENGÜL<sup>1</sup>,  
Mehmet Hakan ŞAHİN<sup>1</sup>,  
Nuh Çağrı KARAAVCI<sup>1</sup>,  
Fatih ALPER<sup>1</sup>

<sup>1</sup> Atatürk Üniversitesi, Tıp Fakültesi,  
Araştırma Hastanesi, Beyin ve Sinir  
Cerrahisi, Erzurum.

#### SUMMARY:

Clay-shoveler's fracture represents an avulsion type of fracture of a spinous process in the lower cervical or upper thoracic region. It is an extremely rare injury at the present times but may be one aspect of a serious injury. A 36 year old male was admitted following a fall from a height. He had severe neck and thoracic back pain with radiation to the bilateral shoulder region. Radiological examination revealed spinous process fractures of the C6, C7 and Th1 vertebrae. Treatment was conservative and good clinical outcome was maintained. Clay-shoveler's fracture is generally considered stable fractures. However, it may be associated with other serious injuries. Thorough diagnostic work-up should be performed in high risk injuries.

**Key words:** Clay-shoveler's fracture, cervicothoracic region fractures, spinous process, treatment

**Level of evidence:** Case report, Level IV

#### ÖZET:

"Kum küreyicilerin kırığı", alt servikal ve üst torakal bölgedeki spinöz çıkıntıların ayrılma kırığıdır. Günümüzde oldukça nadir görülen bu yaralanma ciddi bir yaralanmanın belirtisi olabilir.

36 yaşında erkek hasta yüksekten düşme sonrası, omuzlara yayılan şiddetli boyun ve sırt ağrısı şikâyetiyle müracaat etti. Radyolojik incelemede C6, C7, TH1 omurların spinöz çıkıntılarında kırık saptandı. Hasta konservatif olarak tedavi edildi ve klinik iyileşme sağlandı.

"Kum küreyicilerin kırığı" genellikle stabil kırık olarak değerlendirilir. Ancak, daha ciddi yaralanmalarla birlikte bulunabilir. Yüksek riskli yaralanmalarda kapsamlı tanılmalı çalışılmalıdır.

**Anahtar Sözcükler:** Kum küreyicilerin kırığı, servikotorasik bölge kırıkları, spinöz çıkıntı, tedavi.

**Kanıt Düzeyi:** Olgu sunumu, Düzey IV

**Address:** Atatürk Üniversitesi, Tıp  
Fakültesi, Araştırma Hastanesi, Beyin ve  
Sinir Cerrahisi, 25240 Erzurum.

**Tel.:** +90 442 344 83 66

**Fax.:** +90 442 236 13 01

**Gsm:** +90 0532 362 37 40

**E-mail:** goksinsengul@gmail.com

**Received:** 19th October, 2014

**Accepted:** 11th December, 2014

## INTRODUCTION:

Isolated spinous process fracture, known as a clay-shoveler's fracture, is an avulsion type fracture of one or more spinous process of the lower cervical or upper thoracic vertebrae.

Though these fractures may occur anywhere between C6-T3, C7 or both C7 and T1 are the most commonly affected sites. They are generally considered stable injuries but may be a warning sign of more severe spinal injuries<sup>1,5,9,10</sup>.

In this report, a case of multiple contiguous isolated spinous process fracture of the cervico-thoracic spine is presented.

## CASE REPORT:

A 36-year-old male was admitted following a fall from height. He had severe neck and posterior thoracic pain. Physical examination revealed localized tenderness and limited motion over the dorsal cervical-thoracic region. Neurological examination was normal. Plain radiographs and computed tomography demonstrated fractures of the isolated spinous process of the C6, C7 and T1 vertebrae (Figure-1.a,b). Sagittal T1 and T2-weighted magnetic resonance (MR) imaging also showed spinous process fractures C6, C7 and T1. STIR MR images revealed high signal areas in C3 vertebra body and paraspinal area suggestive of an acute injury (Figure-1.c,d).

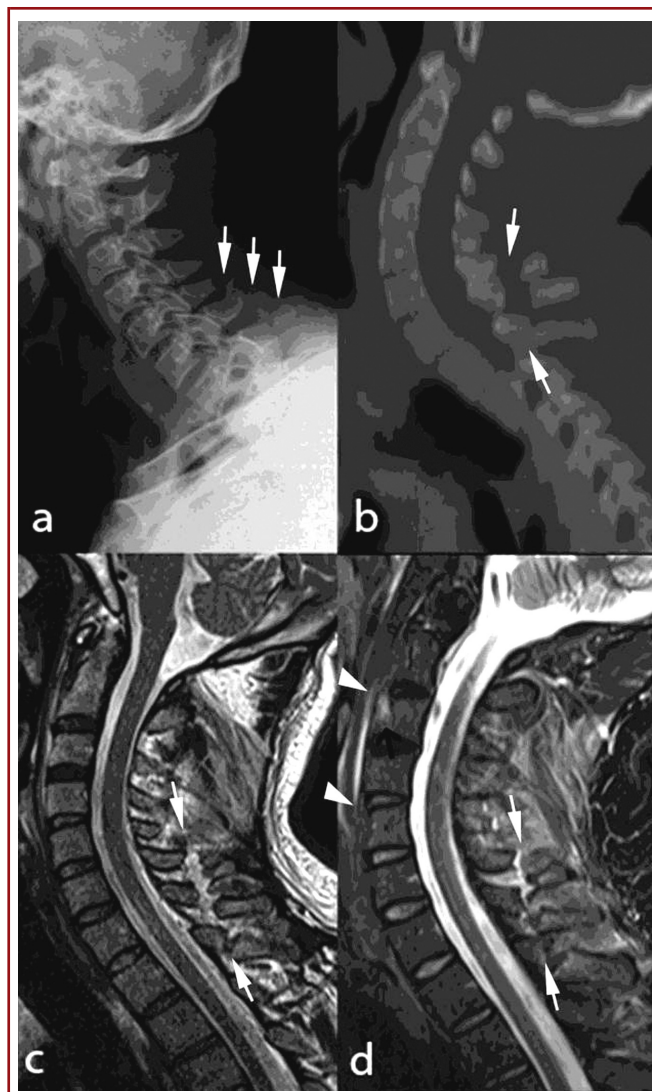
The patient was treated conservatively by analgesic therapy and immobilization with cervical collar for six weeks.

## DISCUSSION:

Clay-shoveler's fracture was first described as an occupational injury in the beginning of 20th century in Western Australia, named for laborers who incurred whip like pulls along the supra-spinal ligaments while shove ling clay over their shoulders. It was most prevalent in workers who regularly engage in weight-bearing activities.

With the advent of industrialization and reduced weight bearing activities it has become relatively rare. In more recent years reported cases are only case reports. In present times, motor vehicle collisions and sports injuries are the common causes of spinous process fractures<sup>2,4-6</sup>. Isolated spinous fracture after falling from height rarely occurs as seen in our case. It occurs when the head and upper cervical segments are forced into flexion against the opposing action of the interspinous and supraspinous ligaments. Direct blow to the posterior aspect of the neck, cervical hyperextension and hyperflexion injuries, muscle and ligament stresses, generally due to shovel heavy loads are the proposed causative mechanisms that lead to the fractures of the vertebral spinous process<sup>2,8</sup>.

Pain at the level of the fractured spine is the main symptom of clay-shoveler's fracture. It may increase with repeated activity that strains the muscles of upper back and gradually subsides in days to weeks. Tenderness on the skin over the posterior spine can be found in the examination of the patient<sup>3,8</sup>.



**Figure-1.** a. Plain radiograph and b. computed tomography of the cervical spine showing spinous process fractures of C6, C7 and T1 vertebrae. c. Sagittal T2-weighted magnetic resonance images showing C5, C6, C7 and T1 spinous process fracture without spinal cord pathology. d. Sagittal MRI STIR image showing high signal areas in C3 vertebra body and paraspinal area suggestive of an acute injury.

The radiographic appearance demonstrates very classical features. On the lateral view, the fracture line is more commonly obliquely oriented, transferring midway between the tip of the spinous and the spinolaminar junction. Downward displacement of the distal spinous fragment and the "double spinous shadow" are seen on the AP view if the shoulders obscure visualization on the lateral radiographs. The possibility of segmental instability can be excluded by flexion extension studies. The lower cervical spine may be difficult to visualize due to patient obesity, muscularity, short neck or severe muscle pain. If the lower cervical spine or cervico-

---

thoracic junction is not well visualized on cervical spine lateral radiographs, computed tomography scans should be obtained. Magnetic resonance imaging should be performed in all cases for detecting further injuries to the surrounding structures including spinal cord and ligaments<sup>2,6-8</sup>. Nuchal bone formation and un-united secondary ossification center of the spinous tip should be considered in the differential diagnosis<sup>2</sup>.

Clay-shoveler's fracture is stable but painful fractures. Immobilization of the neck with a cervical collar, restriction of physical activity for 4 to 6 weeks generally results in pain relief in most patients. Healing of the fracture is rare and re-attachment may only occur if there is a minimal displacement of the avulsed fragment. Non-union of the avulsed fragment is common due to the muscular pull in this region. Clay-shoveler's fractures tend to heal without residual squeal in terms of neck function and pain. If severe pain persists after conservative treatment, surgical excision of the avulsed fragment should be considered<sup>2,5</sup>.

#### REFERENCES:

1. Dickson G, Motsitsi N. Cervical spinous process fractures: the spectrum of injuries. *J Spine Surg* 2007; 4(2): 421-426.
2. Feldman VB, Astri F. An atypical clay-shoveler's fracture: a case report. *J Can Chiropr Assoc* 2001; 45: 213-220.
3. Jordana X, Galtés I, Busquets F, Isidro A, Malgosa A. Clay-shoveler's fracture: an uncommon diagnosis in palaeopathology. *Int J Osteoarchaeology* 2006; 16: 366-372.
4. Kaloostian PE, Kim JE, Calabresi PA, Bydon A, Witham T. Clay shoveler's fracture during in door rock climbing. *Orthopedics* 2013; 36: E381-383
5. Kang DH, Lee SH. Multiple spinous process fractures of the thoracic vertebrae (Clay-Shoveler's Fracture) in a beginning Golfer: a case report. *Spine* 2009; 34(15): E534-537.
6. Kim SY(1), Chung SK, Kim DY. Multiple cervical spinous process fractures in a novice golf player. *J Korean Neurosurg Soc* 2012; 52: 570-573.
7. Matar LD, Helms CA, Richardson WJ. "Spinolaminar breach": an important sign in cervical spinous process fractures. *Skeletal Radiol* 2000; 29: 75-80.
8. Solaroglu I, Kaptanoglu E, Okutan O, Beskonakli E. Multiple isolated spinous process fracture (Clay-Shoveler's fracture) of cervical spine: A case report. *Ulus Travma Acil Cerrahi Derg* 2007; 13: 162-164.
9. Unay K, Karatoprak O, Sener N, Ozkan K. A clay shoveler's fracture with renal transplantation and osteoporosis: a case report. *J Med Case Rep* 2008; 2:187.
10. Yamaguchi KT Jr, Myung KS, Alonso MA, Skaggs DL. Clay-shoveler's fracture equivalent in children. *Spine* 2012; 37: E1672-675.

