



OSTEOID OSTEOMA OF THE ATLAS: REPORT OF A NEW CASE AND REVIEW OF THE LITERATURE

ATLASIN OSTEOİD OSTEOMASI: YENİ BİR VAKA SUNUMU VE LİTERATÜRÜN GÖZDEN GEÇİRİLMESİ

Abolfazl RAHIMIZADEH¹,
Touraj YAZDI¹,
Shaghayegh RAHIMIZADEH¹

¹Pars Institute of Spinal Surgery and
Research, Pars Hospital Tehran, Iran

SUMMARY:

Osteoid osteomas of the cervical spine are uncommon causes of neck pain and painful torticollis in children, adolescents and young adults. In the cervical spine, affection of the upper cervical spine is rarely reported and in particular, atlas vertebra remains the least common location for being involved by osteoid osteomas, where only four cases have been reported previously.

Osteoid osteomas of the cervical spine are uncommon causes of neck pain and painful torticollis in children, adolescents and young adults. In the cervical spine, affection of the upper cervical spine is rarely reported and in particular, atlas vertebra remains the least common location for being involved by osteoid osteomas, where only four cases have been reported previously.

Imaging studies in a 30-year-old male suffering from severe neck pain for a period of one year disclosed an osteoid osteoma of the atlas arch. The tumor was removed with laminectomy of the atlas. Postoperatively, neck pain disappeared within a few days. At 2-year follow-up, the patient has remained symptom free.

Review of the literature disclosed since the report of the first example of the osteoid osteoma of the atlas in 1978 by Jones only 3 more cases have been published so far. Therefore, the current case is the fifth example of atlas affection by this tumor.

Key words: Atlas, Osteoid Osteoma, Spine tumors, Upper Cervical

Level of evidence: Case report, Level IV

ÖZET:

Osteoid osteoma, adölesan ve genç erişkinlerde, servikal bölgede, ağrılı torticollisin en sık sebebidir. Servikal bölgede üst servikal tutulum oldukça nadir olup, sadece 4 vaka rapor edilmiştir.

Bu olgu sunumunda 1 yıldır ağrısı olan ve görüntüme çalışmaları ile atlasın arkında yerleşmiş osteoid osteoma sunulmuştur. Tümör laminektomi ile çıkartılmıştır. Postoperatif bir kaç hafta ağrısı olan hastanın 2 yıl sonundaki kontrolünde hastanın ağrısının olmadığı belirlenmiştir.

Literatür taramasında ilki 1978 yılında Jones tarafından tanımlanan olgu dışında 3 olgu daha yayınlandığı görülmüştür. Bu olgu, literatürdeki 5. olgudur.

Anahtar Kelimeler: Atlas, osteoid osteoma, omurga tümörü, üst servikal omurga

Kanıt Düzeyi: Olgu sunumu, Düzey IV

Address: Abolfazl Rahimizadeh
Pars Hospital, 83 Keshawarz
Blvd15145, Tehran, Iran
Phone :+98 912 3226149
Gsm: +98 912 3226149
E-mail: a_rahimizadeh@hotmail.com
Received: 25th August, 2014
Accepted: 16th September 2014

INTRODUCTION:

Osteoid osteoma is the most common primary benign spinal tumor occurring in children and adolescents where more than 50% of the cases are seen in the second and third decade of life. Osteoid osteoma was described for the first time by Bergstrand in 1930. Later, in 1935, Jaffe defined this tumor as a benign osteoblastic tumor of bone^{3,4,10-13,15}. Osteoid osteomas are self limited tumors and small ranging in size from 0.5 to 2 cm. This tumor is mostly found in the thoracolumbar spine followed by the cervical spine^{3-4,10-13,15}. The upper cervical spine remains the least common location^{1,9}. The tumor typically is located at the posterior elements of the spine.

Recently, in our practice, we were faced with a 31-year-old man suffering severe nocturnal neck and occipital pain with positive aspirin test. Cervical MRI was suspicious of a tumor at the arch of atlas, but Isotope scan clearly showed a hot spot at the lamina of C1 compatible with osteoid osteoma. Subsequent application computerized tomography confirmed the diagnosis the osteoid osteoma of atlas arch and clarified the details of it. Hemi-laminectomy of the atlas arch result in the complete relief of pain. With careful review of the literature, we could encounter only 5 cases of osteoid osteoma of atlas reported previously, 4 of which were located at lamina and one on the lateral mass^{2,5,8}.

CASE REPORT:

A 30-year-old man was admitted with one year history of neck as well as occipital pain and spasm of the neck muscles. Examination revealed tenderness at the posterior aspect of upper cervical spine in deep palpation where his neurological exam was normal. Plain radiographs were normal. But, MRI was suspicious for pathology at the arch of atlas.

Technetium bone scan demonstrated a hot spot in the posterior arch of atlas compatible with an osteoid osteoma. Subsequently, CT scan of the upper cervical spine, with narrow slices was performed which demonstrated a small right-sided tumor in the atlas arch with sclerotic margin and a nidus inside the details of the tumor. Treatment with aspirin relieved the pain and ameliorated nuchal spasm. The risk-benefit of NSAIDs versus surgery was described and the patient's will was undergoing surgery.

Via a mid-line incision, the paravertebral muscles were stripped off the laminae of C1. Subsequently, the tumor was removed along with lamina of atlas through an appropriate hemi-laminectomy.

Post-operatively, the patient's pain and neck spasm were completely relieved. Now, at 2 years follow up, the patient is normal and free of any pain.

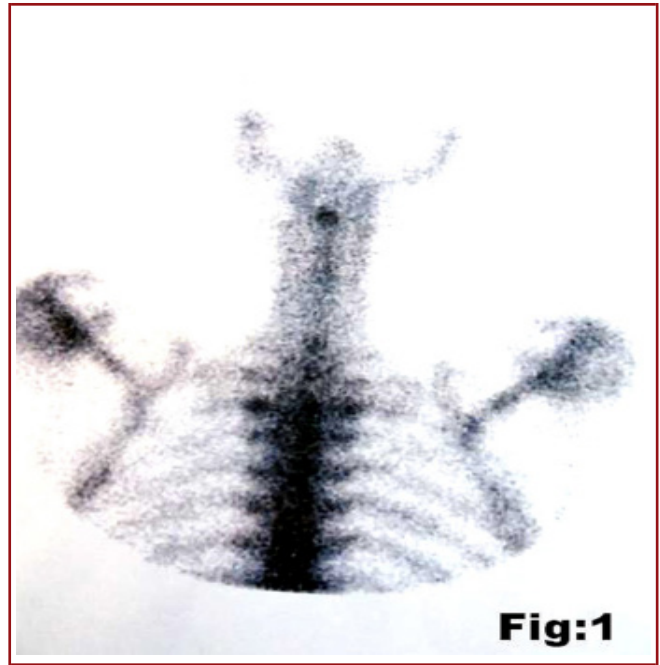


Figure-1. Isotope scan showing a hot spot in the upper cervical spine.

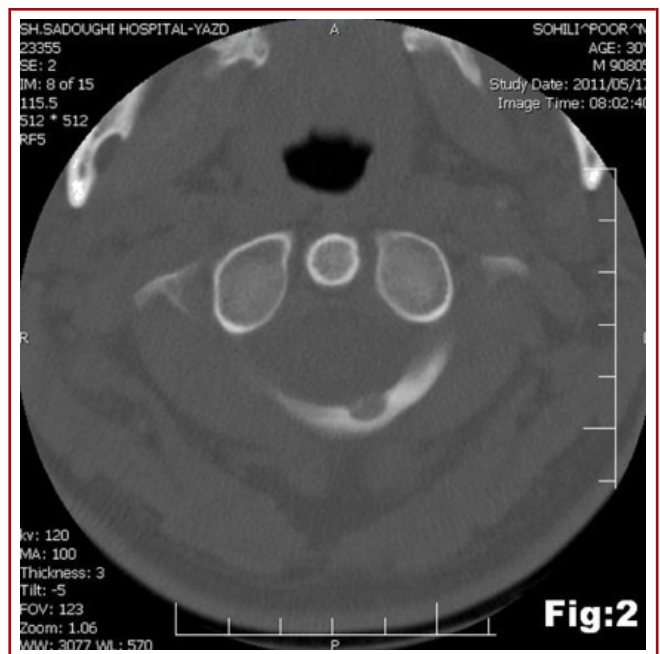


Figure-2. Axial C.T. scan through the atlas showing an osteolytic lesion in the lamina.

DISCUSSION:

Osteoid osteoma is a common primary tumor of the vertebral column. In the series of Levine et al included 41 patients treated during a 36-year period, 18 cases were osteoid osteoma where none was located at atlas⁹. Furthermore, osteoid osteoma was found in 20 out of 61 primary tumors of the cervical spine

reported by Abdu et al, but atlas was not affected in any¹. In current review, only 5 cases could be encountered in the literature (Table-1).

This tumor is composed of an osteolytic defect and sharp sclerotic margin. The osteolytic compartment contains osteoblasts that produce soft osteoid and a nidus. The nidus consists of an irregular network of osteoid trabeculae with highly vascularized stroma and varying degree of calcification presented as woven bones^{3-4,10-13}.

Osteoid osteoma usually measure from 0.5 to 2 cm in size which might be located in cancellous, sub-periosteal or cortical part of a bone. 3, 4, 10-13, 15 65 the most common and classical form is cortical type where sub-periosteal or cancellous ones remain less frequent types.

Male are more affected than females with ratio of 3 to 1. Actually, more than 50% of the cases occur in young adults, between the ages of 15 and 25^{3,4,10-13,15}. However, It rarely occurs before the age of five and after the age of 40. The predilection site of osteoid osteoma in the vertebral column is the lumbar. However, the dorsal and the cervical spine are affected in decreasing frequency and the upper cervical region remains the less frequent site of formation actually, osteoid osteomas are distributed throughout all levels except C1 and C2^{1,3,4,9-13,15}.

In careful review of the literature we could find only 7 cases with axis affection and only 4 cases affecting atlas. This tumor predominantly involves the posterior elements, such as the spinous processes, transverse processes, facets, lamina, and pedicles while it rarely prefers the vertebral body. 3 out of 4 surveyed cases including the current case were in the lamina of atlas and the other two in the lateral mass^{2,5,8}.

The clinical picture of osteoid osteoma of the cervical spine is local neck pain being reached to maximum at nights. Dramatic relief of pain by Aspirin can be used as a screening clinical test for clinical diagnosis this tumor^{1,3,4,9-13,15}. However in those affecting the cervical spine, varying degree of torticollis might be seen. Torticollis is a typical presenting feature in 10 to 100 % of those with cervical involvement^{1,9}. Torticollis was seen in 2 out of 4 cases with atlas involvement^{2,5,8}.

Unfortunately, despite classical nocturnal pain, diagnosis of this benign tumor is often delayed. Conventional radiographs usually fail to show the lesion. Actually, these small tumors are easily obscured among the overlapping shadows of the cervical spine.

Bone scintigraphy is the most sensitive screening test and can provide accurate localization of the tumor^{3-4,10-13,15} actually, early diagnosis of an osteoid osteoma can be achieved only by this tool in all cases with unexplained local pain. Thin axial slices and reformatted CT images help both the accurate shape and the exact size of the tumor, but only after scintigraphy has shown the site of affection^{2,5,8} However, if the cuts are at wrong level or too wide, the tumor might be missed completely.

GD enhanced MRI focusing on the suspected site might clearly show and detect the tumor but is less sensitive than CT scan where scintigraphy remains the most sensitive test^{2,5,8}.

Nonetheless, after establishment of the diagnosis of the osteoid osteoma of atlas and localizing the site, the treatment, in all cases has been surgical excision. In affection of the neural arch, laminectomy of the corresponding lamina will ensure the surgeon that the tumor is completely removed other modes of surgery such as en- block excision, curettage and drilling may provide similar results, although the chance of recurrence exists. Laminectomy was applied in 4 out of 5 reviewed cases including the current case. In the remaining one was managed by interlesional drilling. Regardless of the mode of surgery, tumor removal provides reliable relief of pain and the coexisting deformity disappears. Pain disappears soon after excision where torticollis resolves within a few days to a month^{2,5,8}.

Recently, with application of radiofrequency ablation of the osteoid osteomas located at the skeletal bones, success could be easily achieved^{6,7}. But careful and safe application of this setting in osteoid osteoma of the vertebral column is concerned with regard to possible thermal damage to the neural structures. This method might be useful in those tumors where the site of affection is hardly accessible by surgery, but far enough from the neural tissues^{6,7}.

Table-1. In current review, only 5 cases could be encountered in the literature

Author	Year	Sex	Age	Location	Surgery	Outcome
Jones	1987	M	8	Lamina	Enblock resection	Good
De Praeter	1999	M	21	Lamina	Hemilaminectomy	Good
De Praeter	1999	M	22	Lamina	Hemilaminectomy	Good
Amirjamshidi	2007	M	14	Lateral mass	Drilling	Good
Our case	2014	M	31	Lamina	Hemilaminectomy	Good

In those with comorbidities, or in those with less -accessible location, long-term conservative treatment with Aspirin or non-steroid anti-inflammatory drugs (NSAIDs), might result in disappearance of the tumor and its ultimate solidification⁷.

In summary, upper cervical region is rare location of osteoid osteoma. As imaging continued to evolve, the diagnosis of these lesions might be made easier and earlier. Affection of lamina of the upper cervical region is the simplest one which can be managed surgically either via tumor resection or through laminectomy. However, management of osteoid osteomas located at the pedicle or the body is a challenging issue which requires special consideration. Besides surgical intervention, recent evolution made by percutaneous CT guided radiofrequency has made the precise non-surgical resection of these tumors possible. Conservative treatment can be applied in those cases located at non-accessible location or in those with serious comorbidities.

REFERENCES:

1. Abdu WA, Provencher M. Primary bone and metastatic tumors of the cervical spine. *Spine* 1998; 23: 2767-2777.
2. Amirjamshidi A, Roozbeh H, Sharifi G, Abdoli A, Abbassion K. Osteoid osteoma of the upper cervical spine. *J Neurosurg Spine* 2010; 13: 707-714.
3. Azouz EM, Kozlowski K, Marton D, Sprague P, Zerhouni A, Asselah F. Osteoid osteoma and osteoblastoma of the spine in children. Report of 22 cases with brief literature review. *Pediatr Radiol* 1986; 16: 25-31.
4. Cohen MD, Harrington TM, Ginsburg WW. Osteoid osteoma: 95 cases and a review of the literature. *Semin Arthritis Rheum* 1983; 12: 265-281.
5. De Praeter MP, Dua GF, Seynaeve PC, Vermeersch DG, Klaes RL. Occipital pain in osteoid osteoma of the atlas. A report of two cases. *Spine* 1999; 24: 912-914.
6. Gangi A, Alizadeh H, Wong L, Buy X, Dietemann JL, Roy C. Osteoid osteoma: percutaneous laser ablation and follow-up in 114 patients. *Radiology* 2010; 242: 293-301.
7. Ghanem I. The management of osteoid osteoma: updates and controversies. *Curr Opin Pediatric* 2006; 18: 36-41.
8. Jones DA. Osteoid osteoma of the atlas. *J Bone Joint Surg* 1987; 69-B: 149-152.
9. Kirwan EO, Hutton PA, Pozo JL, Ransford AO. Osteoid osteoma and benign osteoblastoma of the spine: clinical presentation and treatment. *J Bone Joint Surg* 1984; 66-B: 21-26.
10. Levine AM, Boriani S, Donati D, Campanacci M. Benign tumors of the cervical spine. *Spine* 1992; 17: 399-406.
11. Ozaki T, Liljenqvist U, Hillmann A, Halm H, Lindner N, Gosheger G, Winkelmann W. Osteoid osteoma and osteoblastoma of the spine: experiences with 22 patients. *Clin Orthop Relat Res* 2002; 397: 394-402.
12. Pettine KA, Klassen RA. Osteoid-osteoma and osteoblastoma of the spine. *J Bone Joint Surg* 1986; 68-A: 354-361.
13. Pozo JL, Ransford AO. Osteoid osteoma and benign osteoblastoma of the spine: Clinical presentation and treatment. *J Bone Joint Surg* 1984; 66-B: 21-26.
14. Raskas D, Graziano G, Herzenberg J, Heidelberger KP, Hensinger RN. Osteoid osteoma and osteoblastoma of the spine. *J Spinal Disord* 1992; 5: 204-211.
15. Samaha EI, Ghanem IB, Moussa RF, Kharrat KE, Okais NM, Dagher FM. Percutaneous radiofrequency coagulation of osteoid osteoma of the "Neural Spinal Ring". *Eur Spine J* 2005; 14: 702-705.
16. Zileli M, Cagli S, Basdemir G, Ersahin Y. Osteoid osteomas and osteoblastomas of the spine. *Neurosurg Focus* 2003; 15(5): E5.