



## POSTERIOR FOSSA DECOMPRESSION AND CONCURRENT CORRECTION OF KYPHOSCOLIOSIS ASSOCIATED WITH CHIARI I MALFORMATION:

### *CHIARI I MALFORMASYONU İLE EŞLİK EDEN KİFOSKOLYOZUN AYNI SEANSTA POSTERİOR FOSSA DEKOMPRESYONU VE KORREKSİYONU: OLGU SUNUMU*

Mehmet Bülent BALIOĞLU<sup>1</sup>,  
Can Hakan YILDIRIM<sup>2</sup>,  
Akif ALBAYRAK<sup>1</sup>,  
Aytaç AKBAŞAK<sup>3</sup>

<sup>1</sup>Metin Sabancı Baltalimani Bone Diseases Training and Research Hospital, Baltalimani, 34470 Sarıyer, Istanbul, Turkey.

<sup>2</sup>Department of Neurosurgery, Kafkas University, School of Medicine, Kars, Turkey

<sup>3</sup>Özel Kadioglu Hastanesi, Aytekin Kotil (EskiFulya) Cad. No:25Pk 34394 Mecidiyeköy Istanbul, Turkey

#### SUMMARY:

A 16.5-year-old boy underwent concomitant posterior fossa decompression (PFD) for CM-I and spinal curve correction. Preop MRI evaluation revealed a CM-I, cervicothoracic syringomyelia. A thoracic kyphosis (62°) with a double thoracic scoliotic curve (40°, 42°) diagnosed. A preoperative neurological examination revealed numbness in the left arm and a slight loss of motor function. Under intraoperative neurophysiological monitoring (IONM), a PFD and resection of C1 vertebra were performed before the surgical correction of the spinal deformity. Posterior pedicle screws were applied to vertebrae between T2 and L1. IONM revealed a clear improvement in the left arm following PFD. A postoperative magnetic rezonans imaging revealed a satisfactory decompression at the craniocervical junction and a significant improvement of the syrinx. Follow-up study after 3 years later showed that proximal thoracic angle was 10°, main thoracic angle was 10°, and lateral Cobb angle was 42°. Deformity correction surgery and treatment for CM-I performed in one session seems relatively new. IONM is vital in assessing a patient's condition prior to surgical operation and changes, which occur during surgery, as well as evaluation the follow-up period. Our study showed that PFD and spinal curve correction can be conducted in a single surgical session.

**Keywords:** Chiari malformation; scoliosis; kyphosis; syringomyelia; posterior fossa decompression

**Level of Evidence:** Case report, Level IV

#### ÖZET:

Omurga eğriliği ve CM-I olan 16.5 yaşında erkek bir hastaya eş zamanlı olarak deformite düzeltilmesi ve posterior fossa dekompresyonu (PFD) uygulandı. Preop MRG ile CM-I ve servikotorasik siringomyeli, radyolojik olarak torakal kifoz (62°) ile çift torakal skolyoz eğriliği (40°, 42°) gözlemlendi. Preop nörolojik muayenede sol kolda uyuşukluk ve motor fonksiyonun hafif kaybı tespit edildi. İntraoperatif nörofizyolojik monitörizasyon (IONM) altında posterior fossanın ve C1 posteriorunun dekompresyonu omurga deformitesi düzeltilmesi öncesi aynı seansta uygulandı. Posterior pedikül vidaları T2-L1 vertebralara arasına uygulandı. PFD nu takiben IONM da sol kolda belirgin bir düzelme gözlemlendi. Cerrahi prosedür sırasında herhangi bir olumsuz yan etki gözlenmedi. Postoperatif MRG ile kranioservikal bileşkede belirgin bir dekompresyon ve sirinkste düzelme gözlemlendi. Postoperatif 3 yıl takip sonucunda her iki torakal açı 10° ve lateral Cobb açısı 42° olarak ölçüldü. Eş zamanlı omurga deformitesi ve CM-I in düzeltilmesi daha önce tanımlanmamıştır. Cerrahi öncesi, sırasında ve sonrası gelişebilecek nörolojik değişikliklerin değerlendirilebilmesi için IONM kullanılması çok önemlidir. Uygun olgularda PFD ve omurga eğriliği düzeltilmesi eş zamanlı olarak gerçekleştirilebilir.

**Anahtar Kelimeler:** Chiari malformasyonu, skolyoz, kifoz, siringomiyeli, posterior fossa dekompresyonu.

**Kanıt Düzeyi:** Olgu sunumu, Düzey IV

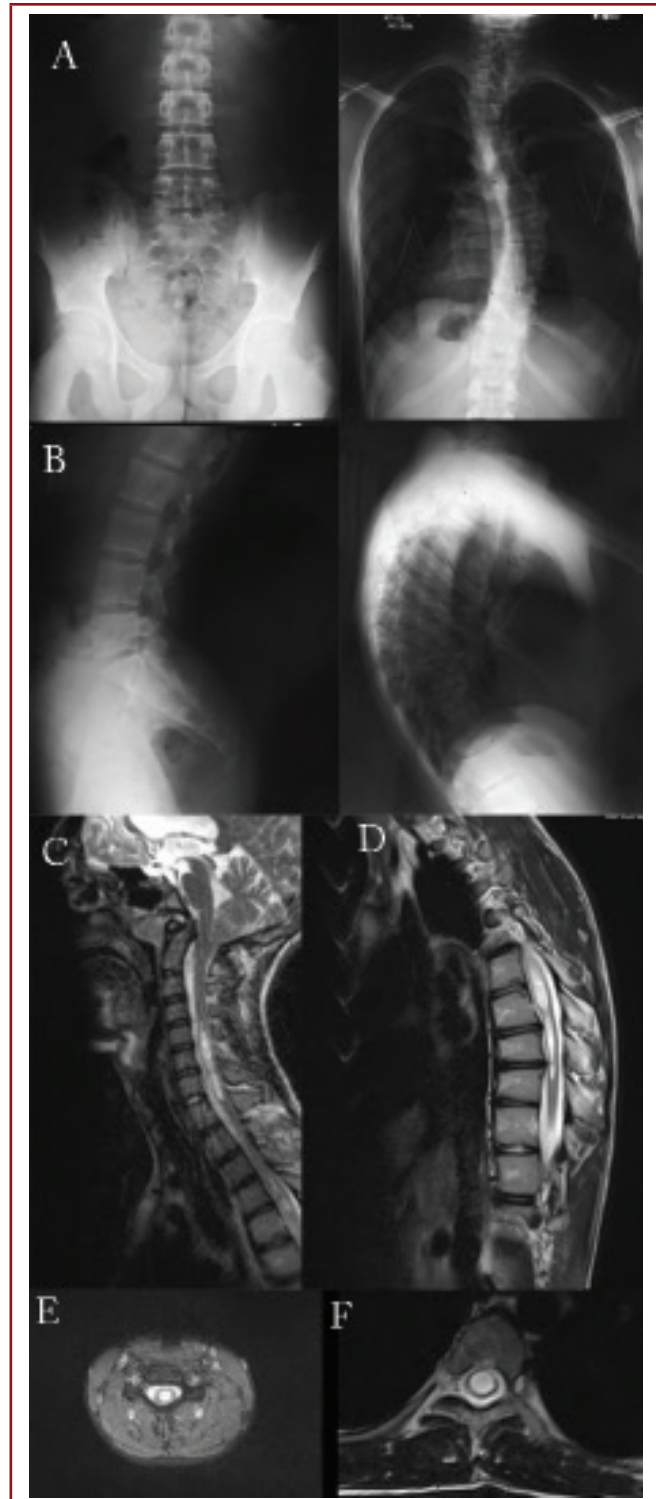
**Address:** Mehmet Bülent Balioğlu,  
Baltalimani Metin Sabancı Bone  
Diseases Training and Research  
Hospital. Rumeli Hisari Caddesi  
No: 62 Baltalimani, 34470,  
Istanbul / TURKEY  
**Tel.:** 0532 2521483  
**Fax:** 0 2123237082  
**E-mail:** mbbalibey@gmail.com  
**Received:** 12th October, 2015.  
**Accepted:** 17th December, 2016

## INTRODUCTION:

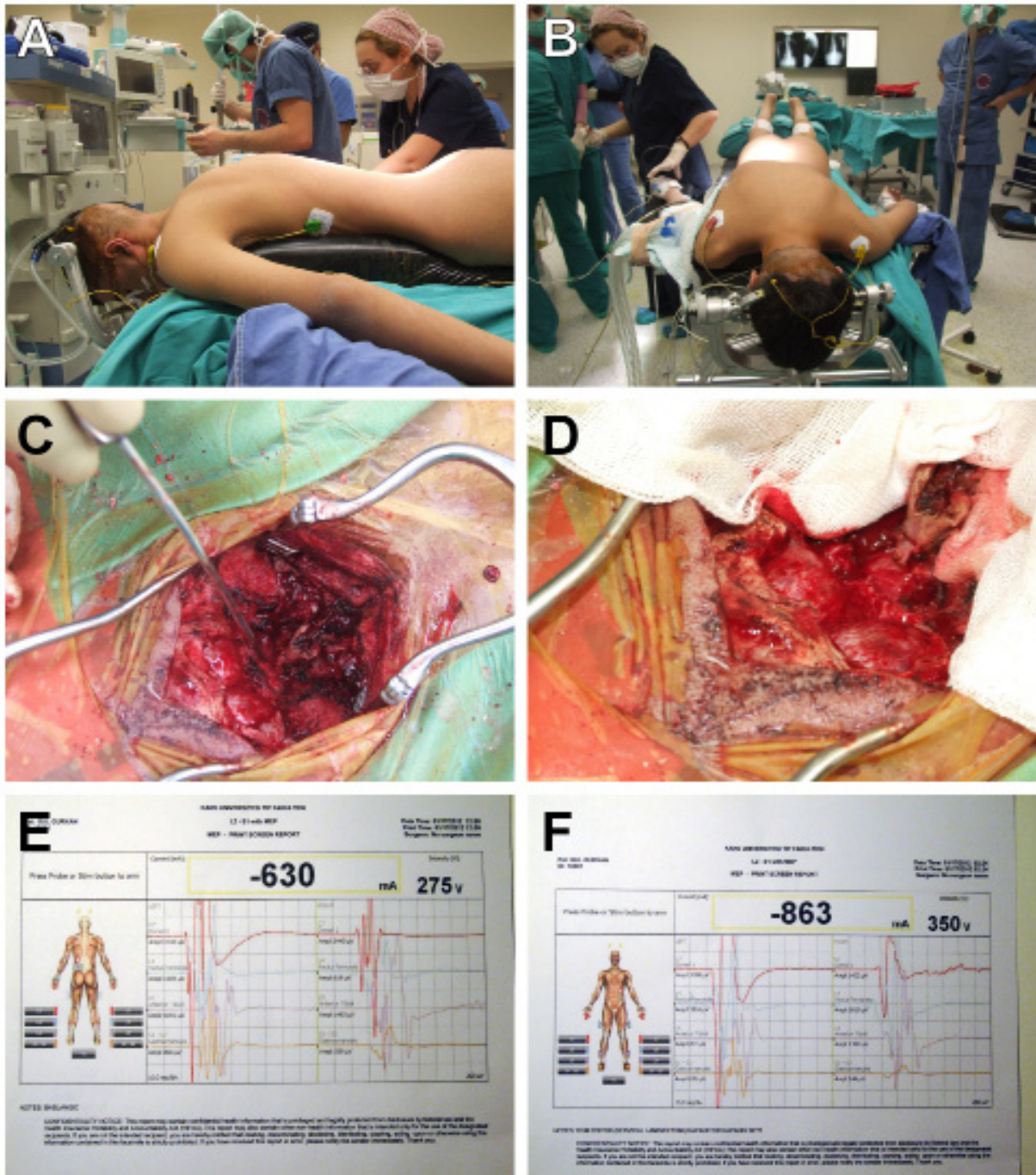
Chiari malformation (CM) associated with syringomyelia is one of the most common intraspinal anomalies in scoliosis<sup>6,15</sup>. Chiari malformation type 1 (CM-I) is defined as herniation of the cerebellar tonsils caudal to the foramen magnum<sup>1,4</sup>. Magnetic resonance imaging (MRI) also reveals a >4-5-mm herniation CM of the tonsils caudal to the foramen magnum<sup>4,7,17</sup>. Previous reports have indicated that scoliosis is found in 50-90% of CM patients and 15-65% of CM-I patients<sup>12,19</sup>. Several studies have investigated the development of scoliosis with CM or syringomyelia, but the mechanism is not fully understood<sup>28</sup>. Due to the neurological risks, posterior fossa decompression (PFD) or a syrinx shunt is recommended 3-6 months before spinal fusion<sup>5</sup>. Our study demonstrates a regression of the neurological findings and the deformity after a concurrent PFD and spinal fusion in an adolescent with CM-I, cervicothoracic syringomyelia and kyphoscoliosis deformity.

## CASE REPORT:

Double thoracic scoliosis and kyphosis deformities were observed by radiography in a 16.5 year-old male. The AP Cobb angles were 40° (T2-T5) and 42° (T6-T10), and the lateral thoracic Cobb angle was 62° (Fig 1). CM-I malformation (cerebellar tonsils extending 18 mm caudal to the foramen magnum) and an extensive syringomyelia cavity in the central spinal cord (between C4-T9, with the widest areas 5 x 6 mm at the level of C6 and 7 x 9 mm at the level of T6) were identified on MRI (Fig 1). During the preoperative neurological evaluation, there was a slight loss of sensation and motor function in the left arm and. No abnormal superficial abdominal reflex was found. Together with intraoperative neurophysiological monitoring (IONM), successive PFD and T2-L1 intervertebral fusion were implemented. The rods were successively placed with segmental compression on the convex side and at the original position on the concave side to prevent spinal cord tension (Fig 2).



**Figure 1.** (A-B) Preoperative AP X-ray film indicating double thoracic scoliosis (Cobb angle; 40° and 42°), Cobb angle on lateral graphy is 62°. (C-F) MRI showed extensive syringomyelia in CM-I and cervical and thoracic region (Syrinx level is between C4 and D9, Syrinx Width is 5 mm at C6 level and 7 mm at T6 level).

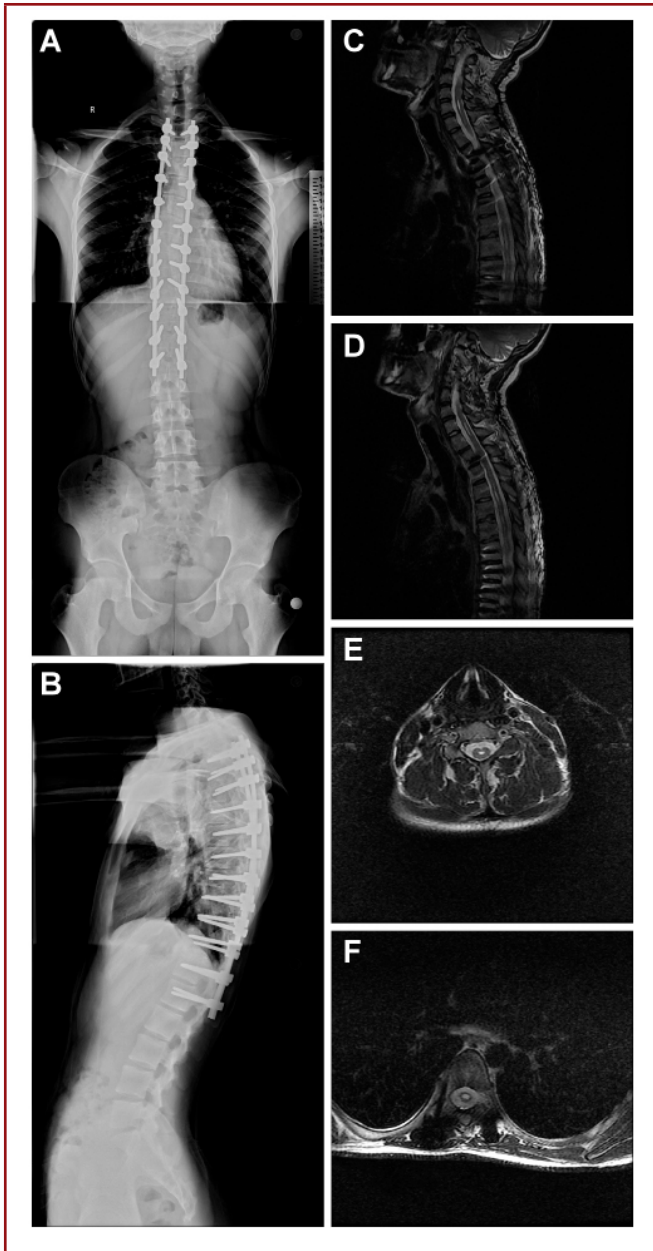


**Figure 2.** (A-B) Patient position. (C-D) Posterior suboccipital decompression and C1 laminectomy for CM-I and Syringomyelia. On IONM, an apparent recovery was observed on the left arm following suboccipital decompression. (E) Beginning and (F) post-decompression.

The operation lasted a total of 8 hours (1.5 hours decompression, 6.5 hours posterior instrumentation). The total blood loss was 1500 cc. On IONM, apparent recovery was observed in the left arm following PFD. No complications were observed during the surgical procedure. The patient was mobilized on post-op day 2 and discharged on day 7. A soft collar was used during post-op week 1. The patient was observed postoperatively in

3th, 6th and 12th months. In the final follow up at the end of 3 years, the AP Cobb angles were 10° both in T2-5 and T6-L1 levels, and the lateral Cobb angle was 42° at T2-L1 level. A recovery of neurological function and an evident decrease in the size of the syringomyelia were observed in MRI (between C4 and T8, with the widest areas 1.8 mm at the level of C5 and 3.9 mm at the level of T6) (Fig 3).





**Figure 3.** (A-B) During the final check in the end of postoperative 2.5 years, AP Cobb angle was 10° (T2-5) and 10° (T6-L1); lateral Cobb angle was 42° (T2-L1). (C-F) An evident decrease in the size of syringomyelia cavity was observed on MRI (Syrinx level is between C4 and T8, Syrinx Width is 1.8 mm at C5 level and 3.9 mm at T6 level).

## DISCUSSION:

Neurosurgical treatment of neural axis malformations is recommended prior to correction of a spinal deformity due to high risk of neurological disruption during the correction<sup>1,5,9,22</sup>. First, PFD or syrinx shunt application, then a vertebral correction 3 to 6 months later is recommended<sup>5</sup>. The

probability of observing a tethered cord with CM-I is 14%<sup>16,23</sup>. Intervention for intraspinal anomalies is recommended before the surgical decompression of the CM<sup>2,16,20</sup>. Most intraspinal anomalies identified with scoliosis are small syrinx or minimal cerebellar ectopies that do not require surgical intervention<sup>24</sup>. In most cases, rather than prophylactic neurological operations, careful observation is recommended for asymptomatic syringomyelia<sup>12</sup>. Some authors report that brace treatment in scoliosis with CM-I or syringomyelia is ineffective<sup>8</sup>. Others defend the use of brace treatment on skeletally immature patients with a Risser grade lower than 3 and a curvature between 20 and 50°<sup>29</sup>. In addition to PFD, it was shown that the use of bracing prevents curve progression, with the exception of double major curvature (64%)<sup>26</sup>.

It was shown that PFD conducted in younger patients, when the curvature is small, will mostly be beneficial for correction of the scoliosis curvature when scoliosis is present with CM-I<sup>29</sup>. Sengupta reported that 37.5% of 16 patients had fixed curvature, and 71.4% of those with fixed curvature were younger than 10 years old at the time of PFD<sup>25</sup>. Muhonen reported that scoliosis regressed in all patients under 10 years during decompression, including those with curvature greater than 40°<sup>18</sup>. Eule presented correction in 5 of 5 cases younger than 8 years old after decompression<sup>8</sup>. Bhangoo et al. reported that the required average age for scoliosis surgery was 158 months with an average Cobb angle of 76° in 13 patients with symptomatic CM and clinically-identified scoliosis who received PFD. These authors stated that the age (>10) and Cobb angle (>30°) were clearly related to the need for additional scoliosis surgery<sup>2</sup>. Flynn et al. found that the reasons for scoliosis progression in patients who received post-neurosurgical intervention were related to older age (>11), the existence of neurological symptoms, rotation of the vertebra object, double scoliosis curvature, and the presence of a wide curve (>50 kyphosis or >40 scoliosis)<sup>10</sup>. Brockmeyer et al. noted that patients with CM-I and syringomyelia in addition to scoliosis, who had PFD and duraplasty curvature greater than 50° and who were older than 12 years have a low chance of correction, whereas the percentage of correction or stabilization of a small curvature in patients younger than 10 years is high (62%)<sup>3</sup>. According to the Kelly et al., spinal deformities are more likely to improve after CM decompression of the hindbrain in young patients (<10 years old) with small coronal Cobb measurements (<40°). Spinal fusion is reserved for those curves that progress to deformities greater than 50°. Spinal deformity surgery may be more challenging in these patients, in part because of difficulties with intraoperative neurologic monitoring challenges<sup>13</sup>. Early neurosurgical intervention for intraspinal anomalies in younger patients ensures correction of the accompanying scoliosis deformity, and this is not possible in older patients and late interventions for curvature<sup>2,3,10,13,18,20,21,25</sup>.

Xie et al. suggested that PFD is not always required before spinal deformity correction in adolescents suffering from CM-I and scoliosis. Among 13 patients with adolescent scoliosis and CM-I with a wide curve who presented evident progression, 7 patients were treated with single-stage total posterior vertebral column resection (Cobb angle  $>90^\circ$ ), and 6 patients were treated with posterior pedicle screw fixation and deformity correction (Cobb angle  $>90^\circ$ ); no neurosurgical actions were taken to address the CM<sup>27</sup>. Xie et al. recommended a gradual primary correction of the deformity with segmental compression on the convex side during the procedure<sup>27</sup>. In our case, we also implemented segmental compression starting from the convex side first, as described by Xie et al., during the placement of rods after PFD and during the correction operation.

According to Zhu et al., for patients with both CM-I and spinal deformity, PFD may be effective for the regression of scoliosis in 64.8% of younger patients, whereas it may not prevent the progression of scoliosis in patients with a Cobb angle  $\geq 44.5^\circ$  and double curvature<sup>29</sup>. In our case, we also considered that PFD may be insufficient due to the age of the patient (16.5 years) and the presence of a double thoracic curve ( $42^\circ$  and  $40^\circ$ ) and kyphosis ( $62^\circ$ ) deformity, and we implemented the deformity correction during the same session.

During spinal surgery, IONM enables the evaluation of the intraoperative integrity of the corticospinal tract<sup>29</sup>. IONM is recommended during pathological treatment and spinal correction to minimize and prevent risks; it is particularly important in evaluating neurological correction during surgery. IONM is vital in assessing a patient's condition prior to surgical operation as well as the changes that occur during surgery, and for evaluation during the follow-up period<sup>14</sup>. Godzik et al. reported that the surgical management of spinal deformity in patients with underlying CM-I and syringomyelia carries a higher risk of new neurological deficit, despite adequate neurosurgical decompression and IONM<sup>11</sup>. We assessed our patient with IONM during surgery. Upon the completion of PFD, we detected an evident increase in the stimulation of the left upper extremity.

We performed a deformity correction during the same session and observed that the correction was maintained and no additional pathological changes developed. At the end of the 2.5-year postoperative period, we obtained satisfactory clinical and radiological results in a patient who was submitted to PFD and deformity correction surgery during the same session.

Deformity-correction surgery and treatment of CM-I performed in one session seems to be a relatively new approach. IONM is vital in assessing a patient's condition prior to surgical operation, as well as the changes may occur during the

surgery, and for evaluation during the follow-up period. Our study demonstrated that PFD and spinal curve correction can be conducted in a single surgical session.

## REFERENCES:

1. Akhtar OH, Rowe DE. Syringomyelia-associated scoliosis with and without the Chiari I malformation. *J Am Acad Orthop Surg* 2008; 16: 407-417.
2. Bhangoo R, Sgouros S. Scoliosis in children with Chiari I-related syringomyelia. *Childs Nerv Syst* 2006; 22: 1154-1157.
3. Brockmeyer D, Gollogly S, Smith JT. Scoliosis associated with Chiari I malformations: the effect of suboccipital decompression on scoliosis curve progression: a preliminary study. *Spine* 2003; 28: 2505-2509.
4. Cardoso M, Keating RF. Neurosurgical management of spinal dysraphism and neurogenic scoliosis. *Spine* 2009; 34: 1775-1782.
5. Charry O, Koop S, Winter R, Lonstein J, Denis F, Bailey W. Syringomyelia and scoliosis: a review of twenty-five pediatric patients. *J Pediatr Orthop* 1994; 14: 309-317.
6. Davids JR, Chamberlin E, Blackhurst DW. Indications for magnetic resonance imaging in presumed adolescent idiopathic scoliosis. *J Bone Joint Surg* 2004; 86-a: 2187-2195.
7. Dyste GN, Menezes AH, VanGilder JC. Symptomatic Chiari malformations. An analysis of presentation, management, and long-term outcome. *J Neurosurg* 1989; 71: 159-168.
8. Eule JM, Erickson MA, O'Brien MF, Handler M. Chiari I malformation associated with syringomyelia and scoliosis: a twenty-year review of surgical and nonsurgical treatment in a pediatric population. *Spine* 2002; 27: 1451-1455.
9. Farley FA, Song KM, Birch JG, Browne R. Syringomyelia and scoliosis in children. *J Pediatr Orthop* 1995; 15: 187-192.
10. Flynn JM, Sodha S, Lou JE, Adams SB Jr, Whitfield B, Ecker ML, Sutton L, Dormans JP, Drummond DS. Predictors of progression of scoliosis after decompression of an Arnold Chiari I malformation. *Spine* 2004; 29: 286-292.
11. Godzik J, Holekamp TF, Limbrick DD, Lenke LG, Park TS, Ray WZ, Bridwell KH, Kelly MP. Risks and outcomes of spinal deformity surgery in Chiari malformation, Type 1, with syringomyelia versus adolescent idiopathic scoliosis. *Spine J* 2015; 15(9): 2002-2008.

- 
12. Hankinson TC, Klimo P Jr, Feldstein NA, Anderson RC, Brockmeyer D. Chiari malformations, syringohydromyelia and scoliosis. *Neurosurg Clin N Am* 2007; 18: 549-568.
  13. Kelly MP, Guillaume TJ, Lenke LG. Spinal Deformity Associated with Chiari Malformation. *Neurosurg Clin N Am* 2015; 26(4): 579-585.
  14. Lo YL, Dan YF, Tan YE, Nurjannah S, Tan SB, Tan CT, Raman S. Intraoperative motor-evoked potential monitoring in scoliosis surgery: comparison of desflurane/nitrous oxide with propofol total intravenous anesthetic regimens. *J Neurosurg Anesthesiol* 2006; 18: 211-214.
  15. McIlroy WJ, Richardson JC. Syringomyelia: a clinical review of 75 cases. *Can Med Assoc J* 1965; 93: 731-734.
  16. Mehta VA, Gottfried ON, McGirt MJ, Gokaslan ZL, Ahn ES, Jallo GI. Safety and efficacy of concurrent pediatric spinal cord untethering and deformity correction. *J Spinal Disord Tech* 2011; 24: 401-405.
  17. Milhorat TH, Chou MW, Trinidad EM, Kula RW, Mandell M, Wolpert C, Speer MC. Chiari I malformation redefined: clinical and radiographic findings for 364 symptomatic patients. *Neurosurgery* 1999; 44: 1005-1017.
  18. Muhonen MG, Menezes AH, Sawin PD, Weinstein SL. Scoliosis in pediatric Chiari malformations without myelodysplasia. *J Neurosurg* 1992; 77: 69-77.
  19. Ono A, Ueyama K, Okada A, Echigoya N, Yokoyama T, Harata S. Adult scoliosis in syringomyelia associated with Chiari I malformation. *Spine* 2002; 27: 23-28.
  20. Ozerdemoglu RA, Denis F, Transfeldt EE. Scoliosis associated with syringomyelia: clinical and radiologic correlation. *Spine* 2003; 28: 1410-1417.
  21. Ozerdemoglu RA, Transfeldt EE, Denis F. Value of treating primary causes of syrinx in scoliosis associated with syringomyelia. *Spine* 2003; 28: 806-814.
  22. Potenza V, Weinstein SL, Neyt JG. Dysfunction of the spinal cord during spinal arthrodesis for scoliosis: recommendations for early detection and treatment. A case report. *J Bone Joint Surg* 1998; 80-a: 1679-1683.
  23. Royo-Salvador MB, Solé-Llenas J, Doménech JM, González-Adrio R. Results of the section of the filum terminale in 20 patients with syringomyelia, scoliosis and Chiari malformation. *Acta Neurochir* 2005; 147: 515-523.
  24. Samdani AF, Asghar J, Pahys J, D'Andrea L, Betz RR. Concurrent spinal cord untethering and scoliosis correction: case report. *Spine* 2007; 32: 832-836.
  25. Sengupta DK, Dorgan J, Findlay GF. Can hindbrain decompression for syringomyelia lead to regression of scoliosis? *Eur Spine J* 2000; 9: 198-200.
  26. Sha S, Zhu Z, Sun X, Zheng X, Liu Z, Wu T, Yan H, Qiu Y. Effectiveness of brace treatment of Chiari malformation-associated scoliosis after posterior fossa decompression: a comparison with idiopathic scoliosis. *Spine* 2013; 38: 299-305.
  27. Xie J, Wang Y, Zhao Z, Zhang Y, Si Y, Yang Z, Liu L, Lu N. One-stage and posterior approach for correction of moderate to severe scoliosis in adolescents associated with Chiari I malformation: is a prior suboccipital decompressional ways necessary? *Eur Spine J* 2011; 20: 1106-1113.
  28. Zhu ZZ, Qiu Y, Wang B, Yu Y, Qian B, Zhu F. Abnormal spreading and subunit expression of junctional acetylcholine receptors of paraspinal muscles in scoliosis associated with syringomyelia. *Spine* 2007; 32: 2449-2454.
  29. Zhu Z, Wu T, Zhou S, Sun X, Yan H, Sha S, Qiu Y. Prediction of curve progression after posterior fossa decompression in pediatric patients with scoliosis secondary to Chiari malformation. *Spine Deformity* 2013; 1: 25-32.