



# MULTIETIOLOGICAL SYNDROME: LOW BACK PAIN SOME ASPECTS OF PATHOGENESIS AND TREATMENT

## MULTİETİYOLOJİK SENDROM: BEL AĞRISI ÇEŞİTLİ PATOLOJİLER VE TEDAVİ

Yashar Raftaroğlu JALILOV<sup>1</sup>,  
Togrul Yasharoğlu JALILOV<sup>2</sup>,  
Elckan Mubarizoğlu  
CHALABIYEV<sup>2</sup>

<sup>1</sup>Doctor of Medicine, MD., Research manager of the department of Orthopedics for adults and trauma consequence of Scientific-Research Institute of Traumatology and Orthopedics of the Ministry of Health of Azerbaijan.

<sup>2</sup>Junior researcher of Scientific-Research Institute of Traumatology and Orthopedics of the Ministry of Health of Azerbaijan.

### SUMMARY:

The study presents data of hospital examination and treatment of 405 patients suffering from acute low back pain; in 247 of them have been revealed changes in bone mineral density of the vertebrae the type of osteopenia and osteoporosis. The majority of patients had bulging disk detected during MRI and CT examinations. 340 people have been managed to eliminate pain using conservative orthopedic treatment. Due to the inefficiency of the conservative-orthopedic treatment in 65 patients performed the surgery operations. It was noted the situations requiring different solutions:

- Mono-lateral pain with a large protrusion of one disk and minor protrusions of adjacent disks:
- Bilateral pain caused by large protrusions of 2 adjacent disks and instability or major segments of the protrusion of the 1st disk and moderate protrusion of adjacent disk involved in the creation of the clinical picture of bilateral pain.

In each of these situations, was performed intervention to ensure the ventral and dorsal decompression of spinal canal elements and the elimination of spinal instability.

Back pain is a multi-factorial phenomenon, and therefore the detection at MRI, CT studies of disk prolapse should not serve as a basis for making a hasty decision for surgical treatment. In most cases, conservative orthopedic treatment has a positive effect. In this case, the basis of the treatment should be made using of orthopedic aids in case of the prolonged immobilization and unloading of the spine, as well as measures to normalize bone mineral density. Surgical treatment should be undertaken only after failure of orthopedic treatment, followed by a continuation of conservative measures to normalize the mineral density of bone structures.

**Keywords:** multi-etiological lumbar pain, abnormalities of the lumbosacral area, osteopenia, osteoporosis, orthopedic treatment, surgical treatment.

**Level of evidence:** Retrospective clinical study, Level III

### ÖZET:

Bu çalışmada akut bel ağrısı olan 405 hastanın klinik muayene ve tedavi sonuçları sunulmuştur; bu hastaların 275'inde kemik mineral dansite ölçümlerinde osteopeni ve osteoporoz saptanmıştır. Hastaların büyük kısmında disk fıtıklaşmasını incelemek üzere MR ve BT incelemeler kullanılmıştır. 340 hastada konservatif tedavi uygulanmış, geri kalan konservatif tedavi yetersiz kalan 65 hastada cerrahi girişimler uygulanmışlardır. Hastalarda farklı çözümler gerektiren durumlar saptanmıştır.

**Bunlar:** 1) Tek taraflı ağrıya sahip tek diskin geniş protrüzyonu ve komşu dikste hafif minör protrüzyon hastalar ve 2) Çift taraflı ağrıya sahip birbirine komşu iki diskte geniş fıtıklaşma ve instabilite veya komşu diskteki orta düzey fıtıklaşmanın karşı taraf basısından sorumlu olduğu hastalar. Bu hastalarda anterior veya posterior dekompresyon ve spinal instabilitenin ortadan kaldırılması amacı ile cerrahi girişim uygulanmıştır. Bel ağrısı çok sebepli bir fenomen olup cerrahi tedaviye yönlendirilmede CT ve MR tek başına yardımcı olmamaktadır. Çoğu vakada konservatif tedavi hastanın yakınmalarının geçirilmesinde olumlu etkide bulunmaktadır. Diğer taraftan konservatif tedavi ve istirahat kemik dansitesindeki düşmeleri düzeltmektedir. Cerrahi tedavi sadece medikal tedavi yetmezliğinde, kemik mineral dansitesinde düzelme olana dek uygulanan medikal tedaviyi takiben uygulanmalıdır.

**Anahtar Kelimeler:** Multi etiyolojik lomber ağrı, lumbosakral bölge anomalileri, osteopeni, osteoporoz, ortopedik tedavi ve cerrahi tedavi.

**Kant Düzeyi:** Geriye dönük klinik çalışma, Düzey III

**Address:** Abbas Sahhat Street, 32, AZ-1007, Baki, Azerbaijan.  
**E-mail:** yashardjalilov@mail.ru, yasharjalilov@gmail.com  
**Tel.:** +994 50 213 43 46  
**Received:** 1st August, 2015  
**Accepted:** 4th September, 2015

## INTRODUCTION:

Most people of the world, at least several times in their lives complain of the low back pain and 1.3 % of them undergo relative surgical treatment<sup>1,2</sup>. Causes of the low back pain are different – multi-etiology syndrome. There have been defined three categories of the back pain in modern medicine<sup>3</sup>:

1. Specific, potential severe diseases of spine, spinal cord and visceral organs with irradiation of pain to spine.
2. Sciatic syndrome (Ischialgia).
3. Non-differentiated pain in the low back.

However, in recent decades there are a lot of data in clinical practice, which allow to join 2 or 3 categories in one “non-specific” group due to similar clinical manifestation and etiology factors. This issue was one of the main questions, discussed in VIII Interdisciplinary World Congress of back and pelvic pain on 27-31st October, 2013 in Dubai<sup>15</sup>. We also prefer to highlight two groups of back pain – specific and non-specific. Because of changes in mineral density of the spine bones in majority of the last one are met degenerative osteochondrosis, deformed spondilosis, spondylolistesis and hormonal spondylopathy<sup>11-12</sup>.

Back pain problems also are actual in Azerbaijan. Problems of the differential diagnosis, and complex orthopedic treatment and surgical treatment studies of the patients with back pain are organized and performed in the Orthopedics clinic for older by Scientific-Research Institute of Traumatology and Orthopedics - SRITO AR (Research manager Doctor of Medical Science Y. R. Jalilov). During recent decades we observed significant increase a number of the patient with lumbodinia and radicular type of pain in older and elderly people, who had osteoporosis different etiology. In addition, in younger people with pathology of disks and instability vertebral segment was often diagnosed mineral density of the bones type of osteopenia and osteoporosis. Therefore, it is important tactically find out which of the etiopathogenetic factors have priority in pain syndrome. Our studies of many years based on ambulatory and stationary observations of the several thousand patients showed that in the majority of the cases low back pain is not only multi-etiological, but multi-pathogenic. Several factors take part in occurrence of pain, each of them has been found out and considered in the treatment process during examination. For example, if the patient has a prolapse of the disk and mineral density changes of the bones, which create instability of the segments in most cases, so treatment should be directed for elimination of components developed pathology condition of the vertebrae. If consider to eliminate only of the prolapsed, and don't liquidate the osteoporosis and instabilities, so we can't reach a stable recover of the patient.

In recent several decade surgical interventions on herniation of a disk increased a lot, specially, among neuro-surgeons. It is suggested different types of the operations, noted a big

intention to economic availabilities and earlier activation of the patients<sup>5,13</sup>. It seems that a part of the authors see all problems in presence of the ballooning-out any disks, which compress spinal radices and if to eliminate it, so a person can return to previous life without any restrictions through several weeks. However, the life shows that such simplified approach is wrong and in most cases low back pain doesn't step back so easily. E.V. Spangfort<sup>2</sup> analyzed results of the surgical treatment of 2504 patients after exploration of the disks and detected in nearest post-operation time 30% of the patients noted low back pain again (failed back surgery syndrome).

Data of the many authors and our observations of many years show in most cases of spine osteochondrosis damages take a place in several segments simultaneously. Analyzes many of our MRT studies confirm opinions about different degree of the damage adjacent segments in poli-segmental osteochondrosis. Well-known conceptions about pathological changes in the vertebral segments in case of the osteochondrosis (A.I. Osna 1973; Kirkaldy-Willis W.H., Farfan H.F., 1982; White A.A., Panjabi M.M., 1990), explain more or less surely pathogenesis of the pain syndrome and other their clinical appearances in mono-segmental process. But many and different degree of damage of the adjacent segments in poly-segmental osteochondrosis create a lot of questions, which answers to them have not found yet:

1. What is the reason of the poli-segmental type damage of the adjacent vertebral segments of the spine?
2. What is the mechanism of the pain syndrome in case of the poly-segmental osteochondrosis?
3. What is right tactics of the treatment in case of poly-segmental type damage of the spine in osteochondrosis?

The goal of the study is analyze the main cause occurrence low back pain considering data of clinical-neurological examinations and investigations, and results of the conservative and surgical treatment of the patients in department for adults of SRITO AR.

## MATERIALS AND METHODS:

In this study is presented information about in-patient examination and treatment of 405 patients suffering from severe low back pain (Table-1).

340 people of them received conservative-orthopedic treatment and 65 surgical. It was used  $\chi^2$  tetrachoric criteria by Pearson for statistical analyze of the obtained results (12).

Consider the gender (264 men and 141 women), age and using method of the treatment we separated 405 patients. As shown in the table most of the patients were at the capable of working age, 31-50 age (180 people–44,44%). 107 people were

at the age of less than 30 (26,43%) and 118 people older than 51 age (29,13 %).

In order to diagnose precisely of the diseases is performed radiography of spine to all applied patients, specially, in recent years with digital radiographic devices which give possibilities to detect too deeply structural changes vertebrae, also MRT, CT, clinical-neurological examinations, also DEXA- and sono-densytometric examinations.

MR examinations detected in majority of the patients ballooning-out of the disks L3-4, L4-5 and L5-S1. Ballooning-out size of the disks in radiography films on MRT examinations showed that most of them have a sagittal diameter of 5-12mm. At the same time, in 186 patients were detected ballooning-out (3-7mm) and damage of the adjacent vertebrae disks poly-segmental type. In most cases of the poly-segmental process occurred damage of 2-3 disks, but sometimes it was observed damage of 4 disks different degree.

Roentgen-densitometer is performed by «HOLOGIC. QDR 4500-A» device. DEXA- densitometer of the spine was performed to 328 and 405 examined and treated patients in a hospital. 60 of patient was performed roentgen-densitometer of the spine and hip joint, also sono-densitometer of the calcaneal bones.

Except mentioned stationary patients DEXA-densitometer was performed to 635 ambulatory patients, with expressed pain kind of lumbodynia and lumbar ischialgia. At the present time, as known, DEXA- densitometer consider the more precisely method (gold method) of the bone mineral density identification among all known methods.

## RESULTS:

It allows differentiate bone mineral density (BMD-bone mineral density) and estimate it in T-score. T-value criteria between 1,0 to 2,5 estimate as an osteopenia, and from 2,5 and less as osteoporosis. Table-2 shows the results of the densitometer.

There were 328 patients: 197 men and 131 women. Bone mineral density of 81 patients may be estimated as normal, 69 men and only 12 women. There were no men at all in the T-criteria group less 3,5 вообще, but only. Among the patient with osteopenia prevailed men (94 men and 47 women), but with osteoporosis women (34 men and 51 women). As shown by above data in the most patients (247 people) along with ballooning-out of the disks noted changes bone mineral density – osteopenia and osteoporosis.

**Table-1.** Placement of the patients by age and methods of treatment.

Number of the patients due to methods of treatment	Age of the patients			
	18-30 age	31-50 age	> 50 age	Total
Surgical treatment	18 (4.4%)	32 (7.9%)	15 (3.7%)	65 (16.0%)
Conservative-orthopedic treatment	89 (22.0)	148 (36.5%)	103 (25.4%)	340 (84.0)
Total	107 (26.4%)	180 (44.4%)	118 (29.1%)	405 (100%)

**Table-2.** Placement of the patients by age and the results of the DEXA-densitometer.

Age of the patients	Results of the roentgen-densitometer by T-score				TOTAL
	+1: -1	-1:-2,5	-2,5:-3,5	-3,5 и <	
20 -30 age	31 43,1±5,8%	26 36,1±5,7%	12 16,7±4,4%	3 4,2±2,4%	72 (22,0±2,3%)
31-50 age	31 20,1±3,2%	72 46,8±4,0%	43 27,9±3,6%	8 5,2±1,8%	154 (47,0±2,8%)
51-60 age and more	19 18,6±3,9%	43 42,2±4,9%	30 29,4±4,5%	10 9,8±2,9%	102 (31,1±2,6%)
TOTAL	81 (24,7±2,4%)	141 (43,0±2,7%)	85 (25,9±2,4%)	21 (6,4±1,4%)	328 (100%)

**Note:** Poly-choric value by Pirson related between age and results of the densitometer:  $\chi^2=19,82$ ;  $p < 0,01$ . As shown from the table, by increasing of the age the bone mineral density is reducing reliably, which leads to reducing of T-score value.

In this studies were identified not only average data mineral density low back region of the spine, but also explicit data for each vertebra (L1-L4). These findings demonstrate, that more extend changes on mineral density were observed in low back vertebrae (often in L4). Most of patients with poly-segmental character of the damage of spine, in this case, is often found out T-value criteria within 1,5 – 2,8. It would be noted another fact, which say patients with reduced bone mineral density of the vertebrae during taking medical history – this is combination of the irradiated pain to the lower limbs (radicular pain) with pain occurred in spine in case of rotating the body in horizontal position (instability of the vertebral segments). In our opinion and by some researchers these cases, as called “hormonal spondylopathy”, lead to the disturbance of anatomical correlation between nerve roots and bone formation, which results to instability of the segments in consequence of reducing of the volume of the vertebral body and a laxity ligamentous apparatus.

In his studies on contrast myelography hernia ballooning-out of the intervertebral disks Y.R.Jalilov (1987), one of the leaders in this direction, showed the informativeness of the roentgenometer measurement of the spine canal width in diagnosis this disease<sup>7</sup>. In recent years for the purpose of measurement of the spine canal width on the medium damaged level of intervertebral disks (D1 value) and medium of the upper vertebral body (D2 value) we perform roentgenometer in MRT films. The ratio of D1 value to D2 gives mathematical index Id ( $D1/D2=Id$ ) – width of the canal on the degenerated disk level, which ideally should correspond to number 1. The less obtained number, the bigger degree narrow spine canal protruded by the degenerated disk.

Analysis performed by us examining more than two thousand patients in ambulatory condition and spondylogram of 405 patients in stationary condition showed significant number of the patients with low back pain on the lumbosacral segments have also congenital anomalies. So, from 405 patients examined in stationary condition revealed anomalies of the low back vertebrae in 253 cases (62,46 %). These anomalies is result static-dynamic disturbance of the vertebral biomechanics in low back vertebral and lumbosacral segments of the spine and this create the condition for occurrence degenerative process in intervertebral disks. Among them it may be point out sacralization, tropism of the articular process, lumbarization, “spina bifida”, diminution of the lumbosacral corner – “acutum sacrum” and etc.<sup>7</sup>.

In 340 of 405 patients the pain syndrome was possible to terminate performing complex conservative-orthopedic treatment. Because of continuation of the pain syndrome surgical intervention was performed in 65 patients. Consider the decision about operative intervention we take into account all examinations, but the first place neurological and clinical

picture of the diseases, which give the possibility to precise all the pathogenic components of the occurring pain syndrome in the operated patient. Depend on the clinical, neurological and investigated data we defined following situations, which require different decisions:

1. The clinical-neurological examination reveals mono-lateral pain syndrome. MRT examination finds out prolapse of the one disk narrowing space of the spine canal on the one side ( $\dot{I}d =$  since 0,44 to 0,55), and compressing root and other elements of the dural sack. MRT examination finds out less sufficient ballooning-out in adjacent segments ( $\dot{I}d =$  since 0,75 to 0,86), which don't leading to disko-radicular conflict. In patients with given situation was performed: –approaching (dorsal decompression) for revision of spinal canal and exploration of disk (ventral decompression) extended inter-laminectomy (with economical margin resection of the part of upper vertebral arch), segmental arthrodes junctura zygapophysealis. This situation detected in 38 patients.

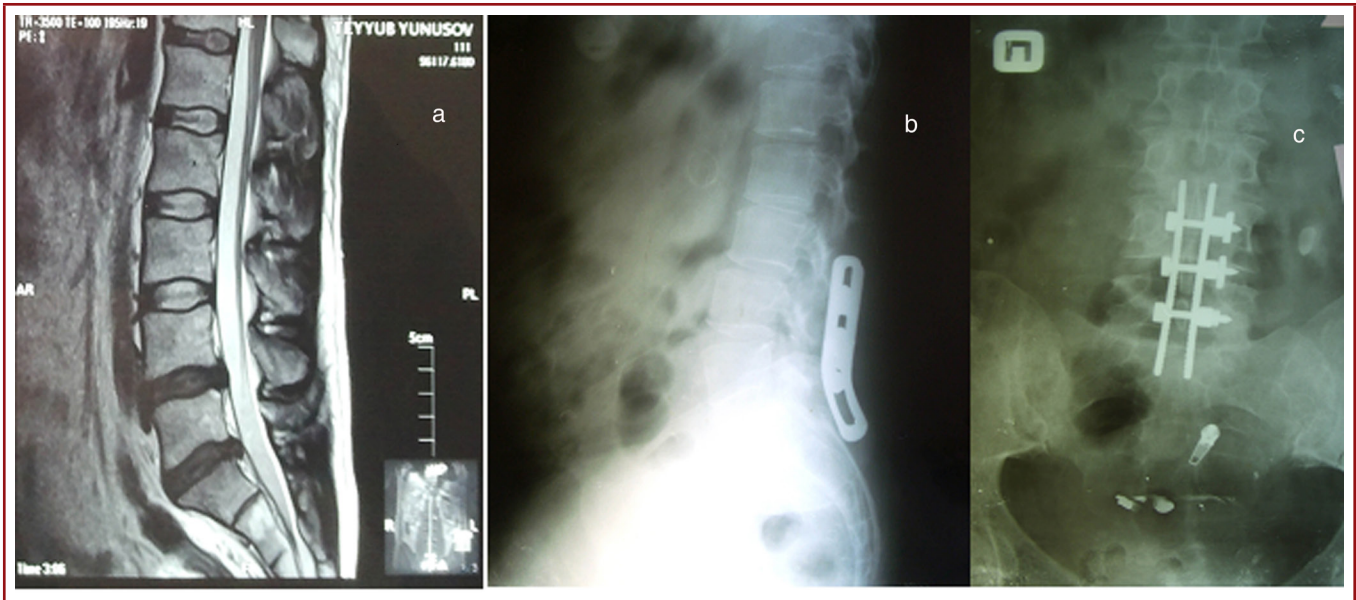
2. Bilateral pain syndrome with ballooning-out of two adjacent disks ( $\dot{I}d=0,44-0,55$ ) compressing of appropriate roots in different sides with occurrence of instabilities of the segments. In these cases it is performed extended inter-laminectomy on two level in appropriate sides, exploration of the disks (13 patients). If on the level of adjacent segment there is a ballooning-out ( $\dot{I}d=0,55-0,60$ ), which takes part in creating clinical picture of the bilateral pain syndrome, we perform inter-laminectomy, revision of the roots in order to decompress them and release from adhesions (14 patients). The operation was completed with segmental arthrodes on two level and fixation modified construction by Jalilov. This is very impotent to liquidate more totally of the instability and its prophylactics in the future. (Figures-1 and 2).

## DISCUSSION:

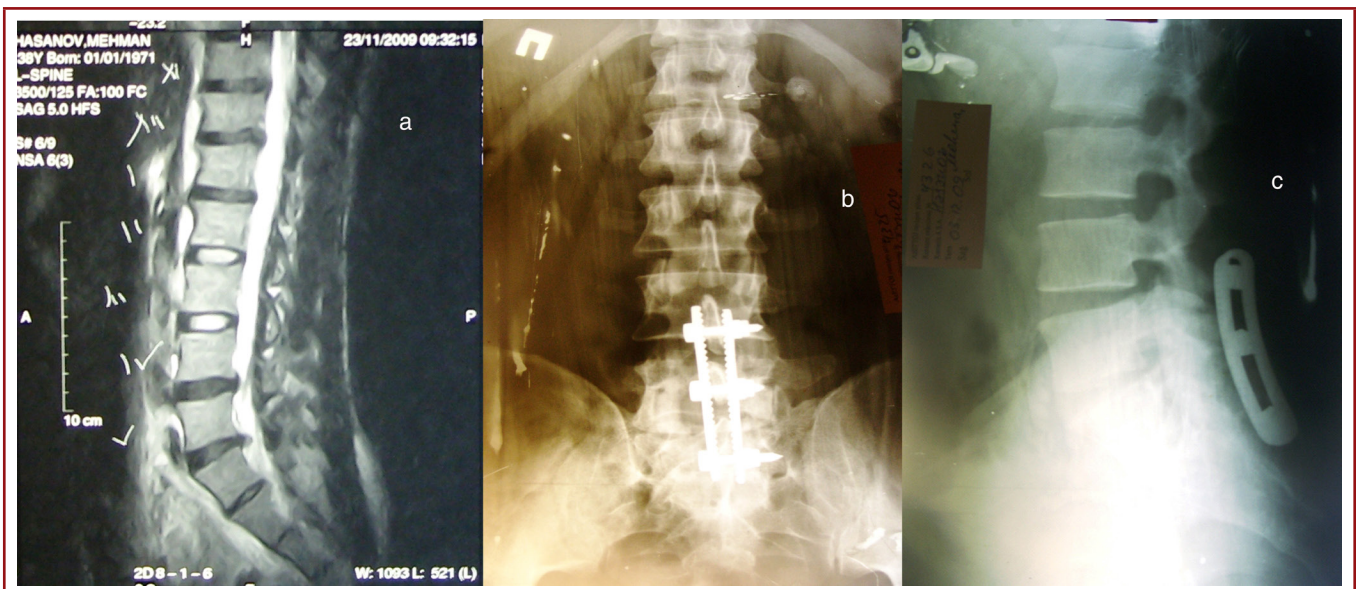
In case of degenerative damage of the disks compression in the severe period characterizes with irritative reactions as shooting pain, also as change of feeling in appropriate dermatoms. Irritative process appear in fail of blood microcirculation in nervous root, phlebolytis, edema and fibrosis of connective tissue. In occurrence of pain irritation of the receptors of the posterior longitudinal ligaments and instability take part in case of pathologic rotation movements in spine segment<sup>11-12</sup>.

Comparing the results of MRT, densitometer, radiography of spine and clinical-neurological it is possible express the opinion, in the most cases in mechanism of the manifesting of pain in our patients the significant role plays changes of the bone mineral density, which results in increasing the physical load to disks and the disturbance of anatomical correlation between nerve roots and bone formation.





**Figure-1.** MR and X-ray pictures of the patient A.Y. with prolapsed two disks: *a)* MRT films of the low back region before the operation; *b)* X-ray picture low back region after the operation of implantation in side projection; *c)* X-ray picture low back region after the operation of implantation in direct projection.



**Figure-2.** MR and X-ray pictures of the patient M.H. (38 years old) with prolapsed two disks:- *a)* MRT films of the low back region before the operation; *b)* X-ray picture low back region after the operation of implantation in side projection; *c)* X-ray picture low back region after the operation of implantation in direct projection.

It is possible, that this is one of the main cause following occurrence instabilities of the segments due to reducing vertebral body volume and a laxity ligamentous apparatus. Observed by us in part of the patients with reduced a spine mineral density a calcification of the cartilaginous and connective structure in spine segments is a respond compensator reaction of the organism, directed for the stabilization of the spine.

Results of our studies and other authors<sup>6-7,11</sup> show that in occurrence of low back pain syndrome degenerative spondyloarthrosis plays an important role. Performed the modern MRT, CT and digital spondylographic examinations give possibilities for more detailed research by the computer and therefore, we have chance to detect radiographic details, which could not see before. During performance such studies in some patients

except pathology of the disks also was established signs of degeneration of the cartilaginous surfaces in the intervertebral junctions – *junctura zupapophysealis* of the segments L4-5 and L5-S1, changes composed of subchondral osteosclerosis and ossification of the para-articular tissues. In some patients with spondylo-arthritis during the exacerbation low back pain some time was noted pain of ischialgia type, however, later this pain syndrome was released by conservative methods of treatment, particularly, by blocking with local steroids. We and other authors explain this with anatomical correlation between the indicated joints and spinal roots. It seems, the spinal roots expose to the affect para-articular inflammation and edema, as they pass near with this joints<sup>12</sup>.

Ballooning-out the disks observed during MRT and CT examinations have not been indicated for compulsory surgical operation yet. Our perennial experience shows for a part of majority of the patients it is necessary to implement conservative-orthopedic treatment till surgical intervention. We implement this treatment in condition with possible elimination physical loading affected to the disks. For this reasons the patients are appointed bed rest with a traction load of 10-14 kg. However, a traction with a heavy burden often results to the negative effect and should be implemented with individually and caution. During the conservative treatment we use corsets. The corsets are made by the specialists for each patient individually. We use the combination of the different analgesics, for the maximum reducing of pain syndrome during the treatment complex. In severe period of the disease we use “para-articular” local steroid blockers. In case of densitometer diagnosis of the osteoporosis we use alendronats, bisphosphonats and other preparations from this line in combination with the the treatment dose of calcium and vitamin D. In most cases by the implemented measures it was reached the elimination of pain syndrome. Latter the patients take ambulatory treatment during several weeks till complete restore of the working ability (Figure-3).

The degeneration process leads to the damage of the intervertebral disk and loss its main fixation function in case of the osteochondrosis, which results to fail of the supporting and moving functions of the spine segment. In addition, the prolapsed disk leads to ventral narrowing space of the spinal canal. Over a long period of time (usually it is so, rarely any patient in primary symptoms is operated) organism as a respond reaction to these disturbances answers with hypertrophy, hypermineralization (ossification) of the capsular-ligamentous apparatus of the segment for counteraction to the pathology movement in it. Continuation of the unhealthy condition leads to edema and subsequent some induration of the peridural fatty tissue. Thereby, in the results of chronic duration of the process to the ventral compression (from the side of prolapsed disk) elements of the spine canal joint and occur dorsal side compression. Data of many authors and our

observations show that in many cases damage of the disks in osteochondrosis has poly-segmental character, by other words, process extends not to one, but to several prolapsed disks. The surgical intervention should consider all these pathology changes in spine and eliminate them finally. By such way, surgical intervention in cases of the damage of the disks has to provide followings:

- provide whole dorsal (economical, but the sufficient access for the comprehensive revisoin) and ventral (exploration) decompression roots and other elements of spinal canal;
- don't exacerbate existing damage of the supporting and moving functions in case of instability of the segment, restore them in corpore (fixation-stabilization of the segment);
- in case of the poly-segmental damage to provide dorsal and ventral decompression of more damaged and taking part in the formation of pain syndrome segments.

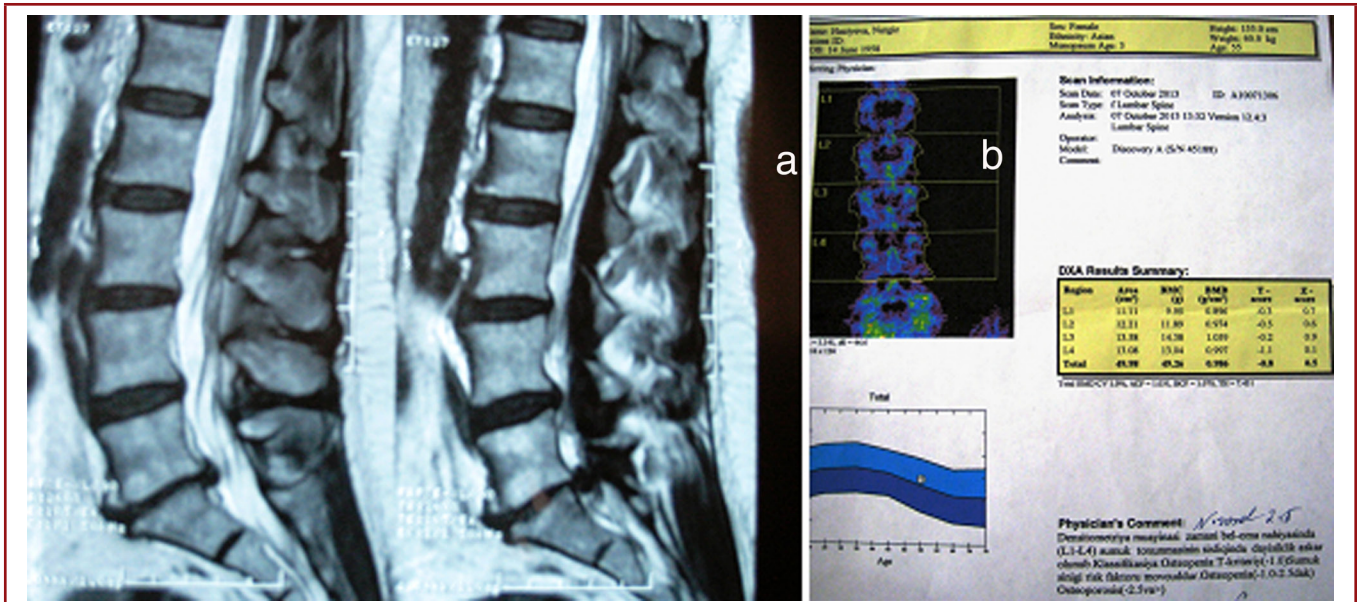
In addition, in elimination of the hernia we don't implement curettage of the disk cavity, because we consider it is dangerous and don't correspond to the goals of the operation manipulation. We could not find in the available literature a theme, where it was convincing confirmed the possibility of strengthening fibrosis formation process of the disk after curettage. This opinion was held by the vertebrologists taking part in 14<sup>th</sup> EFFORT IN Istanbul, showing the multiple complications of the curettage of the disk<sup>4</sup>.

As shown above for the prophylaxis and treatment of the instability we use modified by Jalilov Y.R. construction of Kazmin-Jalilov (RU Patent 1326161, 1987)<sup>1,3,9</sup>. The modified construction as opposed to its prototype has the less dimension and accounted for fixation one or two vertebral segments, which have instabilities.

According the works of Movshovich I.A. and Shotemor Sh. Sh. (1979) there was demonstrated that the instability of the vertebrae characterized appearing in its segments, mainly, pathological rotation movements. From this position, for liquidation or prophylaxis these movements, in our opinion, in majority of cases there is no necessity using interbody traspedicular constructions. The multiple news about successful using the spinal constructions like DIAM also confirm that for the liquidation of the instability of the segment a fixation through a spinous process supports a sufficient stability of spine and don't disturb its biomechanics. About 30 years experiments using modified construction of Kazmin-Jalilov<sup>3</sup> showed its high effectiveness in the treatment of the vertebral segments instability. The technical simplicity establishing of the construction provide possibility its extend use in the clinics, even with minimal availability of equipments.

The long-term results of the surgical treatment with duration of from three till 36 months was followed up in 62 patients.





**Figure-3.** The patient Q.N. 55 years: a) MR examination, hernia of the L5-S1 disks 7 mm.; b) DEXA-densitometer of spine – osteopenia (T -1,0).

In the first group 35 patients from 38 patients were followed up. The complete ending of pain syndrome was observed in 30 patients. In 5 patients pain was in the body and limbs, which we attributed already existed osteopenia and osteoporosis, therefore was performed the treatment with alendronats, biphosphonats, calcium medicine and vitamin D, after all observed release the pain.

The complete liquidation of the instability symptoms in patients of the second group was observed the next day after the operation. The pain in the limbs went away in all patients, however, in 4 patients a long time (several months) observed continuing hypoesthesia in the different region of the skin of foots, which was before the operation. Latter these occurrences regressed in 2 patients, and continue to be in 2 patients.

It was performed the analysis of occurrence of the low back pain causes in 405 patients who received the stationary treatment. In most patients MRT detected ballooning out the disks with the sagittal size 5-12 mm. At the same time the poly-segmental character of the damage was observed in 186 patients. 328 patients were undergone to the investigation of bone mineral density (DEXA- and sono-densitometer). In 247 them found out the changes of the bone mineral density type osteopenia and osteoporosis. In majority of the patients with the poly-segmental character of damage was observed diminish of the bone mineral density in vertebral tissue (T-criteria is between from -1,5 to -2,8). In 62,4 % of patients were revealed the develop anomaly of the lumbosacral part of spine, affected to biomechanics of spine, which also may cause the degenerative develop its segments.

The analysis of the examination results and treatments show that in the majority of cases the low back pain is not only multi-etiological, but also multi-pathological. In the development of the syndrome several facts take part. For example, the cause of the radicular syndrome is not only the ballooning out the disk, but also spondyloarthrosis, and the cause of the instability may be not only the damage of the disk, but also the changes of vertebral mineral density in spine, and each of these facts must be revealed and considered in the treatment process.

In 340 of people the pain syndrome was possible to liquidate by the conservative-orthopedic treatment, which the important component was to use the medicines improving the bone mineral density. In 65 patients due to the non-effectiveness of the conservative treatment was performed surgical treatment. The analysis of the follow up surgical treatment results showed a validity of the selected treatment tactic of one-sided and double-sided pain syndrome in ballooning out of the inter-vertebral spine disks. The sufficient ventral and dorsal decompression and also the measures for the stabilization of the spinal segments (segmental spondylodesis and metalofixation) provided releasing of pain syndrome in 30 patients from 35 patients of first group with one-side pain. Using a modernize fixer for the back fixation of spine allows to provide a significant stabilization of the instability segments of spine, about what inform nearest and follow up results of the surgical treatment in patients from second group. The intervention in the several damaged segments simultaneously in poly-segmental osteochondrosis with a dorsal and ventral or only a dorsal decompression of the compressed spine roots provided releasing of double-sided (bilateral) pain syndrome

---

in all 27 patients from this group. It is very important, to examine of the bone mineral density in all the patients before the operation with the subsequent implementation necessary measures for normalize the revealed abnormalities.

## REFERENCES:

1. Chiu C., John M.D., Kenneth K. Percutaneous decompression discectomy for non-extruded cervical herniated nucleus pulpous. Poster Presentation, *Congress of Neurological Surgeons Annual Meeting*. San Fransisco, September, 1995.
2. Crenshaw ED. *Campbell's Operative Orthopaedics*, 9<sup>th</sup> edition, 1997; p: 3715–3774.
3. DUODECIM Evidence-Based Medicine Guidelines. Medical Publications Ltd 2002; pp: 607. (In Russian)
4. EFORT. *European Instructional Lectures*. 14<sup>th</sup> EFORT Congress Istanbul, Turkey. EFORT IL Book, Volume-13, 2013.
5. Ivanchenko VN, Gromov MS. Ninel VG, Norkin IA. Minimally invasive surgery for treatment of discogenic pain syndrome in patients with lumbar degenerative disease. *Hir Pozvonoc* 2010; 3: 48–51. (In Russian)
6. Jalilov YR., Subahsi M. The surgical principle of stable and unstable lumbar osteochondrosis. *Acta Orthop Tramadol Turcica* 1994; 28(3): 155-157.
7. Jalilov YR, Jalilov TY., Chelyabiev EM. Orthopedic and surgical treatment of poly-segmental protrusions of intervertebral discs. *Azer J Orthop Traumatol* 2010; (2): 20–24.
8. Kazmin AI, Vetrile ST, Jalilov YR, Nechvolodova OL. Contrast myelography in diagnosing hernia protrusion of the intervertebral disc in lumbar osteochondrosis. *Vestnik Rentgenologii Radiologii* 1987; (6): 21-26. (In Russian)
9. Kazmin AI, Jalilov YR, Frolkin EE. Fixator of the spine. RU Patent 1326261, filed 04.07.1985, publ. 30.07.1987. (In Russian)
10. Kornilov NV. Traumatology and Orthopaedics: Guidelines for Physicians. St. Petersburg, 2006; 4: 255–260. (In Russian)
11. Kraemer J. Intervertebral Disc Diseases. Translation from English. Moscow, 2013. (In Russian)
12. Mironov SP, Kotelnikov GP. *Orthopaedics: National Gudelines*, Moscow, 2008; p:832. (In Russian)
13. Pedachenko EG, Kuschaev SV. Endoscopic Spinal Neurosurgery. Kiev, 2000. (In Russian)
14. Petrie A, Sabin C. Medical Statistics at a Glance. Translation: Leonov VP. Moscow, 2009. (In Russian)
15. 8th Interdisciplinary World Congress on Low Back & Pelvic Pain. United Arab Emirates, October 27-31, Dubai 2013; pp: 290-331.