



## LUMBAR INTERVERTEBRAL FORAMINAL MORPHOMETRY

### LOMBER İNTERVERTEBRAL FORAMEN MORFOMETRİSİ

Luay ŞERİFOĞLU<sup>1</sup>,  
Alptekin GÜL<sup>2\*</sup>,  
Sinem GERGİN<sup>3</sup>,  
Hanife Gülden DÜZKALIR<sup>4</sup>,  
Recep BAŞARAN<sup>5</sup>,  
Ali Haluk DÜZKALIR<sup>6</sup>,  
Selçuk ÖZDOĞAN<sup>2</sup>

<sup>1</sup>Neurosurgeon, Esenyurt State Hospital, Department of the Neurosurgery, İstanbul

<sup>2\*</sup>Resident, Dr.Lütfi Kırdar Kartal Training and Research Hospital, Department of the Neurosurgery, İstanbul.

<sup>2</sup>Neurosurgeon, Dr.Lütfi Kırdar Kartal Training and Research Hospital, Department of the Neurosurgery, İstanbul.

<sup>3</sup>Specialist of Anatomy, Yeditepe University, Medical Faculty, Department of the Anatomy, İstanbul

<sup>4</sup>Radiologist, Atatürk State Hospital, Department of Radiology, Zonguldak

<sup>5</sup>Göztepe Training and Research Hospital, Department of the Neurosurgery, İstanbul.

<sup>6</sup>Biruni University Hospital, Department of Neurosurgery, İstanbul.

**Address:** Selçuk ÖZDOĞAN,  
Kartal Dr. Lütfi Kırdar Eğitim ve  
Araştırma Hastanesi Cevizli-Kartal  
İstanbul / Türkiye  
**Tel:** 0506 7637173  
**Fax:** 0216 5784965  
**E-mail:** drselcukozdogan@hotmail.com  
**Received:** 14th October, 2015  
**Accepted:** 17th December, 2015

#### SUMMARY:

**Objective:** The aim of the study is to collect data from all levels of lumbar intervertebral foramen on asymptomatic adults.

**Materials and Method:** We inspected 60 thin-layered reconstructive computed tomography scans of whole spine that obtained in adult patients who were admitted to our hospital for emergency treatment retrospectively.

**Results:** 60 patients (30 females, 50.0%, and 30 males, 50.0%) were included in the study. Accordingly, mean age was  $47.8 \pm 22.3$  years. When the measurements were compared between females and males, none of the measurements were found to be different between females and males. Largest and smallest values for length were found to be at L2, and L5 level, respectively. And, largest and smallest values for width were found to be at L2, and L5 level, respectively.

**Conclusions:** The database should also enable both clinicians and researchers to better understand normal lumbar intervertebral foraminal morphometry.

**Key Words:** Lumbar intervertebral foramina, Reconstructive computed tomography, Intervertebral foramina morphometry.

**Level of Evidence:** Morphometric study, Level III

#### ÖZET:

**Amaç:** Asemptomatik erişkinlerin tüm lomber vertebral seviyelerinin foraminal verilerini toplamaktır.

**Materyal ve Metod:** Acil servise başvuran 60 hastanın ince kesit bilgisayarlı tomografi verileri retrospektif olarak incelendi.

**Sonuçlar:** Çalışmaya 60 hasta (30 kadın, %50.0, 30 erkek %50.0) dahil edildi. Ortalama hasta yaşı  $47.8 \pm 22.3$  olarak bulundu. Sonuçlar kadın ve erkekler arasında karşılaştırıldığında fark bulunamadı. En geniş boy ve en oranı L2 seviyesinde, en dar ise L5 seviyesinde hesaplandı.

**Çıkarım:** Toplanan veritabanı hem klinisyenler hemde araştırmacıların normal lomber foraminal morfometriyi daha kolay anlamasını sağlayacaktır.

**Anahtar kelimeler:** Lomber vertebral foramen, Rekonstrüktif bilgisayarlı tomografi, Vertebral foraminal morfometri.

**Kanıt Düzeyi:** Morfometrik analiz, Düzey III

## INTRODUCTION:

Diagnosing lumbar foraminal stenosis with conventional imaging can be challenging and requires a methodical assessment of the patient's history and baseline characteristics, as well as, imaging evaluation with direct measurement of the foramen, alignment and degenerative changes<sup>3</sup>. The dimensions of the foramen are much smaller on the symptomatic side in those with foraminal stenosis as compared to those with central stenosis<sup>7</sup>.

However, numerous studies have noted the limitations of magnetic resonance imaging (MRI) at assessing foraminal stenosis, computed tomography (CT) is becoming the modality of choice to evaluate the foraminal area and facet degeneration in patients with radicular pain concerning for foraminal stenosis<sup>8,11</sup>.

Our study was made to collect data from all levels of lumbar intervertebral foramen on asymptomatic adults to compare with the symptomatic ones<sup>7</sup>.

## MATERIALS AND METHODS

We inspected 60 thin-layered reconstructive CT scans of whole spine that obtained in adult patients who were admitted to our hospital for emergency treatment retrospectively. Inclusion criterias for patients in the study are, patients had to be older than 17 years and have undergone a complete 3D-CT scan of the lumbar vertebra and had no pathological spinal trauma or disease. Sagittal reconstructive 3D-CT images used to measure all levels of lumbar level foraminal length and width (Figure-1). Patients were excluded if their radiological examinations were not sufficient for the proposed measurements or if they were known to have pathological conditions of the lumbar spine.

## STATISTICAL ANALYSIS

Descriptive data were presented as frequencies and percent for categorical variables, and as mean and standard deviation for numerical variables. Independent group comparisons between both genders were performed with Mann-Whitney U test. P values lower than 0.05 (Type I error level of 5%) was considered as statistically significant result. All analyses were performed by using IBM SPSS Statistics for Windows, Version 21.0 (Armonk, NY: IBM Corp.).

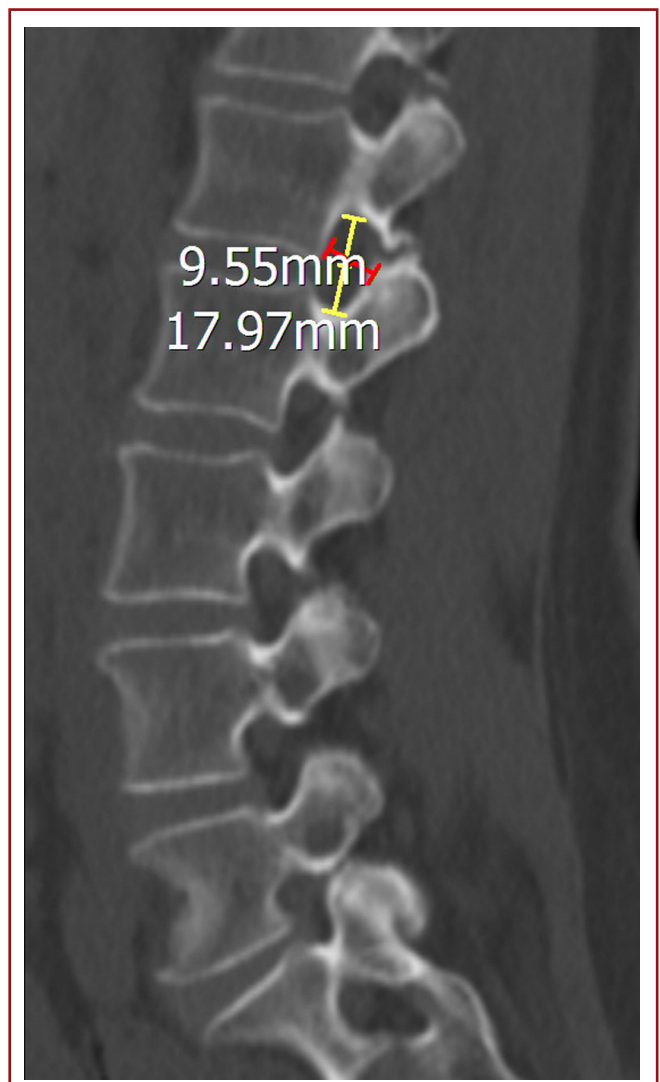
## RESULTS:

60 patients (30 females, 50.0%, and 30 males, 50.0%) were included in the study. General characteristics of patients were presented in Table-1. Accordingly, mean age was  $47.8 \pm 22.3$  years.

**Table-1.** General characteristics of patients

|        | n           | %         |
|--------|-------------|-----------|
| Gender |             |           |
| Female | 30          | 50.0%     |
| Male   | 30          | 50.0%     |
|        | <b>Mean</b> | <b>SD</b> |
| Age    | 47.8        | 22.3      |

When the measurements were compared between females and males, none of the measurements were found to be different between females and males. Largest and smallest values for length were found to be at L2, and L5 level, respectively. And, largest and smallest values for width were found to be at L2, and L5 level, respectively Comparisons between genders are presented in Table-2.



**Figure-1.** Sagittal reconstructive 3D-CT images used to measure all levels of lumbar level foraminal length and width.

**Table 2.** Comparisons of measurements between genders

|             | Female |      | Male |      | P     |
|-------------|--------|------|------|------|-------|
|             | Mean   | SD   | Mean | SD   |       |
| Age         | 50.6   | 21.7 | 45.0 | 23.7 | 0.571 |
| L1_Length_L | 17.0   | 2.5  | 18.4 | 3.3  | 0.199 |
| L1_Length_R | 17.1   | 2.8  | 18.5 | 3.4  | 0.199 |
| L1_Width_L  | 8.6    | 1.6  | 9.7  | 1.0  | 0.112 |
| L1_Width_R  | 8.6    | 1.6  | 9.8  | 1.2  | 0.096 |
| L2_Length_L | 19.0   | 2.4  | 19.5 | 3.0  | 0.596 |
| L2_Length_R | 18.7   | 2.8  | 19.2 | 3.0  | 0.570 |
| L2_Width_L  | 8.8    | 1.1  | 9.3  | 0.9  | 0.272 |
| L2_Width_R  | 8.7    | 1.1  | 9.4  | 0.9  | 0.150 |
| L3_Length_L | 17.9   | 2.4  | 19.1 | 2.5  | 0.162 |
| L3_Length_R | 17.9   | 2.2  | 19.0 | 2.6  | 0.290 |
| L3_Width_L  | 8.3    | 1.5  | 9.2  | 1.2  | 0.325 |
| L3_Width_R  | 8.2    | 1.6  | 9.1  | 1.2  | 0.272 |
| L4_Length_L | 17.2   | 1.4  | 17.4 | 1.9  | 0.384 |
| L4_Length_R | 17.5   | 1.6  | 17.4 | 2.2  | 0.970 |
| L4_Width_L  | 7.8    | 1.4  | 8.1  | 1.3  | 0.597 |
| L4_Width_R  | 7.7    | 1.4  | 8.2  | 1.4  | 0.450 |
| L5_Length_L | 15.5   | 1.6  | 17.2 | 2.2  | 0.082 |
| L5_Length_R | 15.5   | 1.6  | 16.6 | 2.2  | 0.160 |
| L5_Width_L  | 7.8    | 1.5  | 8.6  | 1.5  | 0.120 |
| L5_Width_R  | 7.7    | 1.5  | 8.6  | 1.6  | 0.212 |

**DISCUSSION:**

Radicular symptoms are due to compression of the dorsal root ganglion and root that cause of lumbar disk herniation and spinal stenosis. The most common cause of failed spine surgery is an inadequate decompression. This can be secondary to an inability to execute the surgical plan, but more commonly occurs from unrecognized stenosis<sup>1</sup>. Preoperative identification of lumbar spine foraminal stenosis is important given the surgical plan can differ greatly from that for lateral recess stenosis.

The diagnosis of lumbar foraminal stenosis is important because this clinical entity is often associated with failed back surgery syndrome. Although MRI is widely used and

is considered by many as an appropriate tool for studying spine pathologies, there is limited data to suggest that MRI examinations are sufficiently sensitive or specific for the diagnosis of lumbar foraminal stenosis<sup>2,6</sup>.

Torun et al reported from a cadaveric study that the widest diameter of lumbar intervertebral foramina was determined for the L4 nerve root with a mean of 3.9 mm, the narrowest for the L1 nerve root with a mean of 3.3 mm and no significant difference was observed between genders<sup>10</sup>. Foraminal pathologies at the L1-L2 and the L2-L3 distances are frequently asymptomatic. Stephens et al concluded that the cross sectional area and the height of the foramen do not change, although the foramen becomes auricular in the case of disk pathology of the upper two levels, which explains why

the foraminal pathologies at this level are usually silent<sup>9</sup>. There have been only a few anatomic studies aimed at determining mean foraminal heights. In one such study, Epstein et al measured it as 13 to 15 mm, whereas Magnusson determined it to be 11 to 17 mm<sup>4,5</sup>.

There were significant differences between foraminal measurements carried out on MRI, CT and on the cadavers. This is due to the facts like race, gender, age, osteoporosis degree, pathologies and observers measurement style. More studies should be made to get a true mean values of intervertebral foramina.

The database should also enable both clinicians and researchers to better understand normal lumbar intervertebral foraminal morphometry. The development of this normal database should further allow for more meaningful evaluation of the dimensions of intervertebral foraminal pathologic states, such as spinal stenosis, disc degeneration, disk protrusion or prolapse, facet arthropathy, and spondylosis.

## REFERENCES:

1. Attias N, Hayman A, Hipp JA, Noble P, Esses SI. Assessment of magnetic resonance imaging in the diagnosis of lumbar spine foraminal stenosis—a surgeon's perspective. *J Spinal Disord Tech* 2006; 19: 249–256.
2. Cramer GD, Cantu JA, Dorsett RD, Greenstein JS, McGregor M, Howe JE, Glenn WV. Dimensions of the lumbar intervertebral foramina as determined from the sagittal plane magnetic resonance imaging scans of 95 normal subjects. *J Manipulative Physiol Ther* 2003; 26: 160–170.
3. Demondion X, Manelfe C, Prere J, Francke J. Lumbar lateral recess and intervertebral foramen. Radio-anatomical study. *J Radiol* 2000; 81: 734-745.
4. Epstein BS, Epstein JA, Lavine L. The effect of anatomic variations in the lumbar vertebrae and spinal canal on cauda equina and nerve root syndromes. *AmJ Roentgenol Radium Ther Nucl Med* 1964; 91: 1055-1063.
5. Magnusson PB. Differential diagnosis of pain in the lower back accompanied by static pain. *Ann Surg* 1944; 119: 878-901.
6. Nemoto O, Fujikawa A, Tachibana A. Three-dimensional fast imaging employing steady-state acquisition MRI and its diagnostic value for lumbar foraminal stenosis. *Eur J Orthop Surg Traumatol Orthop* 2014; 24(Suppl 1): S209–S214.
7. Ohba T, Ebata S, Fujita K, Sato H, Devin CJ, Haro H. Characterization of symptomatic lumbar foraminal stenosis by conventional imaging. *Eur Spine J* 2015; 24: 2269–2275.
8. Smith GA, Aspden RM, Porter RW. Measurement of vertebral foraminal dimensions using three-dimensional computerized tomography. *Spine* 1993; 18(5): 629-636.
9. Stephens MM, Evans JH, O'Brien JP. Lumbar intervertebral foramina An in vitro study of their shape in relation to intervertebral disc pathology. *Spine* 1991; 16(5): 525-529.
10. Torun F, Dolgun H, Tuna H, Attar A, Uz A, Erdem A. Morphometric analysis of the roots and neural foramina of the lumbar vertebrae. *Surgical Neurology* 2006; 66: 148–151
11. Yamada K, Aota Y, Higashi T, Ishida K, Niimura T, Konno T, Saito T. Roentgenographic and computed tomographic findings in symptomatic lumbar foraminal stenosis. *Eur Spine J* 2014; doi:10.1007/s00586-014-3683-2