



CRANIOVERTEBRAL JUNCTION MORPHOMETRIC EVALUATION WITH RECONSTRUCTIVE COMPUTED TOMOGRAPHY

REKONSTRÜKTİF BİLGİSAYARLI TOMOGRAFİ İLE KRANİOVERTEBRAL BİLEŞKENİN MORFOMETRİK İNCELEMESİ

Nail DEMİREL¹,
Alptekin GÜL^{2*},
Sinem GERGİN³,
Hanife Gülden DÜZKALIR⁴,
Recep BAŞARAN⁵,
Ali Haluk DÜZKALIR⁶,
Cumhur Kaan YALTIRIK⁷,
Selçuk ÖZDOĞAN²

¹Neurosurgeon, İstanbul Training and Research Hospital, Department of the Neurosurgery, İstanbul

²Resident, Dr.Lütfi Kırdar Kartal Training and Research Hospital, Department of the Neurosurgery, İstanbul.

²Neurosurgeon, Dr.Lütfi Kırdar Kartal Training and Research Hospital, Department of the Neurosurgery, İstanbul.

³Specialist of Anatomy, Yeditepe University, Medical Faculty, Department of the Anatomy, İstanbul

⁴Radiologist, Atatürk State Hospital, Department of Radiology, Zonguldak

⁵Neurosurgeon, Göztepe Training and Research Hospital, Department of the Neurosurgery, İstanbul.

⁶Neurosurgeon, Biruni University Hospital, Department of the Neurosurgery, İstanbul

⁷Neurosurgeon, Yeditepe University Hospital, Department of the Neurosurgery, İstanbul

Address: Selçuk ÖZDOĞAN,
Kartal Dr. Lütfi Kırdar Eğitim ve
Araştırma Hastanesi Cevizli-Kartal
İstanbul Türkiye
Tel: 0506 7637173
Fax: 0216 5784965
E-mail: drselcukozdogan@hotmail.com
Received: 11th September, 2015.
Accepted: 14th December, 2015.

SUMMARY:

Objective: The aim of the study is to evaluate information from reconstructive computed tomography parameters of the craniovertebral junction(CVJ) in asymptomatic individuals.

Materials and Method: We inspected 98 consecutive CVJ reconstructive computed tomography scans obtained in adult patients who were admitted to our hospital for emergency treatment of non-CVJ conditions retrospectively.

Results: 98 patients (46 females, 46.9 %, and 52 males, 53.1 %) were included in the study. Accordingly, mean age was 51.7 ± 18.7 years, mean Chamberline-Odontoid Distance was 2.5 ± 1.2 mm, mean Grabb-Oakes was 6.8 ± 1.4 mm, mean Atlantodental Interval was 1.4 ± 0.5 mm, mean Foramen Magnum AP was 34.3 ± 3.2 mm, and mean Foramen Magnum Lat-Lat, Coronal was 30.0 ± 2.7 mm. When the measurements were compared between females and males, it was found that only foramen magnum anterior-posterior(AP) distance was significantly different between genders (33.1 ± 2.6 mm in females, 35.4 ± 3.4 mm in males, $p=0.011$), and males had larger foramen magnum AP distance values. Age ($p=0.960$), Chamberline-Odontoid Distance ($p=0.952$), Grabb-Oakes ($p=0.068$), Atlantodental Interval ($p=0.680$), and Foramen Magnum Lat-Lat Coronal ($p=0.741$) were similar between females and males.

Conclusions: When evaluating CVJ malformations, surgeons should take into account the normal ranges based on computed tomography scan instead of those obtained from plain radiographs.

Key Words: Craniovertebral junction, reconstructive computed tomography, craniovertebral junction morphometry

Level of Evidence: Morphometric analysis, Level III

ÖZET:

Amaç: Bu çalışmanın amacı asemptomatik erişkinlerde rekonstrüktif bilgisayarlı tomografi ile kraniovertebral bileşkenin değerlendirilmesidir.

Materyal ve Metod: Acil servise kraniovertebral bileşke patolojisi haricinde sebeplerle başvurmuş 98 hastanın rekonstrüktif bilgisayarlı tomografi görüntüleri retrospektif olarak incelenmiştir.

Sonuçlar: Çalışmaya 98 (46 kadın, % 46.9, ve 52 erkek, % 53.1) hasta dahil edildi. Ortalama yaş 51.7 ± 18.7 , ortalama Chamberline-Odontoid mesafesi 2.5 ± 1.2 mm, ortalama Grabb-Oakes mesafesi 6.8 ± 1.4 mm, ortalama Atlantodental mesafe 1.4 ± 0.5 mm, ortalama Foramen Magnum AP mesafesi 34.3 ± 3.2 mm ve ortalama Foramen Magnum koronal yan mesafesi 30.0 ± 2.7 mm olarak bulundu. Ölçümler kadın ve erkekler arasındaki fark karşılaştırıldığında sadece foramen magnum çapı istatistiksel olarak anlamlı bulundu (kadın 33.1 ± 2.6 , erkek 35.4 ± 3.4 mm, $p=0.011$). Yaş ($p=0.960$), Chamberline-Odontoid mesafesi ($p=0.952$), Grabb-Oakes mesafesi ($p=0.068$), Atlantodental aralık ($p=0.680$) ve Foramen Magnum yan koronal ($p=0.741$) erkek ve kadınlar arasında benzer olarak bulunmuştur.

Çıkarım: Kraniovertebral bileşke anomalilerini değerlendirirken, cerrahlar düz radyografiler yerine rekonstrüktif bilgisayarlı tomografi ölçümlerini tercih etmelidir.

Anahtar kelimeler: Kraniovertebral bileşke, rekonstrüktif bilgisayarlı tomografi, kraniovertebral bileşke morfometrisi.

Kanıt Düzeyi: Morfometrik analiz, Düzey III

INTRODUCTION:

The craniovertebral junction (CVJ) is the union of the occiput, atlas and axis. Morphological studies on the normal craniometry of the craniocervical junction can be helpful in improving the precision of such diagnosis criteria and improving the classification of CVJ anomalies^{8,9}.

Bone structures are superimposed on the plain radiographs so, for the evaluation of all CVJ anomalies and diseases we must use of modern diagnostic imaging methods such as CT scan with reconstruction or MRI¹⁰. CVJ could be well layed out with reconstructional 3-dimensional (3D) thin-layered computed tomography. This latter technique requires a large number of overlapping, thin-section axial images and an extremely cooperative patient. The craniometric parameters of the CVJ are of paramount importance to understand and propose adequate treatments for the different diseases that affect the region^{12,13}.

We performed a craniometrical evaluation of an asymptomatic population, with the purpose of gathering information on the normal reconstructional CT parameters of the CVJ in asymptomatic individuals.

MATERIALS AND METHODS:

We inspected 98 consecutive CVJ CT scans obtained in adult patients who were admitted to our hospital for emergency treatment of non-CVJ conditions retrospectively. Inclusion criterias for patients in the study are, patients had to be older than 17 years and have undergone a complete 3D-CT scan of the CVJ for causes other than an investigation of a CVJ malformation or congenital anomaly. Patients were excluded if their radiological examinations were not sufficient for the proposed measurements, if they had undergone only a dynamic CT scan that would preclude some of the measurements, if they were undergoing mechanical ventilation at the time of the CT scan, or if they were known to have pathological conditions of the CVJ.

MEASUREMENTS:

1) The distance from the tip of the odontoid to the Chamberlain line was determined as follows. A line was drawn from the posterior hard palate to the tip of the opisthion (the Chamberlain line) on a sagittal CT image (Figure-1). A perpendicular line was then traced through the tip of the odontoid, and the length of this line was recorded as well as whether the odontoid tip was above or below the Chamberlain line.

2) The amount of ventral cervicomedullary encroachment by the odontoid the measurement proposed by Grabb-Oakes measured in a sagittal

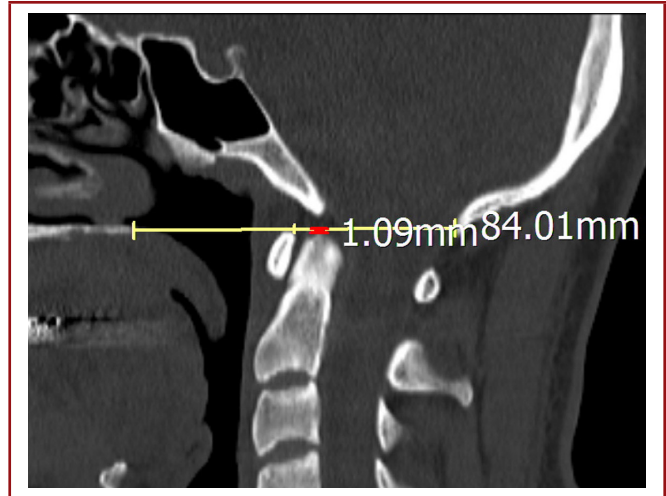


Figure-1. The distance from the tip of the odontoid to the Chamberlain line was determined as follows. A line was drawn from the posterior hard palate to the tip of the opisthion (the Chamberlain line) on a sagittal CT image.

CT image as the distance to a line traced from the most posterior region of the dura mater covering the dens to the line that goes from the inferior surface of the basion to the posterior inferior aspect of the C-2 vertebral body (Figure-2).

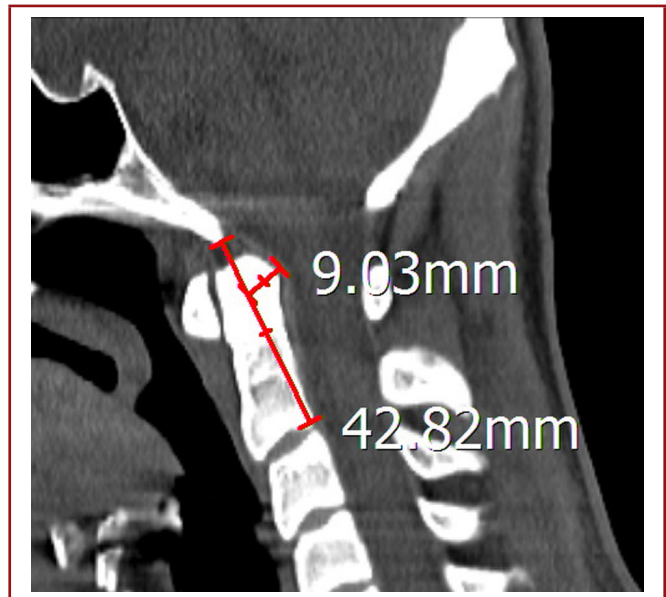


Figure-2. The amount of ventral cervicomedullary encroachment by the odontoid the measurement proposed by Grabb-Oakes measured in a sagittal CT image as the distance to a perpendicular line traced from the most posterior region of the dura mater covering the dens to the line that goes from the inferior surface of the basion to the posterior inferior aspect of the C-2 vertebral body.

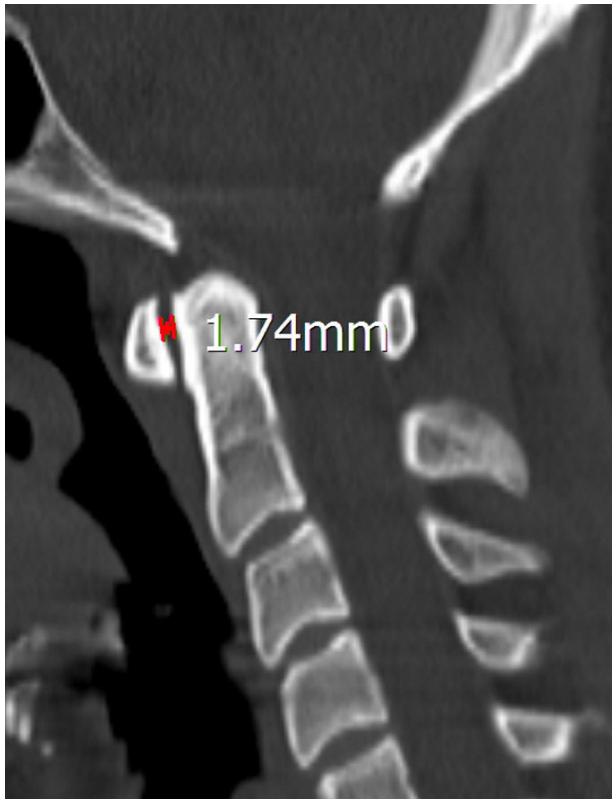


Figure-3. The atlantodental interval was measured as the distance between the posterior border of the anterior C-1 arch and the anterior margin of the odontoid process on a midline sagittal CT image.

3) The atlantodental interval was measured as the distance between the posterior border of the anterior C-1 arch and the anterior margin of the odontoid process on a midline sagittal CT image (Figure-3).

4) The anteroposterior and latero-lateral diameters of the foramen magnum were measured as the greatest distance between the anterior and posterior rims of the foramen magnum (Figure-4) and the greatest distance from its left lateral surface to its right lateral (Figure-5).

STATISTICAL ANALYSIS:

Descriptive data were presented as frequencies and percent for categorical variables, and as mean and standard deviation for numerical variables. Independent group comparisons between both genders were performed with Mann-Whitney U test. P values lower than 0.05 (Type I error level of 5%) was considered as statistically significant result. All analyses were performed by using IBM SPSS Statistics for Windows, Version 21.0 (Armonk, NY: IBM Corp.).

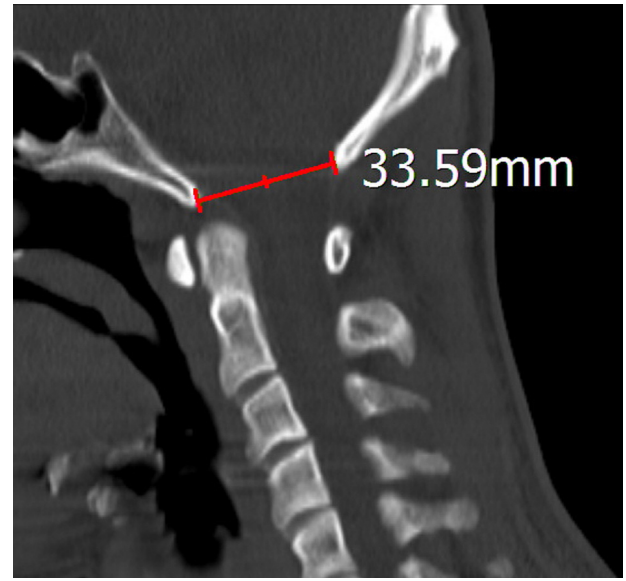

Figure-4. The anteroposterior and latero-lateral diameters of the foramen magnum were measured as the greatest distance between the anterior and posterior rims of the foramen magnum

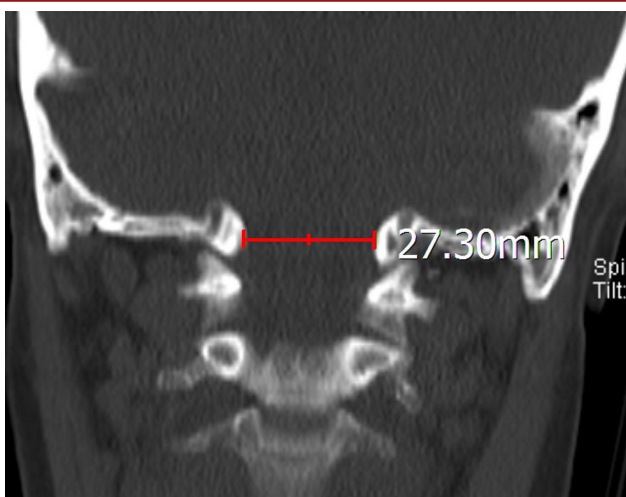


Figure-5. The greatest distance from its left lateral surface to its right lateral.

RESULTS:

98 patients (46 females, 46.9 %, and 52 males, 53.1 %) were included in the study. General characteristics of patients were presented in Table-1. Accordingly, mean age was 51.7 ± 18.7 years, mean Chamberline-Odontoid Distance was 2.5 ± 1.2 mm, mean Grabb-Oakes was 6.8 ± 1.4 mm, mean Atlantodental Interval was 1.4 ± 0.5 mm, mean Foramen Magnum AP was 34.3 ± 3.2 mm, and mean Foramen Magnum Lat-Lat Coronal was 30.0 ± 2.7 mm.

Table-1. General characteristics of patients

	n	%
Gender		
Female	46	46.9%
Male	52	53.1%
	Mean (mm)	SD (mm)
Age	51.7	18.7
Chamberline-Odontoid Distance	2.5	1.2
Grabb-Oakes	6.8	1.4
Atlantodental Interval	1.4	0.5
For. Magnum AP	34.3	3.2
For. Magnum Lat-Lar Coronal	30.0	2.7

When the measurements were compared between females and males, it was found that only foramen magnum ap distance was significantly different between genders (33.1 ± 2.6 mm in females, 35.4 ± 3.4 mm in males, $p=0.011$), and males had larger foramen magnum AP distance values. Age ($p=0.960$), Chamberline-Odontoid Distance ($p=0.952$), Grabb-Oakes ($p=0.068$), Atlantodental Interval ($p=0.680$), and

Foramen Magnum Lat-Lat Coronal ($p=0.741$) were similar between females and males. Comparisons between genders are presented in Table-2.

DISCUSSION:

Understanding and evaluation of CVJ relationships can be simplified by identification of relatively few anatomic landmarks, basic knowledge of the development of structures

constituting the CVJ (occiput, atlas, and axis), and application of some simple craniometric measurements^{3,5,6,7}.

Rojas et al. assessed normal anatomical relationships of the CVJ on CT scans obtained in 200 patients who underwent imaging as part of a trauma protocol and were found to have no osseous or soft tissue abnormality (11). The values differed significantly from the classic values based on standard plain radiographs. The authors reported that 95 % of their patients had an ADI less than 2 mm, smaller than the historical value of 3 mm previously reported in studies from the 1960s as the normal upper limit¹¹.

Batista et al. reported that the mean distance from the tip of the odontoid process to the line proposed by Chamberlain was -1.55 mm (below the line)^{1,2}. Of note, some patients had the tip of the odontoid 2 mm or even 5 mm above the Chamberlain line, both levels that have been proposed as diagnostic criteria for basilar invagination. Based on their findings they evaluated that due to anatomical variations, some asymptomatic individuals would have the diagnosis of basilar invagination. Based on a normal distribution, the normal accepted range of the distance of the tip of the odontoid process in their population was from 5.9 mm below to 2.9 mm above the Chamberlain line¹. Patients with the tip of the odontoid extending more than 2.9 mm past the Chamberlain line would be considered abnormal in their study population³. When analyzing the amount of ventral cervicomedullary encroachment by the odontoid, a measurement proposed by Grabb et al., the mean distance from the most posterior region of the dura mater covering the tip of the odontoid process to the line that goes from the inferior surface of the basion to the inferior aspect of the C-2 body was 6.7 mm, and only 1 asymptomatic patient had a value above 9 mm for this measurement⁴.

Table-2. Comparisons of measurements between genders

	Female		Male		P
	Mean (mm)	SD (mm)	Mean (mm)	SD (mm)	
Age	51.4	18.4	51.9	19.4	0.960
Chamberline-Odontoid Distance	2.5	0.9	2.5	1.5	0.952
Grabb-Oakes	6.5	1.4	7.2	1.4	0.068
Atlantodental Interval	1.4	0.4	1.5	0.6	0.680
For. Magnum AP	33.1	2.6	35.4	3.4	0.011
For. Magnum Lat-Lar Coronal	29.8	2.6	30.2	2.8	0.741

Our study is limited by the lack of intra- and inter-reliability assessment for the presented CVJ measurements. Further studies addressing the reliability of CT scan measurement of the normal CVJ craniometry are necessary. Additionally, CVJ craniometry may be influenced multifactors such as patient race height and among others. Our study did not address these issues, but they should be taken into account in future research in this field.

We reported our results on normal craniometrical values obtained from modern 3D reconstructions in 100 asymptomatic individuals. These studies can be useful for evaluating anomalies of the CVJ in comparison with normal parameters. We believe that the precise landmarks obtained with CT reconstructions should improve the reproducibility of CVJ craniometry compared with measurements obtained with simple plain radiographs. When evaluating CVJ malformations, surgeons should take into account the normal ranges based on CT scan instead of those obtained from plain radiographs.

REFERENCES:

1. Batista UC, Joaquim AF, Fernandes YB, Mathias RN, Ghizoni E, Tedeschi H. Computed tomography evaluation of the normal craniocervical junction craniometry in 100 asymptomatic patients. *Neurosurg Focus* 2015; 38(4): E5.
2. Chamberlain WE. Basilar impression (platybasia). A bizarre developmental anomaly of the occipital bone and upper cervical spine with striking and misleading neurologic manifestations. *Yale J Biol Med* 1939; 11: 487–496.
3. Chethan P, Prakash KG, Murlimanju BV, Prashanth KU, Prabhu LV, Saralaya VV. Morphological analysis and morphometry of the foramen magnum: an anatomical investigation. *Turk Neurosurg* 2012; 22: 416–419.
4. Grabb PA, Mapstone TB, Oakes WJ: Ventral brain stem compression in pediatric and young adult patients with Chiari I malformations. *Neurosurgery* 1999; 44: 520–528.
5. Harris J Jr. The cervicocranium: its radiographic assessment. *Radiology* 2001; 218: 337–351.
6. Harris JH Jr., Carson GC, Wagner LK. Radiologic diagnosis of traumatic occipitovertebral dissociation: 1. Normal occipitovertebral relationships on lateral radiographs of supine subjects. *AJR Am J Roentgenol* 1994; 162: 881–886.
7. Harris JH Jr, Carson GC, Wagner LK. Radiologic diagnosis of traumatic occipitovertebral dissociation: 2. Comparison of three methods of detecting occipitovertebral relationships on lateral radiographs of supine subjects. *AJR Am J Roentgenol* 1994; 162: 887–892.
8. Heiss JD, Suffredini G, Bakhtian KD, Sarntinoranont M, Oldfield EH. Normalization of hindbrain morphology after decompression of Chiari malformation Type I. *J Neurosurg* 2012; 117: 942–946.
9. Karagöz F, Izgi N, Kapıjcıoğlu Sencer S. Morphometric measurements of the cranium in patients with Chiari type I malformation and comparison with the normal population. *Acta Neurochir (Wien)* 2002; 144: 165–171.
10. Kwong Y, Rao N, Latief K. Craniometric measurements in the assessment of craniovertebral settling: are they still relevant in the age of cross-sectional imaging? *AJR Am J Roentgenol* 2011; 196: W421–W425.
11. Rojas CA, Bertozzi JC, Martinez CR, Whitlow J. Reassessment of the craniocervical junction: normal values on CT. *AJNR Am J Neuroradiol* 2007; 28: 1819–1823.
12. Smoker WR. Craniovertebral junction: normal anatomy, craniometry, and congenital anomalies. *Radiographics* 1994; 14: 255–277.
13. Yoshida G, Yasuda T, Togawa D, Hasegawa T, Yamato Y, Kobayashi S. Craniopelvic alignment in elderly asymptomatic individuals: analysis of 671 cranial centers of gravity. *Spine* 2014; 39: 1121–1127.

