



EXTENDED LUMBAR LAMINECTOMY: A SAFE AND SWIFT TECHNIQUE

UZATILMIŞ LOMBER LAMİNEKTOMİ: GÜVENLİ VE HIZLI BİR TEKNİK

Oktay GURCAN¹,
Ahmet Gurhan GURCAY¹,
Atilla KAZANCI¹,
Salim SENTURK²,
İsmail BOZKURT¹

¹ Ataturk Research and Training
Hospital, Department of Neurosurgery,
Ankara, Turkey

² Koc University Hospital, Department
of Neurosurgery, Istanbul, Turkey

SUMMARY:

Even though spinal surgeons are very familiar lumbar laminectomy, prolongation of surgical time increases the risk of complications. The shift towards minimally invasive and shorter operation time pushes surgeons in search of new methods. Thus arises the need for safer maneuvers and techniques. The goal of method employed within this paper is to expand the lumbar canal dorsally by removing the spinous processes, laminae, ligamentum flavum, and bony hypertrophy that are contributing to the canal stenosis. This technique is hasty in technical manners and also flexible. With proper diagnosis and selection of patients, careful appliance of this technique will allow for safe, swift and effective approach to the management of lumbar canal stenosis.

Key words: spinal canal stenosis, lumbar, decompression, surgical drill, laminectomy

Level of Evidence: Technical note, Level V

ÖZET:

Lomber laminektomi sırasında sürenin uzaması, spinal cerrah ne kadar tecrübeli olursa olsun komplikasyon riskini arttırmaktadır. Minimal invaziv ve daha kısa süren cerrahi tekniklere eğilimin artmasıyla beraber cerrahlar yeni yöntemler aramaktadır. Bu şekilde daha güvenli manevra ve tekniklere ihtiyaç doğmaktadır. Bu yazıda ele alınan tekniğin amacı lomber kanalı daraltan posterior elemanları daha geniş ve hızlı bir şekilde çıkartarak güvenli dekompresyon sağlamaktır. Teknik olarak hızlı ve kolaylıkla uygulanabilir bir yöntemdir. Lomber dar kanalın cerrahi tedavisi ele alınırken dikkatli tanı süreci ve hasta seçimiyle beraber bu teknik ile güvenli, hızlı ve etkin bir dekompresyon sağlanabilir.

Anahtar Kelimeler: Spinal dar kanal, lomber, dekompresyon, cerrahi, laminektomi

Kanıt Düzeyi: Teknik not, Düzey V

Address: Oktay GÜRCAN,
Ataturk Research and Training
Hospital, Department of
Neurosurgery, Üniversiteler
Mahallesi, Bilkent Caddesi, No:1,
Çankaya, ANKARA.

E-mail: oktaygurcan@gmail.com
Tel.: 0505 5017334

Received: 12th January, 2016.
Accepted: 14th February, 2016.

INTRODUCTION:

Lumbar laminectomy alone or combined with other procedures continues to be one of the most common technique employed during lumbar surgery. Laminectomy with or without foraminotomy is the common accepted treatment for decompression of the lumbar spondylosis. It is also frequently used for spinal malignancies, infection or traumatic lesions. Although performed frequently, incidental durotomy is not rare averaging around 10%². At least one complication has been reported in 7% of laminectomy cases based on 6376 lumbar operations³.

TECHNIQUE:

A shortened version of the technique has been attached to better visualize the steps. Within this technique after anesthetic preparations the patient is rolled over to prone position supported by silicone pillows bilaterally. A C-arm may be used to localize correct level. After an appropriate midline incision, subperiosteal dissection of paravertebral muscles is followed by splitting of interspinous ligaments using a surgical blade. A high speed drill with a ball end thin pars interarticularis bilaterally from lateral to the medial side. A Kerrison rongeur may be employed before the drill is used to assist the drill entrance point (Figure-1.a-b).

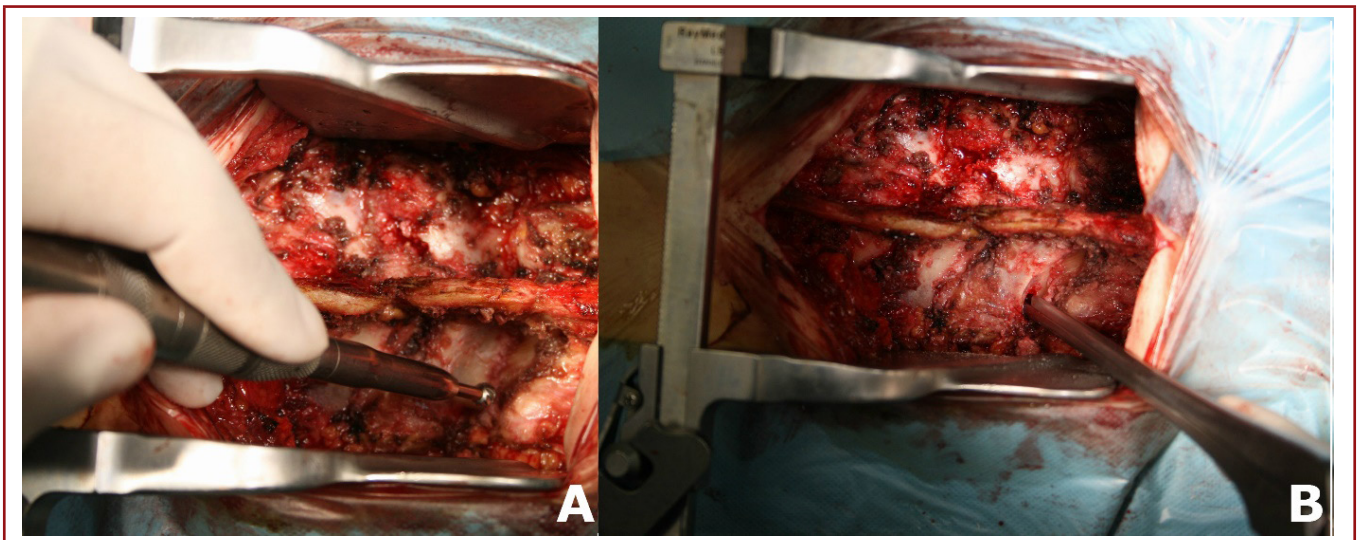


Figure-1. a) A ball ended drill thinning pars articularis. **b)** Kerrison rongeur used to create an entrance point for the footed drill.

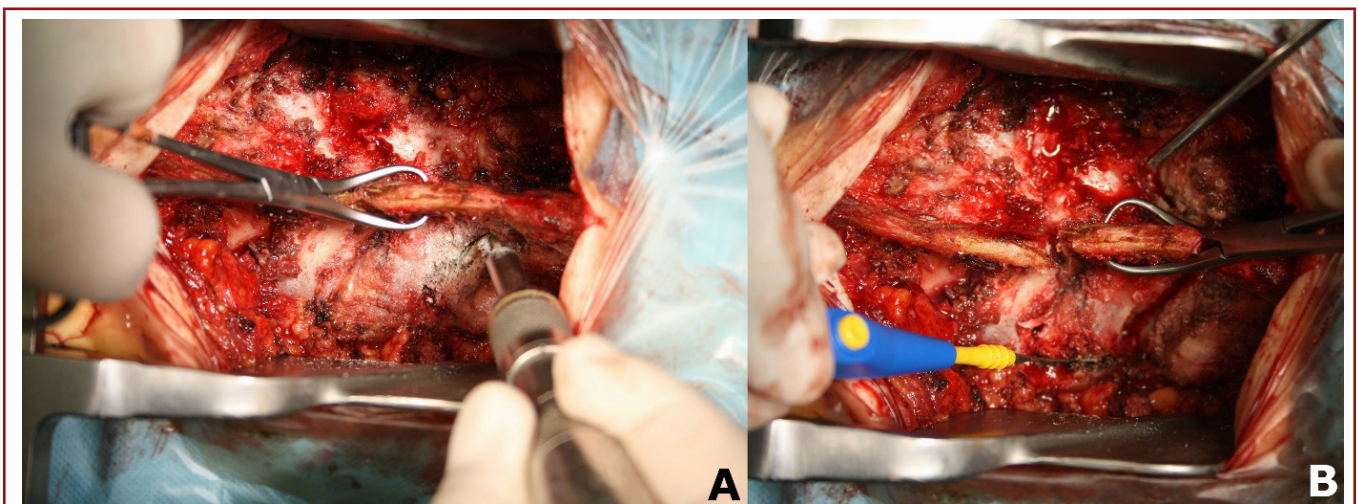


Figure-2. a) Footed end drill used to excise pars interarticularis. **b)** Monopolar cautery used to split facet joint.

After thinning pars interarticularis, a drill with a footed end is used at an approximate 45° angle to excise pars interarticularis allowing the connection between laminae, spinous process and inferior facet joints (posterior elements) to be separated from the vertebral corpus and pedicles.

The inferior facet the joint is then split using a monopolar cautery, then a backhaus clamp is used to elevate the posterior elements and a periosteal dissector is inserted in between ligamentum flavum and facet joints allowing an en bloc excision of the posterior elements (Figure-2,3).

A backhaus clamp should be employed throughout the procedure to allow better visualization of spaces by maneuvering the lamina. After excising lig. flavum, Kerrison rongeur is again used to remove the medial aspects of the superior articular facet joint of the inferior level until pedicle junction along with extended foraminotomy. This wide decompression of the lumbar vertebrae will create the need for posterior instrumentation due to instability. Posterior pedicle screws were used to allow bony fusion.

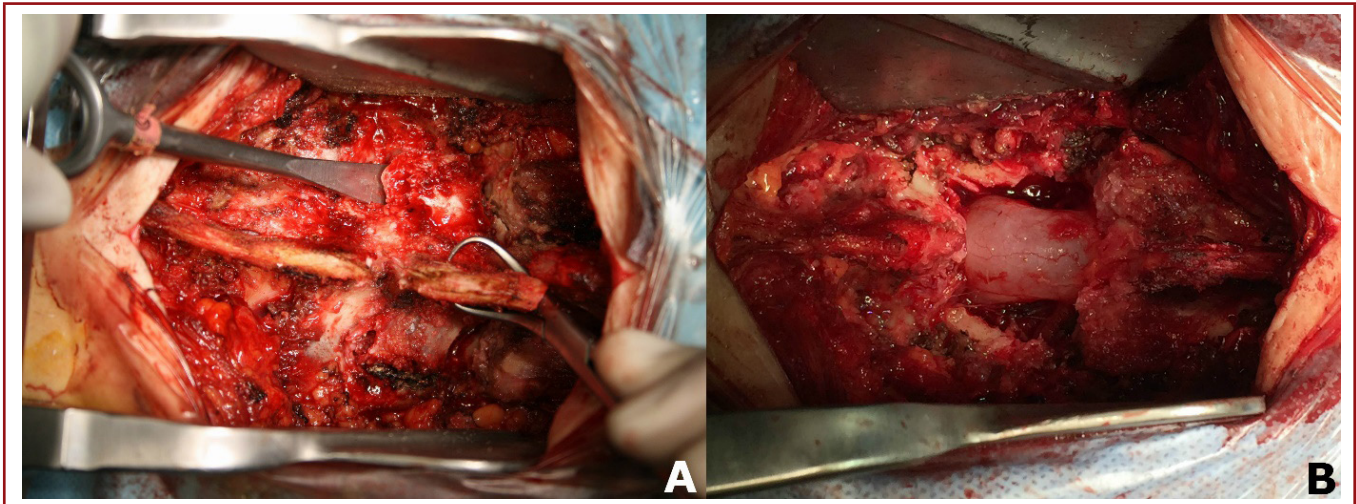


Figure-3. a) Periosteal dissector used to elevate posterior elements along with dissection from the cord. **b)** After the removal of the posterior elements of the spine.

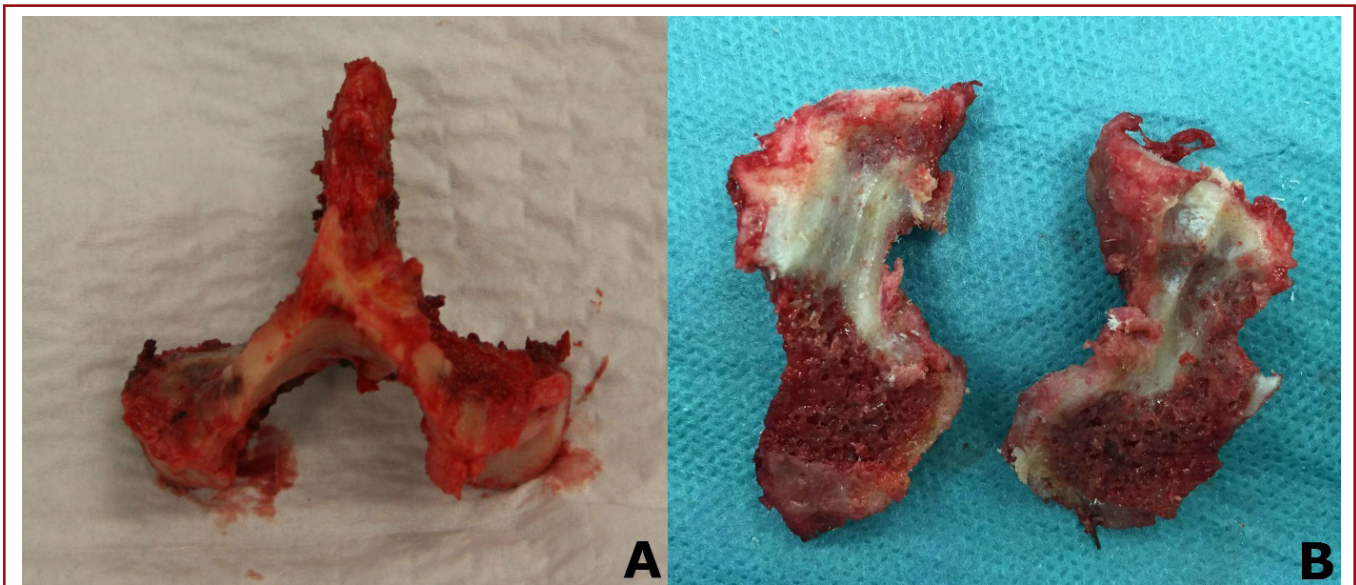


Figure-4. a) Excised bony elements, **b)** Split in half for better placement in bony fusion.

DISCUSSION:

A retrospective analysis of 17, 232 who underwent short-segment lumbar fusion revealed an incidental durotomy rate of 4.6 %¹. This correlated with increased neurological complications and longer hospital stay. A classical decompression using Kerrison and LeKessell rongeur would require multiple entrances to the epidural space and with every debulking maneuver the dura mater is at risk for laceration. Within this technique Kerrison rongeur is used to create an entrance point for the drill where dura is clearly visualized. Once the drill is inserted safely into the epidural space, the risk for damaging dura is minimized. Additionally, the classical method is debilitating and prolongs surgical period.

This extended lumbar laminectomy permits for a maximum neural decompression along with a safer and greater visualization allowing the surgeon for a safer transforaminal lumbar interbody fusion (TLIF) or posterior lumbar interbody fusion (PLIF) placement and pedicle subtraction osteotomy. En bloc excision of the posterior elements also creates a valuable cortical spongy auto graft to be used for posterolateral fusion (Figure-4).

CONCLUSION:

Although experimental research comparing classical methods and these techniques are required to state the technique mentioned here to be safer, clinical experience with this method so far has yielded no complications.

REFERENCES:

1. Buck JS, Yoon ST. The incidence of durotomy and its clinical and economic impact in primary, short-segment lumbar fusion: an analysis of 17, 232 cases. *Spine* 2015; 40(18): 1444-1450.
2. Bydon M, Macki M, Abt NB, Sciubba DM, Wolinsky JP, Witham TF, Gokaslan ZL, Bydon A. Clinical and surgical outcomes after lumbar laminectomy: An analysis of 500 patients. *Surg Neurol Int* 2015; 6(Suppl 4): 190-193.
3. Malter AD, McNeney B, Loeser JD, Deyo RA. 5-year reoperation rates after different types of lumbar spine surgery. *Spine* 1998; 23: 814-820.