



## IS OPEN REDUCTION AND ANTERIOR STABILIZATION EFFECTIVE AND SAFE FOR CERVICAL FRACTURES AND DISLOCATIONS? SINGLE INSTITUTION EXPERIENCE WITH 21 CASES

### SERVİKAL KIRIKLI ÇIKIKLARDA AÇIK REDÜKSİYON VE ANTERİOR STABİLİZASYON ETKİLİ VE GÜVENLİ MİDİR? 21 VAKALIK TEK MERKEZ DENEYİMİ

Ahmet Gurhan GURCAY<sup>1</sup>,  
Oktaç GURCAN<sup>1</sup>,

<sup>1</sup>Department of Neurosurgery, Ataturk  
Training and Research Hospital,  
Ankara, Turkey

#### SUMMARY:

**Objective:** To present our clinical outcomes with open reduction and stabilization method via anterior approach in patients with cervical fracture and dislocation.

**Methods:** This retrospective study was based on data derived from medical files of 21 patients surgically treated in the neurosurgery department of our institution between 2011 and 2015. Preoperative evaluation was made by means of American Spinal Injury Association (ASIA) and Subaxial Cervical Spine Injury Classification (SLIC) scores as well as radiological data obtained from computerized tomography (CT) and magnetic resonance (MR). Stabilization via anterior approach in supine position was performed routinely within 24 hours after admission. Postoperative controls carried out on 1<sup>st</sup>, 3<sup>rd</sup> and 6<sup>th</sup> months consisted of ASIA impairment scales and Bridwell grades extracted from radiological data.

**Results:** Vast majority of the fractures and dislocations were encountered at the levels of C5-6 (9/21; 42.8%) and C6-7 (8/21; 38.1%). Cervical spines were involved bilaterally in 12 (57.1%) patients. Mortality occurred in 3 cases (14.3%) due to acute respiratory distress syndrome and multiple organ failure within 1 month postoperatively. ASIA impairment scales on 1<sup>st</sup> and 6<sup>th</sup> months revealed a gradual recovery, while no difference was observed in terms of Bridwell grades on 3<sup>rd</sup> and 6<sup>th</sup> months. Majority of our cases (18/21; 85.7%) were devoid of any remarkable neurological deficits and they were discharged without any complications within 1 week postoperatively.

**Conclusion:** Our results indicate that open reduction and stabilization via anterior approach may be safe and effective operative technique in the management of cervical fractures and dislocations.

**Key words:** Cervical; dislocation; fracture; open reduction; stabilization; anterior approach.

**Level of Evidence:** Retrospective clinical study, Level III

#### ÖZET:

**Amaç:** Servikal kırıklı çıkıklarda anterior yaklaşımla açık redüksiyon ve stabilizasyon metodu uygulanan hastalardaki klinik sonuçlarımızı sunmayı amaçladık.

**Yöntem ve Gereç:** Bu retrospektif çalışmada 2011 ile 2015 yılları arasında hastanemiz beyin cerrahisi kliniğinde ameliyat edilen 21 servikal kırıklı-çıkık tanısı ile yatırılan hastanın tıbbi dosya ve bilgileri kullanılmıştır. Preoperatif değerlendirme American Spinal Injury Association (ASIA) ve Subaxial Cervical Spine Injury Classification (SLIC) skorları ve bilgisayarlı tomografi (BT) ve magnetik rezonans görüntüleme (MRG) kullanılarak yapılmıştır. Başvuru sonrası 24 saat içinde supin pozisyonda anterior stabilizasyon rutin olarak yapılmıştır. Postoperatif dönemde birinci, üçüncü ve altıncı aylarda ASIA düşüş skalsı ve radyolojik verilerden elde edilen Bridwell dereceleri ile hastaların kontrolleri yapıldı.

**Sonuçlar:** Kırıklı çıkıkların büyük çoğunluğu C5-6 (9/21; 42.8%) ve C6-7 (8/21; 38.1%) seviyelerinde gözlenmiştir. Servikal vertebra 12 (57.1%) hastada bilateral etkilenmiştir. 3 vakada (14.3%) postoperatif bir aylık sürede akut respiratuar distress sendromu ve çoklu organ yetmezliğine bağlı mortalite gelişmiştir. Ameliyat sonrası birinci ve altıncı aylarda ASIA skorlarında kademeli bir düzelme gözlenirken Birinci ve altıncı aylarda Bridwell derecelerinde bir farklılık gözlenmemiştir. Vakalarımızın çoğunda (18/21; 85.7%) belirgin bir nörolojik defisitleri yoktu ve ameliyat sonrası dönemde komplikasyonsuz olarak bir hafta içinde taburcu edilmiştir.

**Yorum:** Servikal kırıklı çıkıklı vakalarda anterior girişim ile açık redüksiyon ve stabilizasyon cerrahi tekniğinin güvenli ve etkili bir yöntem olduğu sonucuna varılmıştır.

**Anahtar Kelimeler:** Servikal omurga; çıkık; kırık; açık redüksiyon; stabilizasyon; anterior yaklaşım.

**Kanıt Düzeyi:** Retrospektif klinik çalışma, Level III

**Address:** Ahmet Gurhan Gurcay, MD.  
Department of Neurosurgery, Ataturk  
Training and Research Hospital,  
Ankara, Turkey  
**E-mail:** drgurcay@gmail.com  
**Tel:** +90532 7082626  
**Fax:** +90312 2912525  
**Received:** 11th January, 2016  
**Accepted:** 24th February, 2016.

## INTRODUCTION:

Cervical dislocation and fracture is common and may occur secondary to distraction-flexion type of injuries in the subaxial cervical spine<sup>4,13</sup>. Unilateral facet injuries can result in increased range of motion and remarkable soft tissue damage including facet capsules, ligamentum flavum, annulus fibrosus and nucleus pulposus. The surgical treatment of cervical facet dislocations is highly variable including anterior alone, posterior alone, anterior-posterior, posterior-anterior, and anterior-posterior-anterior approaches<sup>4,13</sup>. Some authors support that the anterior only approach including closed or open reduction, discectomy and instrumental fusion is recommended, especially in case of a traumatic intervertebral disc herniation and without spinal cord injury<sup>7,9</sup>. However, it must be remembered that achievement of satisfactory reduction can be unfeasible in some cases with bilateral locked facets. Clinical and biomechanical evidence supports the use of anterior cervical discectomy and fusion with plating (ACDFP) for effective stabilization<sup>13</sup>. On the other hand, some publications suggest that ACDFP was less stable than some posterior approaches, especially in axial rotation<sup>3</sup>.

In some cases with bilateral facet dislocation, anterior instrumental fusion followed by posterior fusion was recommended as a treatment modality. There is a debate for the ideal approach and treatment modality in the management of cervical fracture and dislocation. Open reduction and stabilization through anterior approach can eliminate the need for additional posterior supplementation. Moreover, patients may suffer from a high incidence of complications related to trauma, underlying disease process and management of the fracture regardless of the cause. Common complications consist of challenges associated with surgical stabilization and neurological deficits<sup>14</sup>.

The objective of the current study was to present our clinical outcomes with open reduction and stabilization method via anterior approach in patients with cervical fracture and dislocation.

## PATIENTS AND METHODS:

### Study design:

This retrospective study was carried out on data derived from the medical files of 21 patients treated surgically in the neurosurgery department of our tertiary care center between 2011 and 2015. The approval of the local Institutional Review Board had been obtained prior to the study. Diagnosis of cervical fracture or dislocation was confirmed with radiological imaging modalities such as computerized tomography and magnetic resonance imaging. Surgical treatment was performed within 24 hours after admission. Preoperative neurological examination was comprised of American Spinal

Injury Association (ASIA) and Subaxial Cervical Spine Injury Classification (SLIC) scores<sup>11,12</sup>. Postoperative assessment included ASIA impairment scales as well as Bridwell grades<sup>10</sup>.

### Surgical procedure:

All patients were operated uniformly in supine position via anterior approach. Anatomical alignment was restored and stabilization was accomplished in a single surgical session. Intraoperative neuromonitorization (IONM) was routinely used after 2013 except for patients with ASIA impairment scales of A and B.

Surgical intervention was initiated with a right paramedian transverse skin incision followed by blunt dissection. Esophagus and trachea were retracted medially, whereas sternocleidomastoid muscle and carotid sheath were drawn laterally. Bipolar cauterization was used to dissect longus colli muscles.

For bilateral locked facets, Caspar self-drilling distraction pins of 14 mm (*Aesculap surgical instruments Systems, PA, USA*) were placed in the midline of the upper and lower vertebra body. Subsequent to a slight distraction after this procedure, macroscopic discectomy was performed. After emptying the disc space, convex side of sedillot periosteal elevator (*Aesculap surgical instruments Systems, PA, USA*) was placed to the lower half of vertebral corpus. The concave part of elevator was used to compress the lower part of upper vertebra and convex part of the elevator was used for elevating the lower vertebra body. Simultaneous distraction of Caspar distractor provided achievement of normal configuration by restoration of the alignment of the facets.

For unilateral locked facets, unlocking was achieved with distraction and controlled rotation. Caspar self-drilling distraction pins were placed in the midline of the upper vertebra body and lower vertebra body pin was placed towards the locked side of facet with a angle of 35°-40°. After macroscopic discectomy sedillot periosteal elevator was used for compressing the upper vertebra body and for elevating lower vertebra. For unlocking unilateral locked facets distraction and controlled rotation was performed. Microscopic discectomy was followed by placement of PEEK (Polyetheretherketone) cage filled with 1 cc of allograft demineralized bone matrix (DBM) putty. Stabilization was provided by fixation using anterior cervical plate and screws. Layers were sutured and drain was maintained for 1 day after the operation. Gardner or Crushfield traction was not required in any of our patients. Use of Philadelphia cervical collar was recommended for 6 weeks and no infection was observed in any patients postoperatively.

### Sample Case-1:

A 84-year-old male patient was referred to our clinic with a complaint of quadriplegia. In the history it was mentioned

that the patient fell from height and admitted to another hospital. Radiological examination revealed C5-6 dislocation with bilateral locked facet joints and pulmonary contusion with multi-rib fractures (Figure-1a, 1b). The patient's ASIA score was ASIA-A, SLIC score was 7. He was operated on 20<sup>th</sup> hour after trauma via anterior approach. Normal configuration by restoration of the alignment of the facets was achieved as described above (Figure-1c, 1d). In the intensive care unit the patient died because of multi organ failure.

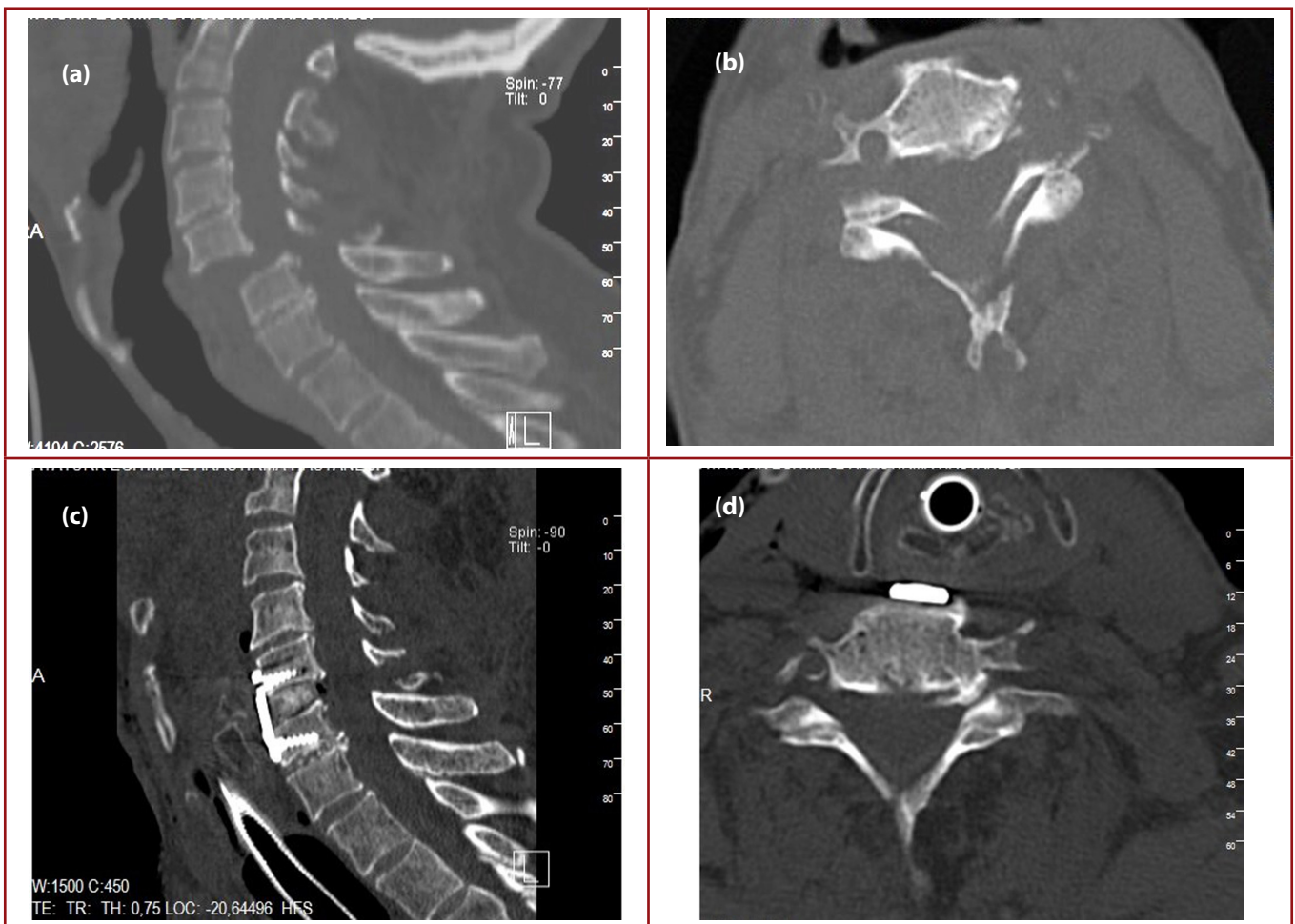
### Sample Case-2:

A 65-year-old male patient admitted to our emergency clinic with a complaint of severe neck pain after fall from height without any neurological deficit. Radiological examination revealed C5-6 dislocation with left locked facet joint (Figure 2a, 2b). The patient's ASIA score was ASIA-E, SLIC score was 5. He was operated on 12<sup>th</sup> hour after trauma via anterior

approach. After unlocking unilateral locked facet with the help of Caspar self-drilling distraction pins and sedillot periosteal elevator normal alignment of the cervical spine was achieved (Figure 2c, 2d).

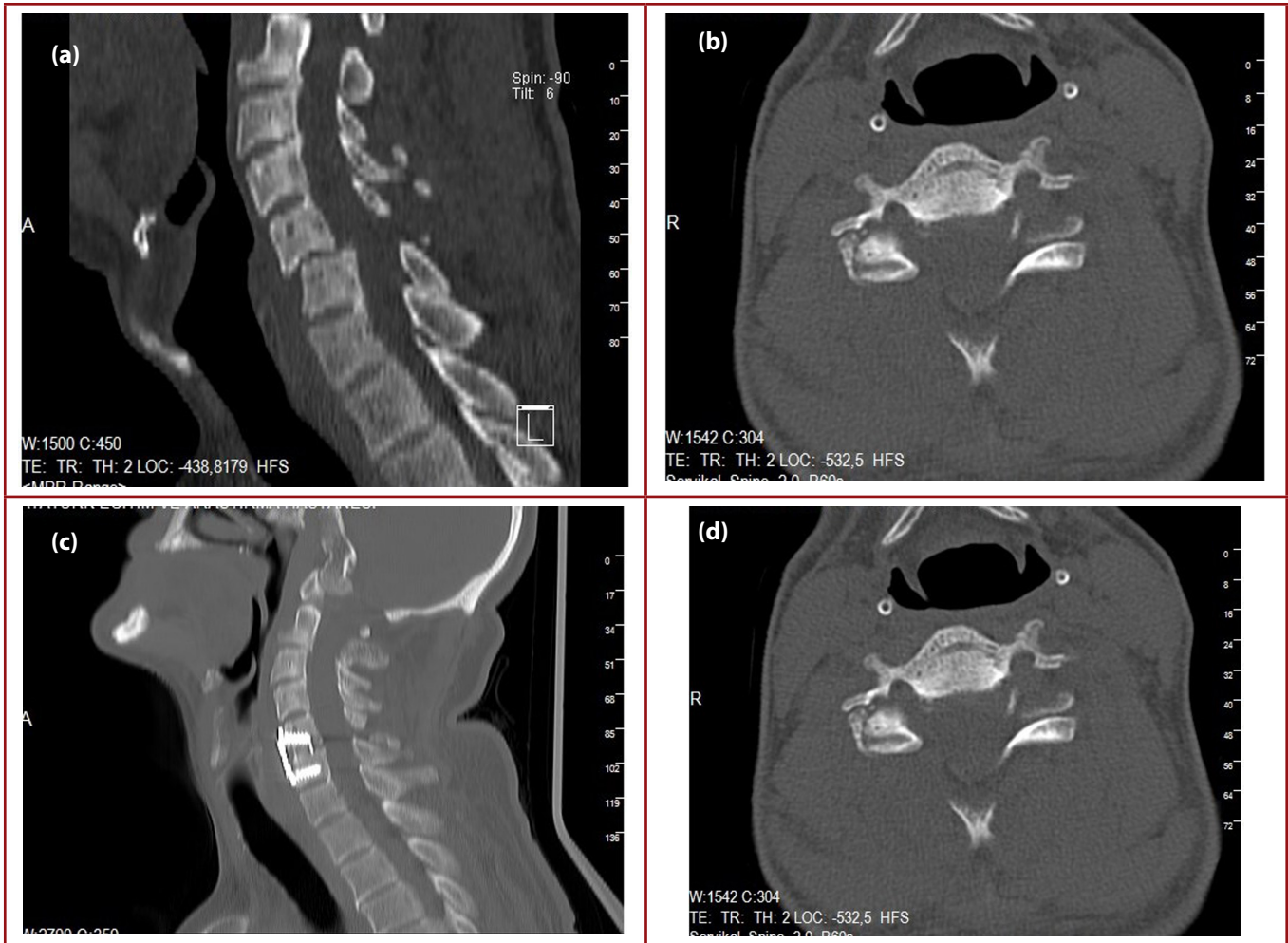
### RESULTS:

An overview of descriptive, clinical and radiological data is demonstrated in **Table 1**. The average age of patients was  $46.24 \pm 15.55$  (range: 19-84). Fifteen cases (71.4%) occurred due to a traffic accident, while 6 patients (28.6%) had cervical fracture / dislocation due to fall from height. Levels of the lesions were at C5-C6 (9, 42.9%); C6-C7 (8, 38.1%); C4-C5 (3, 14.3%) and C3-C4 (1, 4.7%). The mean preoperative SLIC score was  $6.28 \pm 1.42$  (range: 5-9) and bilateral involvement was diagnosed in 12 cases (57.1%). The vast majority of the fractures and dislocations were encountered at the levels of C5-6 (9/21; 2.8%) and C6-7 (8/21; 38.1%).



**Figure-1. a)** Sagittal Computed Tomography scan showing C5-6 dislocation. **b)** Axial Computed Tomography scan showing bilateral locked facet joints at C5-6 level. **c)** Postoperative sagittal Computed Tomography scan. **d)** Computed Tomography scan showing normal facet joint configuration at C5-6 level.





**Figure-2.** a) Sagittal Computed Tomography scan showing C5-6 dislocation. b) Axial Computed Tomography scan showing left locked facet joint at C5-6 level. c) Post operative sagittal Computed Tomography scan. d) Computed Tomography scan showing normal facet joint configuration at C5-6 level.

Facet locks in the cervical spines were bilateral in 12 (57.1%) patients and IONM was performed in 11 cases (52.4%). Number of patients with preoperative ASIA impairment scales of A, B, D and E were 3 (14.3%), 3 (14.3%), 3 (14.3%) and 12 (57.1%), respectively. The average duration of hospitalization was  $12.67 \pm 2.37$  days (range: 4-38).

Mortality occurred in 3 cases (14.3%) due to acute respiratory distress syndrome and multiple organ failure within 1 month postoperatively. ASIA impairment scales on 1<sup>st</sup> and 6<sup>th</sup> months revealed a gradual recovery, while no difference was observed between Bridwell grades on 3<sup>rd</sup> and 6<sup>th</sup> months. Approximately  $\frac{3}{4}$  of our cases had minor or no neurological deficits and they were discharged without any complications within 1 week postoperatively.

## DISCUSSION:

The current study presents our experience with open reduction with stabilization through anterior approach for

cervical fracture and dislocations. Results of the present study demonstrated that both unilateral and bilateral facet locks due to dislocation or fracture can be effectively treated by this method. Intraoperative neuronal monitorization can be a useful adjunctive measure that facilitates the procedure.

Monitorization of the clinical improvement and radiological recovery can be made reliably by ASIA impairment scales and Bridwell grades.

Fractures and dislocations of the spine are among the most challenging entities in the clinical practice of trauma. Vertebral column injuries can occur in these patients and approximately half of these cases have either co-existent spinal cord injuries or neurological deficits of nerve roots<sup>1</sup>. The main causes of traumatic spinal cord injury are motor vehicle-related accidents, violence, falls and sports injuries<sup>8</sup>.

In our series, traffic accidents and falls were reported in the etiology of cervical dislocations or fractures.

**Table-1.** An overview of descriptive, clinical and radiological variables of our series.

No.	Sex	Age	Type of trauma	Level of lesion	SLICpreop.	Facet lock	ASIA preop.	IONM	Duration of hospitalization	ASIA 1 <sup>st</sup> month	Bridwell grade 3 <sup>rd</sup> month	Bridwell grade 6 <sup>th</sup> month	ASIA 6 <sup>th</sup> month
1	M	43	TA	C6-C7	7	Bilateral	A	-	34	B	II	I	B
2	M	67	TA	C6-C7	8	Bilateral	B	-	33	N/A	N/A	N/A	N/A
3	M	38	TA	C5-C6	6	Unilateral	E	-	4	E	I	I	E
4	F	57	Fall	C4-C5	5	Unilateral	E	-	5	E	II	I	E
5	M	30	TA	C5-C6	5	Bilateral	E	-	7	E	II	I	E
6	F	49	TA	C6-C7	8	Bilateral	B	-	10	C	I	I	C
7	M	51	TA	C5-C6	6	Bilateral	D	-	6	E	II	II	E
8	M	26	TA	C6-C7	5	Bilateral	E	+	8	E	II	I	E
9	M	50	TA	C6-C7	5	Bilateral	E	+	5	E	I	I	E
10	M	38	TA	C5-C6	6	Unilateral	E	+	4	E	I	I	E
11	F	47	Fall	C6-C7	6	Unilateral	E	+	9	E	II	II	E
12	F	26	TA	C3-C4	5	Bilateral	E	+	4	E	I	I	E
13	M	63	Fall	C5-C6	5	Unilateral	E	+	5	E	II	II	E
14	F	46	TA	C6-C7	8	Bilateral	D	+	6	D	II	II	E
15	M	53	TA	C5-C6	5	Unilateral	E	+	7	E	II	II	E
16	M	84	Fall	C5-C6	7	Bilateral	A	-	38	N/A	N/A	N/A	N/A
17	M	65	Fall	C5-C6	5	Unilateral	E	+	4	E	II	II	E
18	M	19	TA	C4-C5	7	Unilateral	D	+	7	D	II	I	D
19	F	40	TA	C6-C7	5	Bilateral	E	+	5	E	I	I	E
20	M	35	Fall	C4-C5	9	Unilateral	A	-	32	N/A	N/A	N/A	N/A
21	M	44	TA	C5-C6	9	Bilateral	B	-	33	B	II	I	B

(**Hint:** M: male; F: female; TA: traffic accident; Fall: fall from height; N/A: not applicable due to mortality; SLIC: Subaxial Cervical Spine Injury Classification; ASIA: American Spinal Injury Association; preop: preoperative; IONM: Intraoperative neuromonitorization;)

Lack of other causes such as violence and sports trauma may be due to defects may ensorce from lacking or false information gathered from the patient.

Cervical region is the most common site of spinal cord injury and almost half of these lesions are linked with a neurological deficit<sup>2</sup>.

The cervical region of the spine is comprised of 7 vertebrae and the lower cervical spine includes the third to the seventh vertebrae (C3 to C7). Relative movement of the vertebrae occurs primarily via the facet joints and intervertebral discs lie between the cylindrical parts of adjacent vertebrae. These discs act both as shock absorbers and allow movement. Allen et al. have classified subaxial cervical spine injuries into 6 categories including compression-flexion, vertical compression, distraction-flexion, compression-extension, distraction-extension and lateral flexion. Facet dislocations and fractures may exist due to distraction-flexion injuries and make up 10% of all subaxial cervical spine fractures. They may occur unilaterally or bilaterally<sup>2</sup>. Management of dislocations or fractures of cervical vertebra include controversial aspects.

Reduction and internal fixation can be accomplished through anterior or posterior approaches. Selection of the mode of reduction as well as determination of the route of intervention such as anterior or posterior are crucial to achieve successful therapeutic outcomes<sup>6</sup>. The choice of surgical approach for the management of subaxial cervical spine facet dislocations and fractures is a debateful issue in spinal surgery. The causes of this controversy comprise the differences in the technical facilities and familiarity as well as the experience of surgeons with various surgical modalities. Moreover, differences in interpretation of the imaging studies for the extent of injury and the neurological status of the patient contribute to this variability. Therefore, attributed to the differences in surgical approaches, important variations may exist in terms of neurological, radiographical and clinical outcomes<sup>2</sup>.

Even though cervical dislocations have been stabilized posteriorly; there is currently a trend for anterior surgery. This may be related with the concern regarding the potential for any disc herniation to lead to compression of spinal cord<sup>2,5</sup>. The anterior approach is initiated with decompression and discectomy at the level of the spine affected by the injury. This

intervention is followed by the reduction maneuver that may be carried out using Caspar vertebral pins<sup>2</sup>.

Recent data indicated that there was little difference in long-term neurological status, pain or patient-reported quality of life between anterior and posterior surgical approaches to the management of individuals with subaxial cervical spine facet dislocations. Sagittal alignment can be accomplished via the anterior approach. There was insufficient evidence available to demonstrate differences between groups with respect to medical adverse events, rates of instrumentation failure and infection. Disorders related with voice and swallowing that were encountered in the anterior approach group resolved by three months. Thus, superiority of one approach over the other could not be confirmed and further higher quality multicentre randomized trials are warranted<sup>2</sup>.

Our results imply that fractures and dislocations of cervical vertebra were encountered at the levels of C5-6 and C6-7. Mortality occurred within 1 month postoperatively and the causes underlying demise were acute respiratory distress syndrome and multiple organ failure. ASIA impairment scales reflected the insidious recovery on 1<sup>st</sup> and 6<sup>th</sup> months. On the other hand, radiological improvement was not remarkably noted in terms of Bridwell grades. Vast majority of our series displayed healing without any significant neurological deficits and complications within 1 week postoperatively.

Immediate reduction, realignment of the cervical spine and relief of pressure on the spinal cord are main goals in the treatment of cervical fracture and dislocations. Achievement of reduction must be followed by the most appropriate method of stabilization. Further trials must be performed to establish the main principles of treatment algorithm in the lesions of cervical spine.

Main restrictions of the present study include retrospective design, relatively small sample size and lack of a control group. Moreover, this data reflects the experience of a single institution. Lack of a powered statistical analysis and absence of evaluation of correlation constitute significant limitations. Results of the present study demonstrated that open reduction and stabilization via anterior approach is safe and effective in the management of cervical fractures and dislocations with locked facets. Further prospective, randomized, multicentric, controlled trials on larger series are deemed necessary to establish the algorithm for management of cervical fracture and dislocations in spinal surgery.

### Acknowledgements

Conflicts of interest: None.

No financial support was received for this paper.

### REFERENCES:

1. Burney RE, Maio RF, Maynard F, Karunas R. Incidence, characteristics, and outcome of spinal cord injury at trauma centers in North America. *Arch Surg* 1993; 128: 596-599.
2. Del Curto D, Tamaoki MJ, Martins DE, Puertas EB, Bellotti JC. Surgical approaches for cervical spine facet dislocations in adults. *Cochrane Database Syst Rev* 2014; 10: CD008129.
3. Duggal N, Chamberlain RH, Park SC, Sonntag VK, Dickman CA, Crawford NR. Unilateral cervical facet dislocation: biomechanics of fixation. *Spine* 2005; 30: E164-168.
4. Dvorak MF, Fisher CG, Fehlings MG, Rampersaud YR, Oner FC, Aarabi B, Vaccaro AR. The surgical approach to subaxial cervical spine injuries: an evidence-based algorithm based on the SLIC classification system. *Spine* 2007; 32: 2620-2629.
5. Harrop JS, Sharan AD, Vaccaro AR, Przybylski GJ. The cause of neurologic deterioration after acute cervical spinal cord injury. *Spine* 2001; 26: 340-346.
6. Kahn A, Leggon R, Lindsey RW. Cervical facet dislocation: management following delayed diagnosis. *Orthopedics* 1998; 21: 1089-1091.
7. Lambiris E, Zouboulis P, Tyllianakis M, Panagiotopoulos E. Anterior surgery for unstable lower cervical spine injuries. *Clin Orthop Rel Res* 2003; 411: 61-69.
8. Nobunaga AI, Go BK, Karunas RB. Recent demographic and injury trends in people served by the model spinal cord injury care systems. *Arch Phys Med Rehabil* 1999; 80: 1372-1382.
9. Ordonez BJ, Benzel EC, Naderi S, Weller SJ. Cervical facet dislocation: techniques for ventral reduction and stabilization. *J Neurosurg* 2000; 92(1 Suppl): 18-23.
10. Tan GH, Goss BG, Thorpe PJ, Williams RP. CT-based classification of long spinal allograft fusion. *Eur Spine J* 2007; 16: 1875-1881.
11. Vaccaro AR, Hulbert RJ, Patel AA, Fisher C, Dvorak M, Lehman RA Jr; Spine Trauma Study Group. The subaxial cervical spine injury classification system: a novel approach to recognize the importance of morphology, neurology, and integrity of the disco-ligamentous complex. *Spine* 2007; 32: 2365-2374.
12. Waters RL, Adkins RH, Yakura JS. Definition of complete spinal cord injury. *Paraplegia* 1991; 9: 573-581.

- 
13. Yao R, McLachlin SD, Rasoulinejad P, Gurr KR, Siddiqi F, Dunning CE, Bailey CS. Influence of graft size on spinal instability with anterior cervical plate fixation following in vitro flexion-distraction injuries. *Spine J* 2015; Pii: S1529-9430(15)01230-9. doi:10.1016/j.spinee.2015.08.020.
  14. Zhang Z, Mu Z, Zheng W. Anterior pedicle screw and plate fixation for cervical facet dislocation: case series and technical note. *Spine J* 2015; pii: S1529-9430(15)01450-3. doi: 10.1016/j.spinee.2015.09.040.

