



RELATION BETWEEN CERVICAL SAGITTAL ALIGNMENT AND SURGICAL OUTCOME FOR LAMINECTOMY AND POSTERIOR FUSION OPERATIONS

LAMİNEKTOMİ VE POSTERİOR FÜZYON OPERASYONLARININ SONUÇLARI İLE SERVİKAL SAGİTAL DİZİLİM İLİŞKİSİ

Serkan ŞİMŞEK¹,
Uygur ER²,
Kazım YİĞİTKANLI³

¹MD, PhD, Assoc. Prof. of Neurosurgery, Private Lokman Hekim Hospital, Sincan, Ankara.

²MD, Prof. of Neurosurgery, Duzce University, School of Medicine, Duzce.

³MD, Assoc. Prof. of Neurosurgery, Polatlı State Hospital, Polatlı, Ankara.

SUMMARY

Cervical sagittal balance and alignment have received increased awareness as important factors of radiological and clinical outcomes. The goal of this study is to evaluate preoperative and postoperative alterations in cervical sagittal plane situations and correlation between these changings and surgical outcome in patients undergo laminectomy and fusion for some cervical pathologies. In this retrospectively designed study 44 men and 6 women with some degree cervical stenosis at various cervical levels were included. The mean value of the preoperative and postoperative mJOA scores of the patients were 7.76 and 12.96 respectively. Cervical lordosis angle (CLA) changing was statistically significant after operations. But, C₂₋₇SVA changing was not statistically significant. The contribution of cervical sagittal balance and alignment should be considered in evaluating surgical outcomes for patients undergoing cervical posterior decompression and instrumented fusion.

Key words: Laminectomy and fusion, cervical sagittal parameters, surgical outcome

Level of evidence: Retrospective clinical study, Level III.

ÖZET

Servikal sagittal denge ve dizilim radyolojik ve klinik sonuçlarda oynadığı rol ile son zamanlarda dikkat çekmektedir. Bu çalışmanın amacı bazı servikal patolojiler nedeniyle laminektomi ve enstrümanlı füzyon yapılan hastalarda servikal sagittal denge değişimlerini ve bunun sonuçlara etkisini araştırmaktır. Retrospektif olarak düzenlenmiş bu çalışmada çeşitli derece ve seviyelerde kanal darlığı olan 44 erkek ve 6 kadın hasta yer almışlardır. Ameliyat öncesi ve sonrası mJOA derecesi ortalama değerleri sırasıyla 7.76 ve 12.96'dur. Servikal lordoz açısı (CLA) değişimi istatistiksel olarak anlamlı olmakla beraber C2-7SVA değişimi istatistiksel olarak anlamlı değildir. Servikal sagittal denge ve dizilim posterior dekompresyon ve enstrümanlı füzyon yapılması planlanan hastalarda cerrahi sonuçlar değerlendirilirken mutlaka göz önüne alınmalıdır.

Anahtar kelimeler: Laminektomi ve füzyon, Servikal sagittal parametreler, Cerrahi sonuç

Kanıt düzeyi: Retrospektif klinik çalışma, Düzey III.

Running title: Cervical alignment and outcome

Address: Prof. Dr. Uygur ER,
Duzce University, School of Medicine,
Duzce, Turkey.

Tel: 0090 505 589 23 55

E-mail: uygurer@gmail.com

Received: 9th October, 2016.

Accepted: 17th November, 2016.

INTRODUCTION

To our experience, existing kyphotic cervical deformity or even loss of some degree cervical lordosis may effect on surgical outcomes after posterior cervical approaches for various cervical spine pathologies. Cervical sagittal balance (SB) has received increased awareness as an important factor of radiological and clinical outcomes. Some authors claimed that cervical laminectomy (CL) in patients with ossified posterior longitudinal ligament (OPLL) can cause neurological deterioration due to gained kyphotic deformity⁽⁵⁾. Conversely, some investigators wrote that postlaminectomy cervical kyphosis was not correlated with clinical outcome although progressive cervical kyphosis has been associated with myelopathy⁽³⁾. Besides this controversy, there is another perplexing state in the literature. The question of which sagittal plane parameters should be measured to the best evaluation has not been clarified yet. The literature is overcrowded of sagittal plane measurement methods; and everyday new ones are suggested⁽¹⁾.

The aim of this study is to assess preoperative and postoperative changings in cervical sagittal plane situations and correlation between these changings and surgical outcome in patients undergo laminectomy and fusion for some cervical pathologies.

Two simple and classic methods were used for measurement of cervical sagittal alignment.

That why were these parameters chosen is explained in the next sections.

PATIENTS AND MEASUREMENTS

This retrospectively designed study was conducted in two centers, the neurosurgery clinics of the private Sincan Lokman Hekim Hospital and Düzce University Medical center in between 2014 November and 2016 December.

Patient population is consisted of 44 men and 6 women with some degree cervical stenosis at various cervical levels. Age of patients was between 50 and 84 with a mean of 69.44 years.

Including criteria:

Men or women aged between 45 and 85 year-old underwent a CL and instrumented fusion operation for cervical stenosis diagnosed by clinically and confirmed by an MRI were included in this study.

Excluding criteria:

Patient with severe metabolic diseases, severe diabetes mellitus, cardiac failure, hypertension, hyper or hypothyroid, malign diseases were excluded from the study. Also patients with cervical or other regional benign spine or spinal cord tumors, and patients had previously underwent spinal surgery were excluded from the study.

Operation is standard CL at various levels between C3 and C7, and an instrumented fusion was added to this CL. Cervical vertebral mass screws were used for instrumented fusion. Because patients in this study were generally elderly population, artificial bone grafts made of hydroxyapatite with amount of 5 cc for a cervical segment was used.

Measurements

For clinical follow-up mJOA scores by modified by Benzel EC⁽¹⁾ and recovery rate (RR) measurement was used. $RR = \frac{\text{Postop mJOA score} - \text{Preop mJOA score}}{\text{Preop mJOA score}} \times 100$ / 18 – preop mJOA score formula is used for calculation of RR.

For sagittal plane alignment two measurements were used. Cervical lordosis angle (CLA) and the cervical vertical axis (C₂₋₇SVA) (Fig. 1 a, b). These measurements were calculated on plain lateral X-rays. Roentgenograms were taken in the standing position.

CLA is defined as the angle between the line parallel to the C₂ lower end plate and the C₇ upper end plate on the lateral cervical roentgenogram⁽²⁾. Measurement was performed by Cobb method.

C₂₋₇SVA is defined as the distance between the vertical line dropped from the centroid of C₂ corpus and the posterosuperior aspect of C₇ corpus⁽⁵⁾.

Radiologic measurements were performed before and immediately after operations. Postoperative mJOA scores were taken 2 mounts after operations.

Statistical analysis

SPSS ver. 15.0 for windows (SPSS Inc., Chicago, IL, USA) was used for statistical analysis. A descriptive statistics (mean, median, standard deviation, minimum-maximum values) for numerical variables were given. Numerical comparisons in data with normal distribution were carried out by T-test for independent variables and analysis of variance for dependent variables. The results were taken as statistically significant if the p-value was less than 0.05.

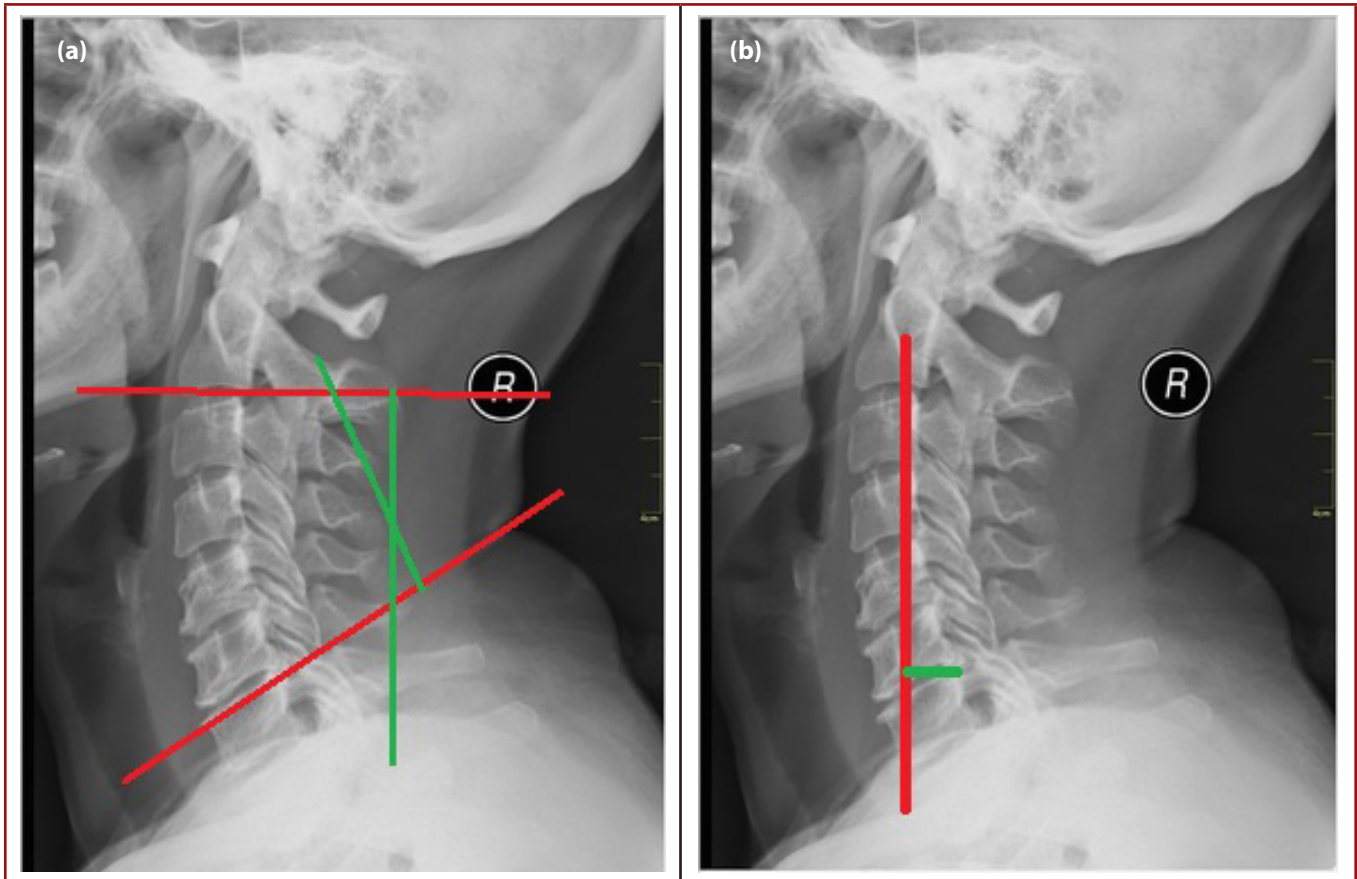


Figure-1. CLA (a) and $C_{2-7}D$ (b) measurements are seen.

RESULTS

The mean value of the preoperative and postoperative mJOA scores of the patients were 7.76 and 12.96 respectively. This result was accepted as statistically significant ($p < 0.001$). The mean RR was 51.62. This result was also statistically significant ($p < 0.001$) (**Table-1**).

CLA changing was statistically significant after operations ($p < 0.05$). The mean preoperative CLA value was 12.9° , and

the mean postoperative value was 14.1° . That the rate of increasing is approximately 8.5 % was slightly more than expected.

The mean preoperative $C_{2-7}SVA$ was 25.9 mm, and the mean postoperative value was 28.1 mm. This changing is not statistically significant ($p > 0.05$).

Table-1. Summary of results

n=50 44 M, 6 F (50-84yo)	Preop mJOA	Postop mJOA	RR	Preop CLA	Postop CLA	Changing rate	Preop $C_{2-7}SVA$	Postop C_{2-7} SVA
Mean	7.76	12.96	51.62	12.9	14.1	8.5%	25.9	28.1
Min-Max values	4.0-10.0	9.0-15.0	33.3-66.7	2.6-23.0	7.2-21.0		8.0-44.0	10.0-61.0

mJOA: Modified Japanese Orthopedic Association scores; RR: Recovery rate; CLA: Cervical lordosis angle in degrees; $C_{2-7}SVA$: C_{2-7} vertical distance in mm.

DISCUSSION

Degenerative cervical diseases generally cause symptoms by compressing some regions of cervical cord or spinal nerves emerging from it at various levels. Besides this main mechanism of pathology, changings in bony structures around the cord affect the function in some degree. In majority of elderly population, simple decompression of neural tissue does not provide a sufficient removal of symptoms. Therefore, existing sagittal alignment disorder or developed disorder after a posterior surgery should be considered when planning a posterior cervical operation for decompression of neural tissue.

In this study mainly two sagittal parameters, CLA and C_{2-7} SVA were considered. For evaluation of cervical lordosis and SB, these two measurements generally accepted as good radiographic parameters respectively ⁽⁶⁾. We also decided to use these parameters. Because restoring lordosis is a vital part of surgical treatment and CLA is a direct method to measure lordosis. Changing in lordosis angle may correlate clinical outcomes ⁽²⁾. In this study, importance of restoring lordosis may be seen clearly. Approximately 8.5% increase in CLA provided a better horizontal gaze for patients after operation.

A good horizontal gaze carries with an important quality of life for especially kyphotic elderly people ⁽¹⁰⁻¹²⁾. Conversely, adults with positive sagittal spinopelvic malalignment compensate with abnormally increased cervical lordosis in an effort to maintain horizontal gaze ⁽¹⁰⁾. Or some adults with negative SB compensate this with dropping their head forward. Therefore the second measurement which was used in this study was C_{2-7} SVA. Because it is a way to directly measure shearing of head forwardly. Unexpectedly, it is seen that, shearing of head toward the front cannot be restored patients covered by this study. In fact, a slight increase of the mean distance can be said. Cervical sagittal imbalance arising from regional and/or global spinal sagittal malalignment may play a part in aggravating adjacent segment disorders after multilevel instrumented fusion ⁽⁸⁾. But, restoring cervical lordosis can be compensate this forward sliding that patients generally no longer suffer from horizontal gaze problem. This event shows us that cervical lordosis may be the most important parameter for cervical sagittal alignment. Although the improvement after cervical decompression was not greatly affected, some authors claimed that postoperative functional outcome scores were significantly lower in patients with C_{2-7} SVA >4-5cm (10,11). In this study, there was no patient with C_{2-7} SVA <8.0 mm. In the new literature, some authors claimed that posterior decompression is not suitable for degenerative cervical myelopathy patients with preoperative cervical sagittal imbalance ⁽⁹⁾. Some investigators asserted that laminectomy is superior to laminoplasty in treatment cervical myelopathy. Base of their opinions is better restoring cervical alignment only ⁽⁴⁾.

That the mean RR was 51.62 can be shown restoring cervical lordosis is also vital part of operation besides decompression. Preoperative SB and cervical contour should be always considered and if there is an existing cervical malalignment it must be restored during fixation with lateral mass screws and rods.

The involvement of global sagittal balance and cervical regional alignment should be considered in evaluating surgical outcomes for patients undergoing cervical posterior decompression and instrumented fusion.

REFERENCES

1. Lee CK, Shin DA, Yi S, Kim KN, Shin HC, Yoon DH, Ha Y. Correlation between cervical spine sagittal alignment clinical outcome after cervical laminoplasty for ossification of the posterior longitudinal ligament. *J Neurosurg Spine* 2016; 24: 100-107.
2. Kaptain GJ, Simmons NE, Replogle RE, Pobereskin L. Incidence and outcome of kyphotic deformity following laminectomy for cervical spondylotic myelopathy. *J Neurosurg* 2000; 93(2 Suppl): 199-204.
3. Benzel EC, Lancon J, Kesterson L, Hadden T. Cervical laminectomy and dentate ligament section for cervical spondylotic myelopathy. *J Spinal Disord* 1991; 4: 286-295.
4. Dağlı M, Er U, Şimşek S, Bavbek M. Late results of anterior cervical discectomy and fusion with interbody cages. *Asian J Neurosurg* 2013; 1: 34-38.
5. Liu X, Chen Y, Yang H, Li T, Xu B, Chen D. Expansive open-door laminoplasty versus laminectomy and instrumented fusion for cases with cervical ossification of the posterior longitudinal ligament and straight lordosis. *Eur Spine J* 2016 Dec 27. doi: 10.1007/s00586-016-4912-7.
6. Vidal C, Ilharreborde B, Azoulay R, Sebaq G, Mazda K. Reliability of cervical lordosis and global sagittal spinal balance measurements in adolescent idiopathic scoliosis. *Eur Spine J* 2013; 22(6): 1362-1367.
7. Smith JS, Shaffrey CI, Lafage V, Blondel B, Schwab F, Hostin R, Hart R, O'Shaughnessy B, Bess S, Hu SS, Deviren V, Ames CP. Spontaneous improvement of cervical alignment after correction of global sagittal balance following pedicle subtraction osteotomy. *J Neurosurg Spine* 2012; 17(4): 300-307.
8. Vital JM, Senegas J. Anatomical bases of the study of the constraints to which the cervical spine is subject in the sagittal plane. A study of the center of gravity of the head. *Surg Radiol Anat* 1986; 8(3): 169-173.

-
9. Patwardhan AG, Khayatzadeh S, Nguyen NL, Havey RM, Voronov LI, Muriuki MG, Carandang G, Smith ZA, Sears W, Lomasney LM, Ghanayem AJ. Is cervical sagittal imbalance a risk factor for adjacent segment pathomechanics after multilevel fusion? *Spine* 2016; 41(10): E580-588.
 10. Oshima Y, Takeshita K, Taniguchi Y, Matsubayashi Y, Doi T, Ohya J, Soma K, Kato S, Oka H, Chikuda H, Tanaka S. Effect of Preoperative Sagittal Balance on Cervical Laminoplasty Outcomes. *Spine* 2016; 41(21): E1265-E1270.
 11. Sakai K, Yoshii T, Hirai T, Arai Y, Shinomiya K, Okawa A. Impact of the surgical treatment for degenerative cervical myelopathy on the preoperative cervical sagittal balance: a review of prospective comparative cohort between anterior decompression with fusion and laminoplasty. *Eur Spine J* 29, 2016 Jul [Epub ahead of print]
 12. Lau D, Winkler EA, Than KD, Chou D, Mummaneni PV. 169 laminoplasty vs laminectomy with posterior spinal fusion for multilevel cervical spondylotic myelopathy: matched cohorts of regional sagittal balance. *Neurosurgery* 2016; 63(Suppl.-1): 167-168.

