



DO BOTULINUM TOXIN-A INJECTIONS INTO THE PARASPINAL MUSCLES CREATE AN IDIOPATHIC LIKE SCOLIOSIS: AN IN VIVO STUDY ON RATS

PARASPİNAL KASLARA BOTULİNUM TOKSİN-A ENJEKSİYONU İLE İDİOPATİK BENZERİ SKOLYOZ ELDE EDİLEBİLİR Mİ? RATLARDA İN VİVO ÇALIŞMA

Kerim SARIYILMAZ ¹,
Okan OZKUNT ¹,
Murat AKSU ²,
Halil Can GEMALMAZ¹,
Mustafa SUNGUR ¹,
Alauddin KOCHAI ³,
Fatih DIKICI ¹

¹Acibadem University Atakent Hospital, Department of Orthopedics and Traumatology, Turgut Ozal Bulvarı, No:16, 34303, Kucukcekmece, Istanbul, Turkey.

²Acibadem University Atakent Hospital, Department of Neurology, Turgut Ozal Bulvarı, No:16, 34303, Kucukcekmece, Istanbul, Turkey.

³Sakarya University, Department of Orthopedics and Traumatology, Sakarya.

Adress: Kerim Sariyilmaz,
Acibadem University Atakent Hospital,
Department of Orthopedics and
Traumatology, Turgut Ozal Bulvarı,
No:16, 34303, Kucukcekmece, Istanbul,
Turkey.

E-mail: ksariyilmaz@gmail.com

Tel: +90 533 541 66 03

Received: 12th October, 2016.

Accepted: 14th December, 2016.

SUMMARY:

Objective: Scoliosis is a spine deformity and also involves some adaptive changes of in paraspinal muscles and ligaments. Some studies found paraspinal EMG activity differences, thus, we hypothesized that blocking the muscle activity of paraspinal muscles in one side of the spine may produce a scoliotic curve.

Methods: 15 female Sprague-Dawley rats were divided into 3 groups as R, L and C. After intraperitoneal anesthesia, for Group R, Botulinum toxin-A was injected to right lumbar paraspinal muscles with the help of EMG. For Group L, Botulinum toxin-A injections were applied in the same manner, into the left paraspinal muscles. In Group C, 1 cc saline injection was applied to the right paraspinal muscles.

Results: In the R Group, left apex lumbar curve was observed in 3 rats. In the L Group, right apex lumbar curve was observed in 3 rats. In the C Group, no one developed any coronal curves. When we evaluated the curves under fluoroscopy, we realized that all of the curves were disappeared under counter-bending maneuver opposite to curves which has caused us to think that that curves were not structural curves.

Conclusion: In this study, we aimed to create a non-surgical scoliosis model in rats by injecting botulinum toxin-A into the paraspinal muscles. To our knowledge, this was the first scoliosis model used botulinum toxin-A injection. Unfortunately, we did not achieve successful results. Future studies with longer follow-up period, larger number of animals, repeated injections and higher dose of Botulinum toxin-A may create a scoliosis model.

Key words: scoliosis; animal model; rat; botulinum toxin-A

Level of Evidence: Experimental animal study, Level II

ÖZET:

Amaç: Skolyoz paraspinal kas ve ligamanlarda da bazı adaptif değişikliklerin olduğu bir deformitedir. Bazı çalışmalar paraspinal EMG aktivitelerinde bazı değişiklikler tespit etmişlerdir. Bu yüzden, bu çalışmadaki hipotezimiz paraspinal kasların bir tarafının kas aktivitesinin bloke edilmesi ile skolyotik bir eğrilik elde edilebileceğiydi.

Metod: 15 dişi Sprague-Dawley rat, R, L ve C olma üzere 3 gruba ayrıldı. İntraperitoneal anestezi sonrası, Grup R'deki ratların sağ lomber paraspinal kaslarına EMG yardımı ile Botulinum Toksin-A enjekte edildi. L grubundaki ratların sol paraspinal kaslarına aynı işlem uygulandı. C grubunun sağ lomber paraspinal kaslarına ise 1 cc salin enjekte edildi.

Sonuçlar: Grup R'de 3 ratta apeksi sol tarafta olan eğrilik olduğu görüldü. Grup L'de 3 ratta apeksi sağ tarafta olan eğrilik olduğu görüldü. Grup C'de herhangi bir koronal eğrilik görülmedi. Floroskopi altında yapılan değerlendirmede, eğrilik gözlenen ratlar eğriliğin karşı tarafına doğru eğilerek bekletildi ve eğriliklerin kaybolduğu görüldü. Bu da bize eğriliğin yapısal bir eğrilik olmadığını düşündürdü.

Çıkarımlar: Bu çalışmada ratların paraspinal kaslarına Botulinum Toksin-A enjeksiyonu yaparak cerrahi-dışı bir skolyoz modeli oluşturmayı amaçladık. Bizim bilgimize göre bu çalışma Botulinum Toksin-A kullanılan ilk skolyoz modelidir. Ne yazık ki başarılı bir sonuç elde edemedik. Daha uzun takibin yapıldığı, daha fazla hayvanın kullanıldığı, tekrarlayan enjeksiyonlar ve daha yüksek dozda Botulinum Toksin-A kullanılan ileriki çalışmalarda yapısal bir skolyoz modeli elde edilebilir.

Anahtar kelimeler: skolyoz; hayvan modeli; rat; botulinum toksin-A

Kanıt Düzeyi: Deneysel hayvan çalışması, Düzey II.

INTRODUCTION:

Adolescent idiopathic scoliosis (AIS) affects 1-3 % of the population and the etiology and pathogenesis remains still unknown. The development of this deformity may be related to development⁽⁸⁾, genetics^(7,29), muscular dysfunction^(11,30), metabolic and chemical problems⁽³¹⁾ and nervous system^(3-5,27). To better understand idiopathic scoliosis, researchers have been developing a variety of animal models to promote this three-dimensional deformity. Von Lesser⁽¹⁸⁾, first described an experimental scoliosis by unilateral dissection of the phrenic nerve in rabbits and produced a thoracolumbar scoliosis. Thereafter, several experimental procedures have been reported in various animals.

The 3D deformity of AIS involves some adaptive changes of each side of the curvature in muscles and ligaments⁽²⁵⁾. Thus, researchers tend to investigate the muscle electrical activities by surface electromyography (SEMG) in these patients.

Some studies found increased paraspinal EMG activity in the convex side^(6,33).

As inspired from these muscle activities of scoliotic patients, we hypothesized that blocking the muscle activity of paraspinal muscles in one side of the spine may produce a scoliotic curve due to existing muscle activity of the other side and finally

pulling and rotating the vertebrae away from the midline. Thus, we aimed to inject botulinum toxin-A to rat paraspinal muscles to create a new scoliosis model.

MATERIAL AND METHODS:

This experimental study included 15 female Sprague-Dawley rats with an age of 3-4 weeks and weight of 130-150 g, obtained from the Animal Laboratory Unit of Acibadem University. Institutional Animal Care and Use Committee approval was obtained before study initiation (ethics committee permission number 2015/27). The rats were divided randomly into 3 groups, 5 in each, as R, L and C.

For anesthesia, all the rats were administered an intraperitoneal injection of 5 mg/kg ketamine/xylazine. Before botulinum toxin-A injections, anteroposterior (AP) and lateral fluoroscopic images were taken to rule out any possible spinal anomalies and curves.

In taking the images in the AP view, the rats were placed in a head-down position, by strapping the hindlimbs and tails to the C arm tube with an adhesive tape, and rotating the C-arm 45° from the horizontal plane to eliminate the gravity effect and prevent positional curves (**Figure-1**).




Figure-1. To eliminate the gravity effect and prevent positional curves, fluoroscopic views were taken by placing the rats in a head-down position and strapping the hindlimbs and tails to the C arm tube with an adhesive tape, and rotating the C-arm 45° from the horizontal plane.

In Group R, 3 U/kg (15) of Botulinum toxinA (Botox, Allergan, Irvine, CA) was injected to right lumbar paraspinal longissimus and ilio-costalis muscle group with the help of

EMG (MP150, BIOPAC Systems Inc., Camino Goleta, California) guidance (**Figure-2**).

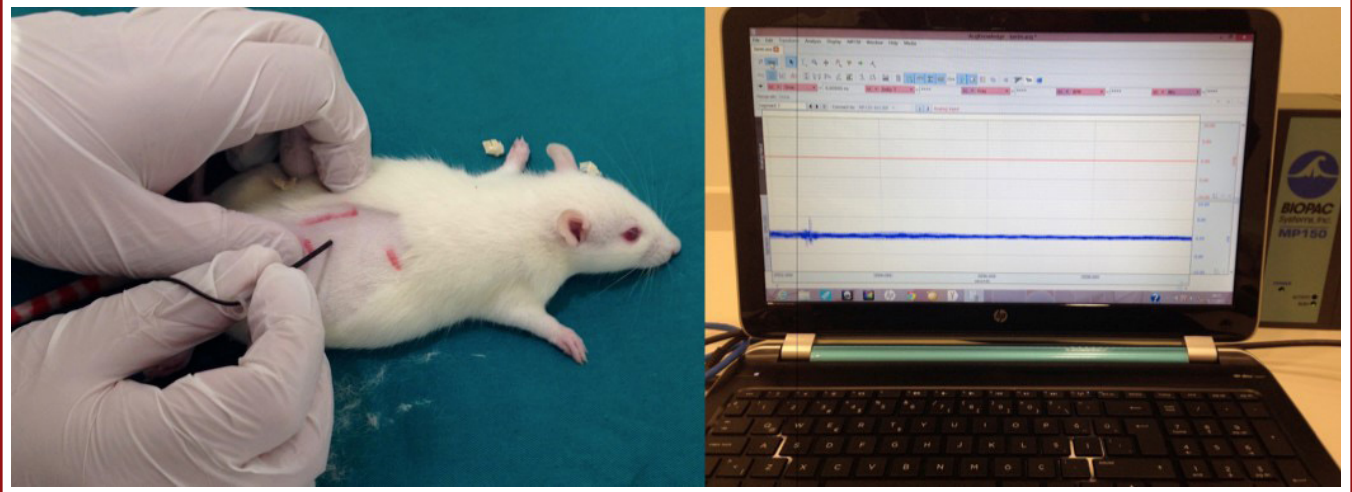


Figure-2. Botulinum toxin-A was injected to paraspinal longissimus and ilio-costalis muscle group with the help of EMG

In Group L, Botox injections were applied in the same manner, into the left paraspinal muscles. In Group C (control group), 1 cc saline injection was applied to the right paraspinal muscles and followed if they develop a curve during the follow-up period.

Rats were housed in group cages in an air-conditioned room with controlled lighting (lights off from 7.00 p.m. to 7.00 a.m.) and given *ad libitum* access to food and water. After 3 months, following intraperitoneal ketamine/xylazine injection,

fluoroscopic images were taken for all rats in the same manner mentioned above.

RESULTS:

In the R Group, left apex lumbar curve was observed in 3 rats. Two rats did not develop any curves and showed a straight spine in the AP view (**Figure-3**).

In the L Group, right apex lumbar curve was observed in 3 rats, however, 2 rats did not show any scoliotic curve (**Figure-4**).

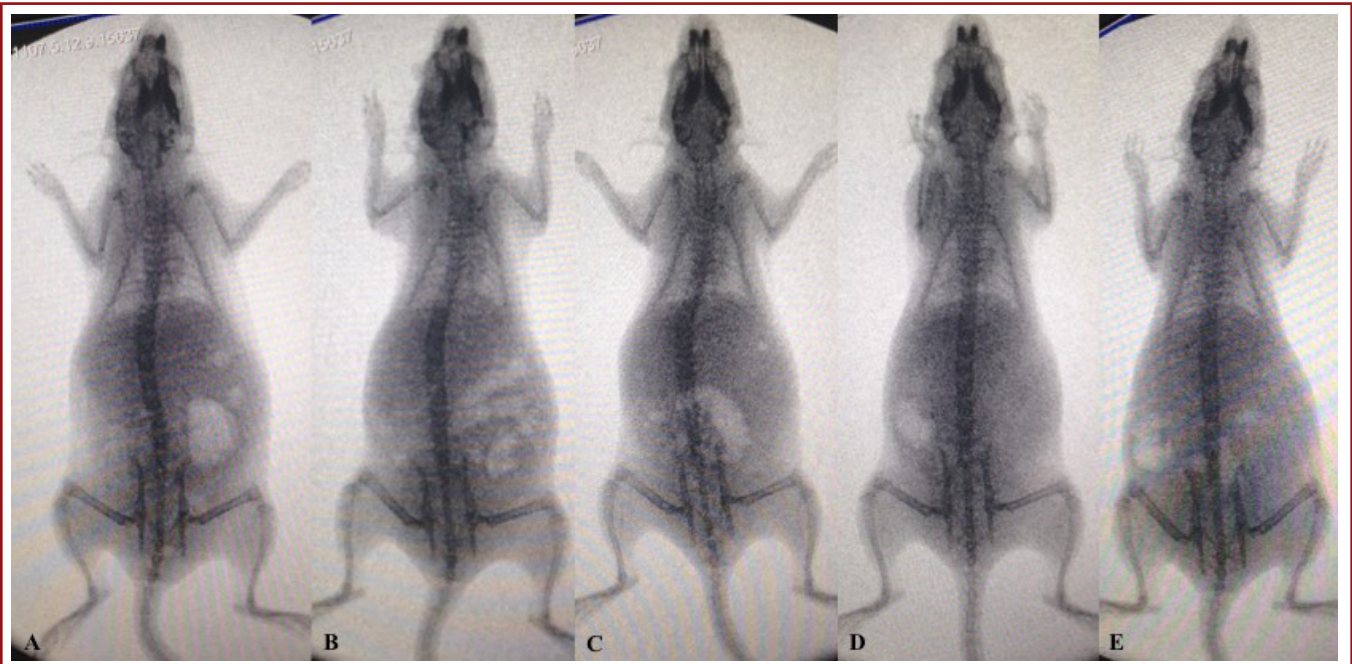


Figure-3. Fluoroscopic views of Group R, 3 months after botulinum toxin-A 432 injection.

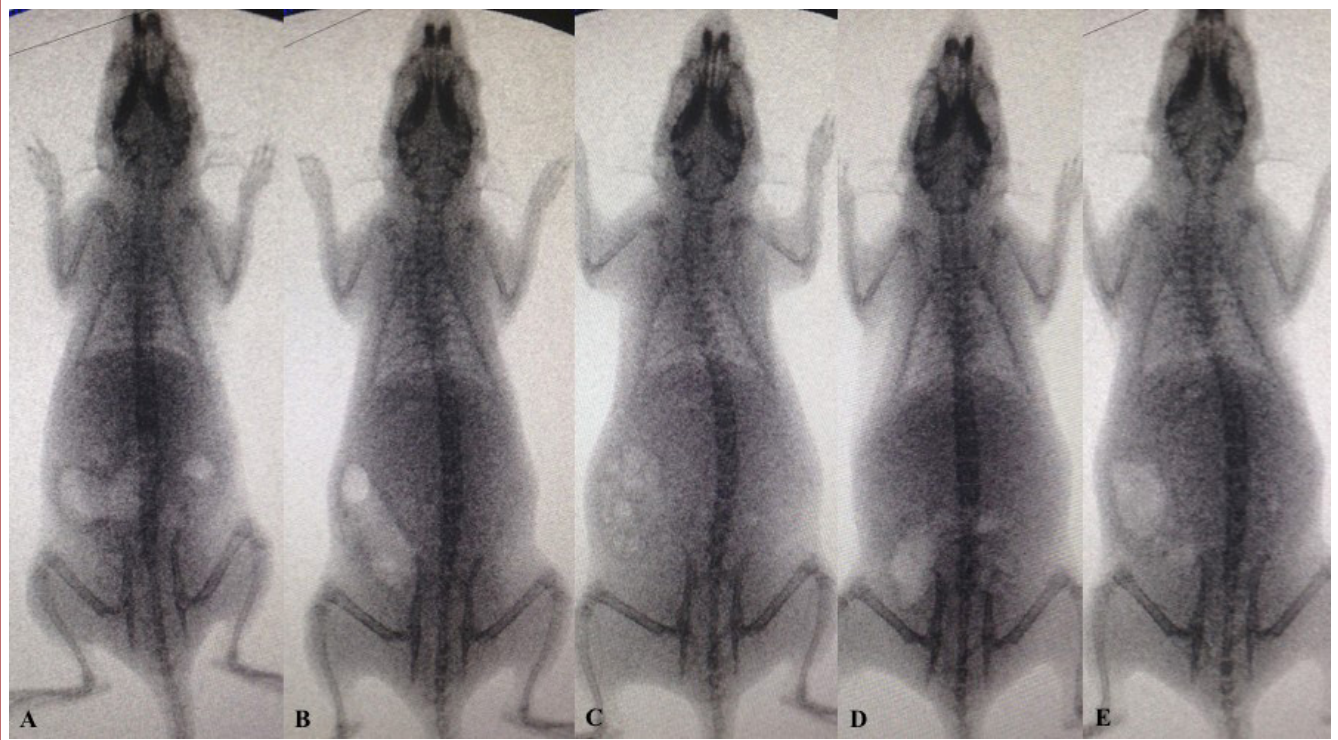


Figure-4. Fluoroscopic views of Group L, 3 months after botulinum toxin-A 435 injection.

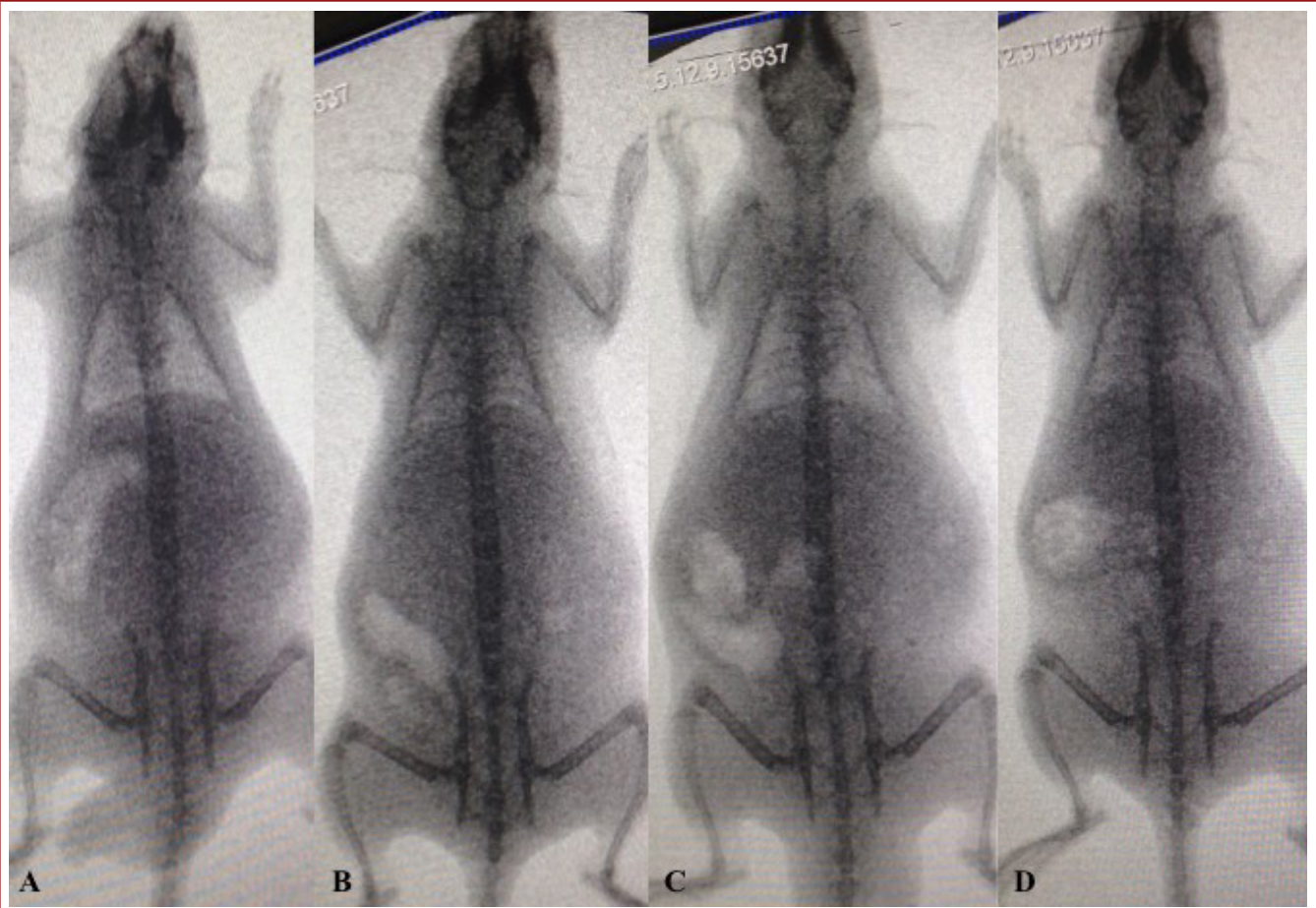


Figure-5. Fluoroscopic views of Group C, 3 months after botulinum toxin-A 438 injection.

In the C Group, one rat died one-day after saline injection due to an unexplained cause. Remaining 4 rats, did not develop any coronal spinal curves during the follow-up period. (Figure-5).

When we evaluated the curves under fluoroscopy, we realized that all of the curves were disappeared under counter-bending maneuver opposite to curves which has caused us to think that that curves were not structural curves.

DISCUSSION:

Despite the various studies of AIS, the etiopathogenesis is still unknown and studies continue to enlighten this issue. Animal models are frequently used to investigate the etiology, however, there is no animal model that replicates this deformity in its multiple characteristics (23).

In a review about animal models, Janssen et al (17), found that chicken is the most widely used experimental animal for scoliosis research, followed by the rabbit, rat and mouse. Primates, sheep, pigs, goats, cows, frogs and dogs also had been used. Although chickens are frequently used, despite the fact that chicken is bipedal, the anatomy and biomechanics is completely different from human (17). In our research, we used rats, because of their low cost and easy handling. The disadvantage of these rodents is the fact that they are quadrupedal. To create a bipedal model, Goff and Landmesser (12), amputated the forelegs and tail in newborn rats and mice. Rats rapidly developed an upright erect walking. Subsequently, many researches used bipedal rats in scoliosis research, and found that bipedal rats and mice showed higher incidences of scoliosis compared with quadrupedal counterparts (2,19-21,24,34). However, it is clearly known that even the spine of bipedal rats and mouse is not loaded in a similar way as the standing human spine due to humans' fully extended knee and hip upright ambulation biomechanics (17). Additionally, it has been demonstrated that scoliosis is not exclusive to bipedalism (13). Thus, to investigate our hypothesis, we used quadrupedal rats in this preliminary study.

Different scoliosis animal models, such as genetic, neuroendocrine, neurologic, growth disturbance, mechanical, teratogenic and spinal cord injury models were used in the literature (23). Most of the scoliosis animal models are invasive procedures such as pinealectomy, brain stem damage, resection of posterior elements, epiphysiodesis, intercostal nerve resection, spinal cord damage, hemilaminectomy and posterior tethering has been widely used. The disadvantages of these procedures were that they are invasive. Damaging the paraspinal tissues may lead to subjective results about the scoliosis model. Although most of the animal studies which focus on producing experimental studies are invasive and surgical procedures, rare noninvasive experimental scoliosis models exist (17).

Poussa et al (28) used an external split in skeletally immature rabbits and obtained scoliosis in over 50 % of the animals. Similarly, Hakkarainen (14) produced scoliosis by a three-point plaster cast in rabbits.

Silva et al (32) immobilized the rats by two vests (scapular and pelvic) which were attached to each other externally, and bend them to right side, and finally they achieved scoliosis after 12 weeks. The advantages of noninvasive scoliosis models were that they do not use any type of surgery, they are very simple and do not affect the surrounding tissues of the spine. Additionally, these non-invasive models can be easily prepared and applied to a large number of animals in a short time period with low costs.

Previous studies showed paraspinal electromyographic activity differences between the convex and concave sides of the scoliotic curve (6,35-36). This may be related to muscular weakness or paravertebral muscle stretching on the convex side. However, it is not clear that these electromyographic changes are due to scoliosis or they cause scoliosis. In a clinical study, Acaroglu et al (1) investigated calmodulin and melatonin levels in adolescent idiopathic scoliosis patients' paravertebral muscles, samples taken during the surgeries and, found higher calmodulin at the convex side and lower at the concave side. Melatonin ratios were not found to be significantly different.

Botulinum toxin is a neurotoxic protein produced by the Clostridium species. It acts by binding presynaptic cholinergic nerve terminals and decreasing the release of acetylcholine, causing a neuromuscular block. It is also developed for medical, cosmetic and research use. As a therapeutic use, it can be used for spasticity, dystonia, involuntary muscle activity, chronic muscle pain, strabismus, muscle hyperactivity disorders and cosmetic problems (16). In light of the paraspinal muscle activities in scoliotic curves, we hypothesized that blocking the muscle activity of paraspinal muscles in one side of the spine may produce a scoliotic curve, thus we planned this animal study, however we did not obtain structural curves. This may be related with inadequate follow-up time or low dose of Botulinum toxin-A injection.

This study has several limitations. First, this is an in vivo animal study and can not simulate an in vivo human characteristics due to different phylogenetic, biomechanics and anatomic features. To create a scoliosis model with higher incidence, bipedal rats could be used, however, it is clearly shown that in scoliosis can be produced in quadrupedal animals. It can be a future study to use bipedal rats with similar methodology. The rats could be followed longer than 3 months, however, the reported selective blocking effect of botulinum toxin A usually wears off 3-4 months after injection (10) and current accepted inter-injection interval is generally 12 weeks or more (22), thus we followed the rats 3 months, which was the botulinum toxin-A maximum effect duration. Lastly, we injected 3 U/kg

botulinum toxin-A, and higher doses could be used up to 18 U/kg safely according to previous studies ^(9,26).

Animal scoliosis models have been widely used to understand the etiology of scoliosis. In this current animal study, we aimed to create a non-surgical scoliosis model in rats by injecting botulinum toxin-A into the paraspinal muscles, unfortunately, we did not achieve successful results. Future studies with longer follow-up period, larger number of animals, repeated injections and higher dose of Botulinum toxin-A may create a scoliosis model.

REFERENCES:

1. Acaroglu E, Akel I, Alanay A, Yazici M, Marcucio R. Comparison of the melatonin and calmodulin in paravertebral muscle and platelets of patients with or without adolescent idiopathic scoliosis. *Spine* 2009; 34: E659-663.
2. Akel I, Demirkiran G, Alanay A, Karahan S, Marcucio R, Acaroglu E. The effect of calmodulin antagonists on scoliosis: bipedal C57BL/6 mice model. *Eur Spine J* 2009; 18: 499-505.
3. Alexander MA, Bunch WH, Ebbesson SO. Can experimental dorsal rhizotomy produce scoliosis? *J Bone Joint Surg* 1972; 54-A: 1509-1513.
4. Barrios C, Arrotegui JJ. Experimental kyphoscoliosis induced in rats by selective brain stem damage. *Int Orthop* 1992; 16: 146-151.
5. Barrios C, Tunon MT, De Salis JA, Beguiristain JL, Canadell J. Scoliosis induced by medullary damage: an experimental study in rabbits. *Spine* 1987; 12: 433-439.
6. Butterworth TR Jr, James C. Electromyographic studies in idiopathic scoliosis. *South Med J* 1969; 62: 1008-1010.
7. Cowell HR, Hall JN, MacEwen GD. Genetic aspects of idiopathic scoliosis. A Nicholas Andry Award essay, 1970. *Clin Orthop Rel Res* 1972; 86: 121-131.
8. Dickson RA, Lawton JO, Archer IA, Butt WP. The pathogenesis of idiopathic scoliosis. Biplanar spinal asymmetry. *J Bone Joint Surg* 1984; 66-B: 8-15.
9. Dodd SL, Selsby J, Payne A, Judge A, Dott C. Botulinum neurotoxin type A causes shifts in myosin heavy chain composition in muscle. *Toxicon* 2005; 46: 196-203.
10. Dolly JO, Aoki KR. The structure and mode of action of different botulinum toxins. *Eur J Neurol* 2006; 13(Suppl.-4): 1-9.
11. Fidler MW, Jowett RL. Muscle imbalance in the aetiology of scoliosis. *J Bone Joint Surg* 1976; 58-B: 200-201.
12. Goff CW, Landmesser W. Bipedal rats and mice; laboratory animals for orthopaedic research. *J Bone Joint Surg* 1957; 39-A: 616-622.
13. Gorman KF, Breden F. Idiopathic-type scoliosis is not exclusive to bipedalism. *Med Hypotheses* 2009; 72: 348-352.
14. Hakkarainen S. Experimental scoliosis: production of structural scoliosis by immobilization of young rabbits in a scoliotic position. *Acta Orthop Scand* 1981; 192: 1-57.
15. Hulst JB, Minamoto VB, Lim MB, Bremner SN, Ward SR, Lieber RL. Systematic test of neurotoxin dose and volume on muscle function in a rat model. *Muscle Nerve* 2014; 49: 709-715.
16. Jankovic J, Brin MF. Botulinum toxin: historical perspective and potential new indications. *Muscle Nerve* 1997; 6: S129-145.
17. Janssen MM, de Wilde RF, Kouwenhoven JW, Castelein RM. Experimental animal models in scoliosis research: a review of the literature. *Spine J* 2011; 11: 347-358.
18. Von Lesser L. Experimentelles und Klinisches über Skoliose. (Experimental and clinical scoliosis). *Virchows Arch* 1888; 113: 10-46.
19. Machida M, Dubousset J, Yamada T, Kimura J, Saito M, Shiraishi T, Yamagishi M. Experimental scoliosis in melatonin-deficient C57BL/6J mice without pinealectomy. *J Pineal Res* 2006; 41: 1-7.
20. Machida M, Murai I, Miyashita Y, Dubousset J, Yamada T, Kimura J. Pathogenesis of idiopathic scoliosis. Experimental study in rats. *Spine* 1999; 24: 1985-1989.
21. Machida M, Saito M, Dubousset J, Yamada T, Kimura J, Shibusaki K. Pathological mechanism of idiopathic scoliosis: experimental scoliosis in pinealectomized rats. *Eur Spine J* 2005; 14: 843-848.
22. Ojo OO, Fernandez HH. Is it time for flexibility in botulinum inter-injection intervals? *Toxicon* 2015; 107: 72-76.
23. Ouellet J, Odent T. Animal models for scoliosis research: state of the art, current concepts and future perspective applications. *Eur Spine J* 2013; 22(Suppl.-12): S81-95.
24. Oyama J, Murai I, Kanazawa K, Machida M. Bipedal ambulation induces experimental scoliosis in C57BL/6J mice with reduced plasma and pineal melatonin levels. *J Pineal Res* 2006; 40: 219-224.
25. Stagnara P, Dove J (Eds.). *Spinal Deformity*. Butterworths, Boston 1988.

-
26. Pickett A, O’Keeffe R, Judge A, Dodd S. The in vivo rat muscle force model is a reliable and clinically relevant test of consistency among botulinum toxin preparations. *Toxicon* 2008; 52: 455-464.
 27. Pincott JR, Davies JS, Taffs LF. Scoliosis caused by section of dorsal spinal nerve roots. *J Bone Joint Surg* 1984; 66-B: 27-29.
 28. Poussa M, Schlenzka D, Ritsila V. Scoliosis in growing rabbits induced with an extension splint. *Acta Orthop Scand* 1991; 62: 136-138.
 29. Fischer RL, DeGeorge FV. Idiopathic scoliosis: an investigation of genetic and environmental factors. *J Bone Joint Surg* 1976; 49: 1005-1006.
 30. Roaf R. The basic anatomy of scoliosis. *J Bone Joint Surg* 1966; 48-B: 786-792.
 31. Rodriguez RM Sr, Bailey RW, Rodriguez RP Jr. Skeletal lesions of lathyrism and effects of bipedalism on spine development. *Clin Orthop Rel Res* 1965; 41: 189-197.
 32. Silva CA, Guirro RR, Delfino GB, Arruda EJ. Proposal of non-invasive experimental model to induce scoliosis in rats. *Rev Bras Fisioter* 2012; 16: 254-260.
 33. Zuk T. The role of spinal and abdominal muscles in the pathogenesis of scoliosis. *J Bone Joint Surg* 1962; 44-B: 102-105.
 34. Tanaka H, Kimura Y, Ujino Y. The experimental study of scoliosis in bipedal rat in lathyrism. *Arch Orthop Trauma Surg* 1982; 101: 1-27.
 35. Zetterberg C, Bjork R, Ortengren R, Andersson GB. Electromyography of the paravertebral muscles in idiopathic scoliosis. Measurements of amplitude and spectral changes under load. *Acta Orthop Scand* 1984; 55: 304-309.
 36. Zetterberg C, Hansson T, Lindstrom J, Irstam L, Andersson GB. Postural and time-dependent effects on body height and scoliosis angle in adolescent idiopathic scoliosis. *Acta Orthop Scand* 1983; 54: 836-840.

