



LUMBAR SPINAL CANAL DIAMETERS AND AREA MEASUREMENTS IN HEALTHY INDIVIDUALS

Birnur YILMAZ¹,
Burçak GÜMÜŞ¹,
Halime ÇEVİK¹,
Sadık Ahmet UYANIK¹

¹Okan University Istanbul Hospital,
Department of Radiology, Istanbul,
Turkey

SUMMARY

Objective: We aimed to the lumbar spinal canal lengths and area measurements were measured in normal healthy individuals between 20 and 50 years of age in the Turkish population by Magnetic Resonance Imaging (MRI).

Material and Methods: Three measurements were analyzed in axial MRI of 50 (30 male, 20 female) healthy individuals in 20-50 age groups (mean age:33,69±12). In T2-weighted fast spin-echo (FSE) axial MR images, measurements were obtained at L3-4, L4-5, L5-S1 levels. Measured lumbar spinal canal anterior-posterior diameter (DSAPD) mm and spinal canal transverse diameter (DSTD), mm and spinal canal cross-sectional area (DSCSA), mm² measurements in healthy individuals by axial MRI (figure1,2,3). SIGNA Explorer GE 1,5 T MR device used. The patients were placed in the supine position with a cushion under both knees. T2-weighted FSE axial and sagittal images were obtained (TR/TE, 3213.48/100.00 ms for axial scan and 3207.27/100.00 ms for sagittal scan; slice thickness, 4 mm; slice gap, 0.4 mm; field of view, 16 cm for axial scan and 32 cm for sagittal scan; matrix, 256 × 216 of axial scan and 512 × 252 for sagittal scan; flip angle, 90°; ETL, 18; and excitations, 3). On T2-weighted FSE axial images, spinal canal diameter and area measurements were performed.

Results: Lumbar spinal canal measurements; Lumbar DSAPD L3-4 (24,46± 2,12) mm, L4-5 (22,86± 2,07) mm, L5-S1 (20,36± 2,13) mm, DSTD L3-4 (27,16± 2,10) mm, L4-5 (27,06± 2,03) mm, L5-S1 (26,46± 2,47) mm, lumbar DSCSA L3-4 (272,0± 21,4) mm², L4-5 (254,6± 20,7) mm², L5-S1 (234,6± 22,7) mm² were measured in healthy individuals.

Conclusion: In evaluating lumbar spinal stenosis, it is necessary to know the lumbar spinal canal measurements in normal individuals. MRI is an important examination in evaluating lumbar spinal canal measurements.

Keywords: Lumbar Spinal Canal, Lumbar Spinal canal, Magnetic Resonance Imaging.

Level of evidence: Retrospective Clinical Study, Level III

INTRODUCTION

We aimed to the lumbar spinal canal lengths and area measurements were measured in normal healthy individuals between 20 and 50 years of age in the Turkish population by MRI. MRI is the most diagnostic method for spinal pathologies. Degenerative changes in facet joints can be in the form of facet hypertrophy, osteophytes spur development, cartilage narrowing, joint effusion, and capsular hypertrophy, all of which can be assessed in detail by MRI⁽⁴⁾. Axial and sagittal MRIs typically show narrowed spinal canals.

In lumbar spinal stenosis, T1-weighted images are useful for evaluating the width

and contours of the foramen and conus medullaris. T2-weighted images provide an accurate assessment of spinal canal diameters. The decrease in epidural fat tissue due to the hypertrophic bone, T1 and T2 weighted image with low density, hypertrophic ligament flavum, T1 and T2 weighted images and moderate thickening and prolonged compression appear as a dark color from high to low on the T1 signal. The fat signal around the nerve root (seen best in T1-weighted images) appears to be reduced in axial and sagittal images^(1,2). MR examination has several advantages over CT. The patient does not receive ionizing radiation and the procedure is non-invasive. Also, the

Address: Birnur YILMAZ, Aydınlı
Cad. No: 2 Okan University Hospital,
İçmeler, Tuzla, İstanbul, Turkey.
Phone: +90 (533) 6424136
Fax number: +90 (216) 4946526
E-mail: birnurtavasli@yahoo.com
Received: 11th April, 2017.
Accepted: 3rd June, 2017

patient does not need to be in the hospital. As with myelography, all lumbar vertebrae can be visualized. Soft tissue evaluation of conus, cauda equina, and nerve roots is better than CT. Ligamentum flavum, disc herniation and intraspinal synovial cysts are more common in imaging than other methods. MR is superior to CT and myelography in predicting the loss of epidural fat tissue (3-5).

MRI examination also has some disadvantages. In the case of lumbar spinal stenosis, cortical bone and osteophytes are less visible. MRI examinations can not be performed on those who have non-titanium metal devices in the spine, eyes and cranium, pacemakers and claustrophobia. MRI is also a more expensive test than CT (5-12,14).

To assess spinal stenosis, spinal canal diameters need to be known in normal healthy individuals. Therefore, we have measured these lumbar spinal canal measurements in a limited number of healthy individuals.

MATERIALS AND METHODS

Three measurements were analyzed in axial MRI of 50 (30 male, 20 female) healthy individuals in 20-50 age groups (mean age:33,69±12). In T2-weighted fast spin-echo (FSE) axial MR images, measurements were obtained at L3-4, L4-5, L5-S1 levels. Measured lumbar spinal canal anterior-posterior diameter (DSAPD) mm and spinal canal transverse diameter (DSTD), mm and spinal canal cross-sectional area (DSCSA), mm² measurements in healthy individuals by axial MRI (figure1,2,3). SIGNA Explorer GE 1,5 T MR device used. The patients were placed in the supine position with a cushion under both knees. T2-weighted FSE axial and sagittal images were obtained (TR/TE, 3213.48/100.00 ms for axial scan and 3207.27/100.00 ms for sagittal scan; slice thickness, 4 mm; slice gap, 0.4 mm; field of view, 16 cm for axial scan and 32 cm for sagittal scan; matrix, 256 × 216 of axial scan and 512 × 252 for sagittal scan; flip angle, 90°; ETL, 18; and excitations, 3). On T2-weighted FSE axial images, spinal canal diameter and area measurements were performed.

Image Analysis

Three radiologists (readers 1,2,3) participated in all three-step evaluations in this study. Before the review of the lumbar MRIs in the pre-step evaluation, three radiologists discussed the measurements of the lumbar spinal canal and established a consensus measurements that they would use on T2-weighted axial images. All evaluations were completed, one radiologist (reader 1) repeated the last second-step evaluation to allow calculation of intra-reader agreement and also to measure. DSCSA, DSAPD, and DSTD on T2-weighted axial images and on T2-weighted mid-sagittal images at each disc level of the lumbar spine working manually at a Workstation.

Ethics Committee approved and written consent form was taken from all the volunteers. Those with spondylodiscitis, who underwent disc surgery, and those with inflammatory diseases such as ankylosing spondylitis were excluded from the study.

Statistical Package for Social Sciences (SPSS) v23.0 (IBM co. Chicago IL) was used for statistical analyses. ANOVA test was used.

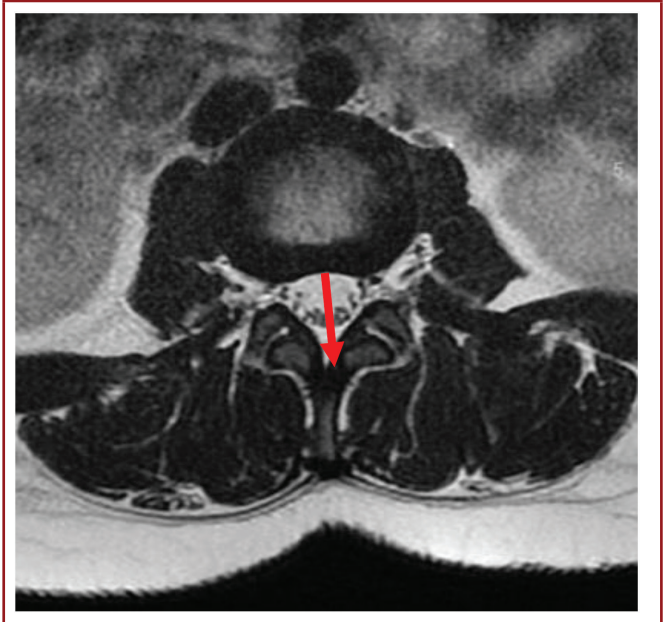


Figure-1. Lumbar spinal canal anterior-posterior diameter measurements.

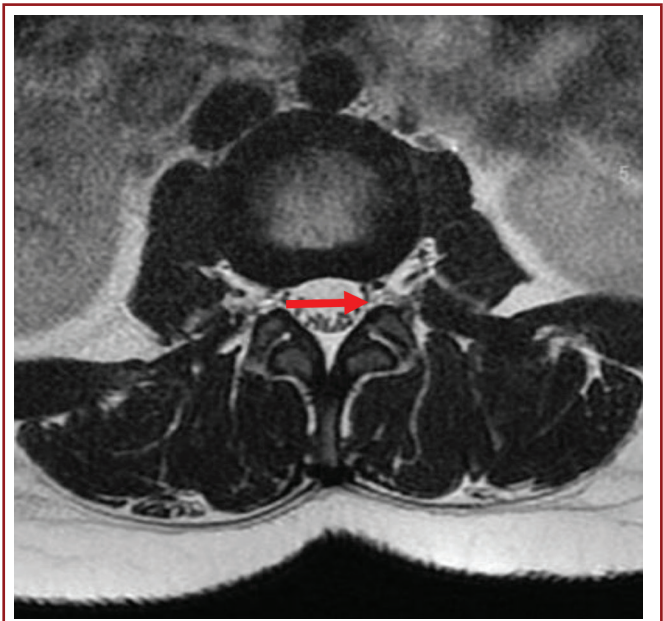


Figure-2. Lumbar spinal canal transverse diameter measurements.

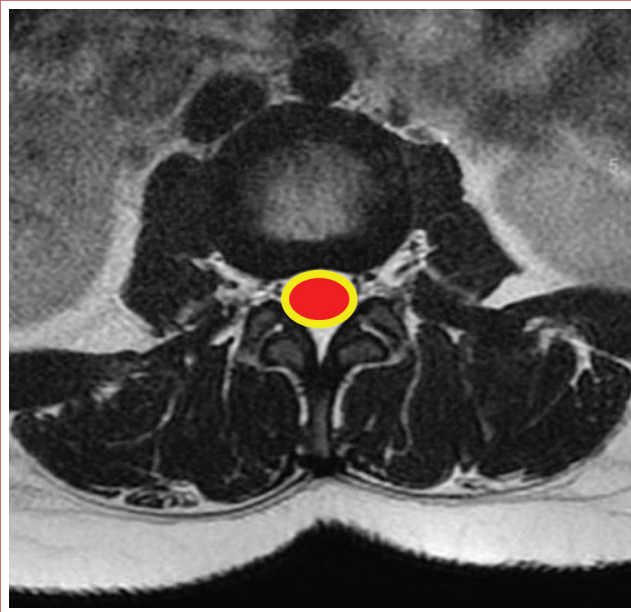


Figure-3. Lumbar spinal canal cross-sectional area measurements.

RESULTS

Lumbar spinal canal measurements; Lumbar DSAPD L3-4 (24,46± 2,12) mm, L4-5 (22,86± 2,07) mm, L5-S1 (20,36± 2,13) mm; DSTD L3-4 (27,16± 2,10) mm, L4-5 (27,06± 2,03) mm, L5-S1 (26,46± 2,47) mm; lumbar DSCSA L3-4 (272,0± 21,4) mm², L4-5 (254,6± 20,7) mm², L5-S1 (234,6± 22,7) mm² were measured in healthy individuals (Table-1,2).

Table-1. Lumbar spinal canal anterior-posterior diameter and transverse diameter measurements (mm).

Lumbar Levels	Spinal Canal Antero-posterior Diameter Mean± SD	Spinal Canal Transverse Diameter Mean± SD
L3-4	24,46± 2,12	27,16± 2,10
L4-5	22,86± 2,07	27,06± 2,03
L5-S1	20,36± 2,13	26,46± 2,47

SD: Standard deviation

Table-2. Lumbar spinal canal cross-sectional area measurements (mm²).

Lumbar Levels	Spinal Canal Cross-Sectional Area Mean± SD
L3-4	272,0± 21,4
L4-5	254,6± 20,7
L5-S1	234,6± 22,7

DISCUSSION

It is usually due to degenerative changes of the vertebral column in the elderly, resulting in lumbar spinal stenosis. Nowadays, the increase in the average age of the population increases the importance of degenerative lumbar spinal stenosis. Patients with neurogenic claudication or sciatica complaints are restricted in their functional activities and become dependent on the bed. Lumbar spinal stenosis typically occurs as a result of complex degenerative processes that produce pressure in neural elements. Spinal stenosis, central cord stenosis, lateral recess stenosis, degenerative spondylolisthesis or confusion due to all three. In addition to these findings, disc herniation may be accompanied by pathology. Degenerative stenosis and lumbar spondylosis are thought to occur due to recurrent axial loading and rotational constraints, facet hypertrophy, ligamentum flavum thickening, and osteophyte formation. Other causes of spinal stenosis include postoperative, post-traumatic, neoplastic, infectious, bone disease-related (as in Paget's disease), congenital stenosis (achondroplastic form).

On the basis of the results of previous studies, a >15 mm² change in the DCSA induced by axial loading was defined as a significant change,⁽¹⁵⁻¹⁷⁾ worsening the severity of the clinical symptoms⁽⁹⁾. If the anterior posterior diameter of the lumbar canal is less than 10 mm, it is considered as an absolute stenosis. If this diameter is less than 13 mm, it is regarded as relative stenosis^(3,13).

The results we have found in our study are consistent with previous literature studies. Until now, there is no study of normal spinal canal measurements in the Turkish population.

Among the limitations of this study, it is not possible to standardize on the gender, age, weight, and height of the individuals taken into the study. This study is limited to only 50 people and it is a preliminary study. In future studies, the number of working groups should be increased. In order to standardize lumbar spinal canal measurements in Turkish society, there is a need for further studies.

In evaluating lumbar spinal stenosis, it is necessary to know the lumbar spinal canal measurements in normal individuals. MRI is an important examination in evaluating lumbar spinal canal measurements.

REFERENCES

- Amundsen T, Weber H, Lilleas F, Nordal HJ, Magnaes B, Abdelnoor M, Lilleås F. Lumbar spinal stenosis clinical and radiologic features. *Spine* 1995; 10: 1178-1186.
- Binder DK, Schmidt MH, Weinstein PR. Lumbar spinal stenosis. *Semin Neurol* 2002; 2: 157-165.

-
3. Boden SD, Davis DO, Dina TS, Patronas NJ, Wiesel SW. Abnormal magnetic-resonance scans of the lumbar spine in asymptomatic subjects. A prospective investigation. *J Bone Joint Surg* 1990;72-A: 403-408.
 4. Epstein NE, Epstein JE. Lumbar decompression for spinal stenosis. In: Frymoyer JW (Ed.), *The Adult Spine: Principles and Practice*. Lippincott-Raven, Philadelphia 1997; pp: 2055-2088.
 5. Haba K, Ikeda M, Soma M, Yamashita T. Bilateral decompression of multilevel lumbar spinal stenosis through a unilateral approach. *J Clin Neurosci* 2005; (2): 169-171.
 6. Herno A, Airaksinen O, Sari T. Long-term result of surgical treatment of lumbar spinal stenosis. *Spine* 1993; 18(11): 1471-1474.
 7. Kanno H, Ozawa H, Koizumi Y, Koizumi Y, Morozumi N, Itoi E, Ishii Y. Dynamic change of spinal canal cross-sectional area in axial loaded magnetic resonance imaging correlates with the severity of clinical symptoms in patients with lumbar spinal canal stenosis. *Spine* 2012; 37: 207-213.
 8. Önel D, Sarı H, Dönmez Ç. Lumbar spinal stenosis: Clinical/radiologic therapeutic evaluation in 145 patients. *Spine* 1993; 18(2): 291-298.
 9. Pappas CTE, Sonntag VKH. Degenerative disorders of the spine: lumbar stenosis. In: Menezes AH, Sonntag VKH, Benzel EC (Eds.). *Principles of Spinal Surgery*, 1996; 631-644.
 10. Porter RW. Spinal stenosis and neurogenic claudication. *Spine* 1996; 21(17): 2046-2052.
 11. Rauschnig W. Anatomy and pathology of the lumbar spine. In: Frymoyer JW (Ed.), *The Adult Spine*. Lippincott-Raven, Philadelphia 1997; pp: 1687-1703.
 12. Roland M, Fairbank J. The Roland-Morris disability questionnaire and the Oswestry disability questionnaire. *Spine* 2000; 25(24): 3115-3124.
 13. Ullrich CG, Binet EF, Sanecki MG, Kieffer SA. Quantitative assessment of the lumbar spinal canal by computed tomography. *Radiology* 1980; 134: 137-143.
 14. White AA, Panjabi MM. *Clinical Biomechanics of the Spine*. 2nd ed., Lippincott, Philadelphia 1990.
 15. Willén J, Danielson B, Gaultz A, Niklason T, Schönström N, Hansson T. Dynamic effects on the lumbar spinal canal: axially loaded CT-myelography and MRI in patients with sciatica and/or neurogenic claudication. *Spine* 1997; 22: 2968-2976.
 16. Willén J, Danielson B. The diagnostic effect from axial loading of the lumbar spine during computed tomography and magnetic resonance imaging in patients with degenerative disorders. *Spine* 2001; 26: 2607-2614.
 17. Willén J, Wessberg PJ, Danielsson B. Surgical results in hidden lumbar spinal stenosis detected by axial loaded computed tomography and magnetic resonance imaging: an outcome study. *Spine* 2008; 33: E109-115.