



ANTERIOR CERVICAL DISCECTOMY: EVALUATION WITH CERVICAL LORDOSIS AND SAGITTAL VERTICAL AXIS MEASUREMENT

Mustafa KAYA¹,
Veysel ANTAR²

¹ Ereğli State Hospital, Neurosurgery
Clinic, Zonguldak

² İstanbul Training and Research
Hospital, Department of Neurosurgery,
İstanbul

ORCID Numbers:

Mustafa Kaya: 0000-0001-9401-0311

Veysel Antar: 0000-0003-2144-6442

Corresponding Author:

Address: Mustafa KAYA, Ereğli State
Hospital, Zonguldak, TURKEY

Tel: +90 542 694 50 01

E-mail: mkaya2834@gmail.com

Received: 10th January, 2018

Accepted: 12th March, 2018.

ABSTRACT

Aim: The purpose of this study is therefore to compare cervical lordosis and sagittal vertical axis values before and after anterior cervical discectomy operations.

Materials-Method: We evaluated 62 patients who were operated for cervical disc herniation between 2016-2018 retrospectively. Cervical X-ray graphics were taken as standing lateral neutral positioned preoperative and postoperative periods. These graphics were searched with the radiology pacs program and CL angle and SVA were measured at preoperative and postoperative periods.

Results: A total of 62 patients included in the analyses. Mean age of the study group was 45.9±8 years, and M/F ratio was 26/36 (41.9 % vs. 58.1 %). Most frequent diagnosis was C4-5 disc hernia (n=28, 45.2 %), and most frequent operation was C4-5 microdiscectomy + interbody fusion. Comparisons between study periods revealed that postoperative CL was significantly increased when compared to preoperative values (p<0.001), but there was no significant difference for SVA (p=0.445).

Conclusion: There are different results for the discussion on cervical sagittal alignment changes after anterior cervical discectomy operations. We found that cervical lordosis is increasing significantly after anterior cervical discectomy operations whereas SVA not. Anterior cervical discectomy operations support to maintain CL in degenerative cervical disc disease. However, further investigations with an increased amount of cervical spine data are needed with long-term results.

Key Words: Anterior cervical discectomy, cervical lordosis, Cobb angles, sagittal vertical axis

Level of Evidence: Retrospective clinical study, Level III.

INTRODUCTION

Cervical degenerative disc disease is a common cause of pain and disability. Most symptomatic cases present between the ages of 40-60, although many individuals never develop symptoms⁽⁹⁾. Anterior cervical discectomy surgery has become a standard treatment for cervical degenerative disc disease as it is a proven intervention for patients with myelopathy and radiculopathy as it affords the surgeon the ability to provide direct decompression with discectomy and restoration of disc height⁽⁶⁾.

The widest range of motion is on the cervical spine relative to the rest of the spine and this region supports the mass of the head⁽¹³⁾. Sagittal balance of the

spine is a fundamental element necessary for understanding spinal disease and instituting proper treatment. The procedure of drawing perpendiculars to vertebral body endplate lines to evaluate scoliotic curves on anteroposterior radiographs was reported by Lippman in 1945, which was later popularized in 1948 by Cobb^(1,16). The major parameters used to assess the cervical spine alignment include the Cobb angles, Jackson stress lines, and Harrison posterior tangent lines for the sagittal curvature, and the gravity line or C2 plumb line for the SVA.

The purpose of this study is therefore to compare cervical lordosis and sagittal vertical axis values before and after anterior cervical discectomy operations.

MATERIALS AND METHOD

We evaluated 62 patients who were operated for cervical disc herniation between 2016-2018 retrospectively. Cervical X-ray graphics were taken as standing lateral neutral positioned preoperative and postoperative period. These graphics were searched with the radiology pacs program and CL angle and SVA measurement of these patient were evaluated with the techniques being explained below (Figure-1):

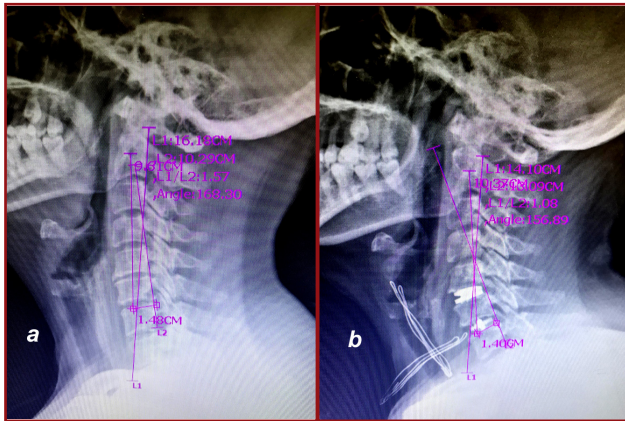


Figure-1. (a) Preoperative and **(b)** postoperative cervical sagittal measurement of the patient A.B.

Cobb Angle: Cobb angles are measured with a line either parallel to the inferior endplate of C₂ to the posterior margin

of the spinous process, and another line parallel to the inferior endplate of C₇.

Sagittal vertical axis: A plumb line is drawn from the center of C₂, and the distance from this line to the posterior corner of the upper endplate of C₇ is obtained.

Statistical Analyses

Descriptive data were presented using mean and standard deviation, and frequencies and percent. Wilcoxon test was used for comparisons between the dependent groups of the study (preoperative and postoperative angle measurements), and statistical significance was evaluated according to a two-sided Type-I error level of 5 %. Statistical Package for the Social Sciences (SPSS) 21 software (IBM Corp. in Armonk, NY) was used for all statistical analyses of this research.

RESULTS

A total of 62 patients included in the analyses. Mean age of the study group was 45.9±8 years, and M/F ratio was 26/36 (41.9 % vs. 58.1 %). Most frequent diagnosis was C4-5 disc hernia (n=28, 45.2 %), and most frequent operation was C4-5 microdiscectomy + interbody fusion. General demographics of the patients was presented in Table-1.

CL and SVA between preoperative and postoperative periods was presented in Table-2. Accordingly, comparisons between study periods revealed that postoperative CL was significantly increased when compared to preoperative values (p<0.001), but there was no significant difference for SVA (p=0.445).

Table-1. General demographics of the patients

	Mean	SD
	n	%
Age (years)	45,9	8
Sex		
Male	26	41.9
Female	36	58.1
Diagnosis		
C4-5 disc hernia	28	45.2
C4-5-6 disc hernia	20	32.3
C5-6 disc hernia	10	16.1
C5-6-7 disc hernia	2	3.2
C6-7 disc hernia	2	3.2
Operation		
C4-5 microdiscectomy + interbody fusion	28	45.2
C4-5-5 microdiscectomy + interbody fusion	20	32.3
C5-6 microdiscectomy + interbody fusion	10	16.1
C5-6-7 microdiscectomy + interbody fusion	2	3.2
C6-7 microdiscectomy + interbody fusion	2	3.2

Table-2. Pre- and post-operative angle measurements

	Preoperative		Postoperative		P
	Mean	SD	Mean	SD	
CL: Cervical Lordosis	13	18.1	18.1	13.2	<0.001
SVA: Sagittal Vertical Axis	1.9	1	1.8	0.9	0.445

DISCUSSION

Anterior cervical discectomy has been suggested as an effective and safe treatment for spinal cervical degenerative disc diseases. Clinical importance of sagittal balance is important in the management of spinal degenerative pathologies. Cervical lordosis (CL) may be dependent on the anatomy of the cervico-thoracic junction (CTJ), which typically involves the C₇ and T₁ vertebrae, the C₁₋₇ discs, and the associated ligaments⁽¹⁵⁾. CTJ is the site at which lordosis of the cervical spine changes to kyphosis in the thoracic spine⁽²⁾.

Although a few studies have reported the normal sagittal balance of the cervical spine and physiological CL has not been clearly defined yet, Hardacker et al. reported a mean CL of 40.0° ± 9.7° that had a significant correlation with thoracic kyphosis⁽⁵⁾. Lee et al. reported that the mean values C₂₋₇ angle was 9.9° ± 12.5°⁽¹²⁾. Also Gore et al. reported C₂-C₇ cervical lordosis angles of 16° for men and 15° for women⁽⁴⁾. Özdoğan et al reported mean values of C₂₋₇ as 18,37° ± 9,44° in their study⁽¹⁴⁾.

There is not much nominative data for the gravity line or C2 plumb line for the SVA Hardacker et al. reported a C7 SVA mean value of 15.6 mm⁽⁵⁾. Gore et al. reported a mean SVA of 16.8 mm, and also suggested that CL increased with age, but did not address the adjacent spinal alignment measurements or segmental cervical values⁽⁴⁾.

Jeon et al reported on 33 patients who were operated for three or more level anterior cervical discectomy and fusion surgery under neutral supine position and they found that surgery did not significantly change the postoperative cervical alignment⁽⁷⁾. Gillis et al found that anterior discectomy with 1 and two levels is able to achieve statistically significant improvement in cervical lordosis by the 1-year follow-up with a mean improvement of 3.46° but not with SVA⁽³⁾. Our study's results are supporting Gillis' report.

Katsuura et al reported with 69 patients that multilevel anterior cervical discectomy and fusion surgery significantly increases and maintains both segmental and global cervical lordosis up to 6 months after surgery and increasing C2-C7 global lordosis is correlated with increasing positive sagittal vertical axis⁽⁸⁾. Kwon et al found that C2-7 SVA after two-level anterior cervical discectomy and fusion surgery was affected more significantly by the sagittal angle and C2-7

angle than by the T1 slope and two-level anterior cervical discectomy and fusion surgery with plate restored more cervical lordosis by obtaining more segmental lordosis at the operated level and was more effective in terms of cervical alignment compared with anterior cervical discectomy and fusion surgery using stand-alone cages⁽¹¹⁾. Kim et al reported that anterior cervical discectomy and fusion surgery affects whole spine sagittal alignment, especially in patients with high cervical lordosis and in these patients, alteration of cervical lordosis to a normal angle shortened the SVA and resulted in reciprocal changes in pelvic tilt and sacral slope⁽¹⁰⁾.

Conclusion

There are different results for the discussion on cervical sagittal alignment changes after anterior cervical discectomy operations. We found that cervical lordosis is increasing significantly after anterior cervical discectomy operations whereas SVA not. Anterior cervical discectomy operations support to maintain CL in degenerative cervical disc disease. However, further investigations with an increased amount of cervical spine data are needed with long-term results.

REFERENCES

1. Cobb JR. Outlines for the study of scoliosis. In: Edwards JW (Ed.). *Instructional Course Lecture*. Vol 5. American Academy of Orthopedic Surgeons, Ann Arbor 1948; p: 261-275.
2. Deviren V, Scheer JK, Ames CP. Technique of cervicothoracic junction pedicle subtraction osteotomy for cervical sagittal imbalance: report of 11 cases. Clinical article. *J Neurosurg Spine* 2011; 15: 174-181.
3. Gillis CC, Kaszuba MC, Traynelis VC. Cervical radiographic parameters in 1- and 2-level anterior cervical discectomy and fusion. *J Neurosurg Spine* 2016; 25(4): 421-429.
4. Gore DR, Sepic SB, Gardner GM. Roentgenographic findings of the cervical spine in asymptomatic people. *Spine* 1986; 11: 521-524.
5. Hardacker JW, Shuford RE, Capicotto PN, Pryor PW. Radiographic standing cervical segmental alignment in adult volunteers without neck symptoms. *Spine* 1997; 22: 1472-1480.
6. Istemen I, Ozdogan S, Duzkalir AH, Senturk S, Yildirim T, Okutan MO. Clinical results of median corpectomy in cervical spondylotic patients with myelopathy. *Turk Neurosurg* 2016; 26(1): 90-96.

-
7. Jeon SI, Hyun SJ, Han S, Lee BH, Kim KJ, Jahng TA, Kim HJ. Relationship between cervical sagittal alignment and patient outcomes after anterior cervical fusion surgery involving 3 or more levels. *World Neurosurg.* 2018 Feb 21. pii: S1878-8750(18)30359-0. doi: 10.1016/j.wneu.2018.02.088.
 8. Katsuura Y, Lemons A, Lorenz E, Swafford R, Osborn J, Cason G. Radiographic analysis of cervical and spinal alignment in multilevel acdf with lordotic interbody device. *Int J Spine Surg* 2017; 11: 13.
 9. Kelly JC, Groarke PJ, Butler JS. The natural history and clinical syndromes of degenerative cervical spondylosis. *Adv Orthop* 2012; 2012: 393642.
 10. Kim JH, Park JY, Yi S, Kim KH, Kuh SU, Chin DK, Kim KS, Cho YE. Anterior cervical discectomy and fusion alters whole-spine sagittal alignment. *Yonsei Med J* 2015; 56(4): 1060-1070.
 11. Kwon WK, Kim PS, Ahn SY, Song JY, Kim JH, Park YK, Kwon TH, Moon HJ. Analysis of associating factors with c2-7 sagittal vertical axis after two-level anterior cervical fusion: comparison between plate augmentation and stand-alone cages. *Spine* 2017; 42(5): 318-325.
 12. Lee SH, Kim KT, Seo EM, Suk KS, Kwack YH, Son ES. The influence of thoracic inlet alignment on the craniocervical sagittal balance in asymptomatic adults. *J Spinal Disord Tech* 2012; 25: E41-E47.
 13. Louis R. Spinal stability as defined by the three-column spine concept. *Anat Clin* 1985; 7: 33-42.
 14. Özdoğan S, Köken M, Düzkalır HG, Düzkalır AH, Yaltrık CK, Öztürk E, Savrınlı EC, Civelek E, Kabataş S. Measurement of cervical lordosis with different methods. *JTSS* 2017; 28(1): 21-26.
 15. Scheer JK, Tang JA, Smith JS, Acosta FL Jr, Protopsaltis TS, Blondel B, Bess S, Shaffrey CI, Deviren V, Lafage V, Schwab F, Ames CP; International Spine Study Group. Cervical spine alignment, sagittal deformity, and clinical implications. *J Neurosurg Spine* 2013; 19(2): 141-159.
 16. Sevastikoglou JA, Bergquist E. Evaluation of the reliability of radiological methods for registration of scoliosis. *Acta Orthop Scand* 1969; 40: 608-613.