



ASSESSMENT OF CORRELATION BETWEEN GLOBAL SAGITTAL AXIS AND CLINICAL SCORES IN SPINAL DEFORMITY PATIENTS

Ömer BOZDUMAN¹,
Murat KÖKEN²

¹Afyonkarahisar State Hospital
Department of Orthopaedics and
Traumatology, Afyonkarahisar, Turkey.
²Ufuk University Faculty of Medicine
Department of Orthopaedics and
Traumatology, Ankara, Turkey.

ORCID Numbers:

- Ömer BOZDUMAN:
0000-0002-3874-633X
- Murat KÖKEN:
0000-0001-9180-0625

Address: Ömer BOZDUMAN,
Afyonkarahisar Devlet Hastanesi,
Ortopedi ve Travmatoloji Kliniği,
Afyonkarahisar Türkiye.
Mail: omerbozduman@gmail.com
Phone: +90 530 117 85 78
Received: 12th April, 2018.
Accepted: 24th June, 2018.

ABSTRACT

Objectives: Sagittal deformity requires higher energy to maintain an erect posture. Clinically, to be able to assess the severity of sagittal deformity and efficacy of compensatory mechanisms, new parameters are required. This study investigated the correlation between clinical relevance of global sagittal axis (GSA) and the severity of sagittal deformity.

Methods: In this study, retrospective review of patients who underwent full-body radiographs and clinical scoring systems which are Oswestry Disability Index (ODI), Scoliosis Research Society-22 and the visual analog scale for back and leg pain are integrated. The GSA is the angle between a line from the center of C-7 to midpoint of the femoral condyles, and a line from the posterior superior corner of the S-1 sacral endplate to midpoint between the femoral condyles. Correlation between clinical scoring systems and GSA data were compared.

Results: Eighty-four patients (mean age 46 years) were included. The GSA correlated significantly with all ODI, Scoliosis Research Society-22 and the visual analog scale for back and leg pain scores. Statistical analysis revealed that in sagittal deformity, the GSA increased with a concurrent increase in pelvic posterior translation (+0.186) and knee flexion (+0.284) and decrease in pelvic retroversion (-0.832)

Conclusions: The GSA is a practical and reliable measure to assess the sagittal deformity. The GSA correlated highly with clinical scores.

Key Words: Global Sagittal Axis; Sagittal deformity; Sagittal Alignment

Level of Evidence: Retrospective clinical study, Level III

INTRODUCTION

In spine patients, radiographic analysis of the sagittal plane is important for surgeon for determining the treatment. Jean Dubousset and his theory of the conusofeconomy is the basis of sagittal plane. According to Dubousset, the normal human posture assumes a stance limited to a narrow anterior-posterior range to minimize muscle exertion⁽³⁾. Following Dubousset's work, investigation of sagittal plane deformities in patients become more popular^(1,4,6). Studies have shown that in sagittal spinal deformity the loss of lumbar lordosis is common, and physiological and functional malalignment of spine is

seen⁽⁵⁾. However, other compensatory mechanisms is seen beyond spinal column⁽²⁾. Mechanisms such as thoracic hypokyphosis, hip extension (pelvic retroversion around the hip joint), and increased flexion of the knee and ankle are commonly recruited^(7,9). The combination of sagittal spinal deformity and pelvic/lower limb compensation results in an alignment in which the trunk is tilted anteriorly while the pelvis translates posterior to the gravity line⁽¹⁰⁾. The aim of this compensation is to keep the center of gravity over a narrow area between the feet⁽³⁾. There are multiple parameters to assess the severity of this deformity both radiographically and clinically.

Lafage et al⁽⁷⁾ found that if the compensatory mechanisms fail, the clinical impact of sagittal deformity worsens. They demonstrated that in patients who are failed to compensate by pelvic retroversion, patients become more disabled. Since, a full radiographic analysis is not made in those patients; other compensatory mechanisms are not clearly investigated.

In the aspect of developing radiological technologies, new parameters can be made in order to enlight the deformities. These parameters can enlight different types of compensatory mechanisms. In the daily routine, these patients can be easily screened by surgeon. This study investigated the clinical relevance of the global sagittal axis (GSA). The authors hypothesized that the GSA would significantly correlate with regional radiographic parameters along the full-body axis, as well as clinical outcome scores.

METHODS

Study Design

This retrospective review is prepared in a single center. Patients who have adult spinal deformity and who underwent full-body stereo radiography between 2012-2018 were integrated. Patients completed Oswestry Disability Index (ODI), Scoliosis Research Society-22 and the visual analog scale for back and leg pain questionnaires. Patients with fractures, infections, neuromuscular scoliosis, and malignancies were excluded.

Data collection and radiographic analysis

Patients data of age, sex, body mass index, and medical history and questionnaires: Oswestry Disability Index (ODI), Scoliosis Research Society-22 and visual analog scale (VAS) for back and leg pain.

Stereo radiographs were assessed using Clear Canvas. Radiographic parameters included, lumbar lordosis (LL), pelvic tilt (PT), pelvic incidence (PI), T-1 pelvic angle (TPA) and C7-S1 sagittal vertical axis (SVA). Lower- extremity radiographic parameters included ankle flexion angle, pelvic shift and knee flexion angle (KA). Cranio-cervical radiographic parameters included C2-7 SVA, chin-brow vertical angle (CBVA) and C2-7 cervical curvatures. GSA is the angle between a line from the center of C-7 to midpoint of the femoral condyles, and a line from the posterior superior corner of the S-1 sacral endplate to midpoint between the femoral condyles (Figure1,2).

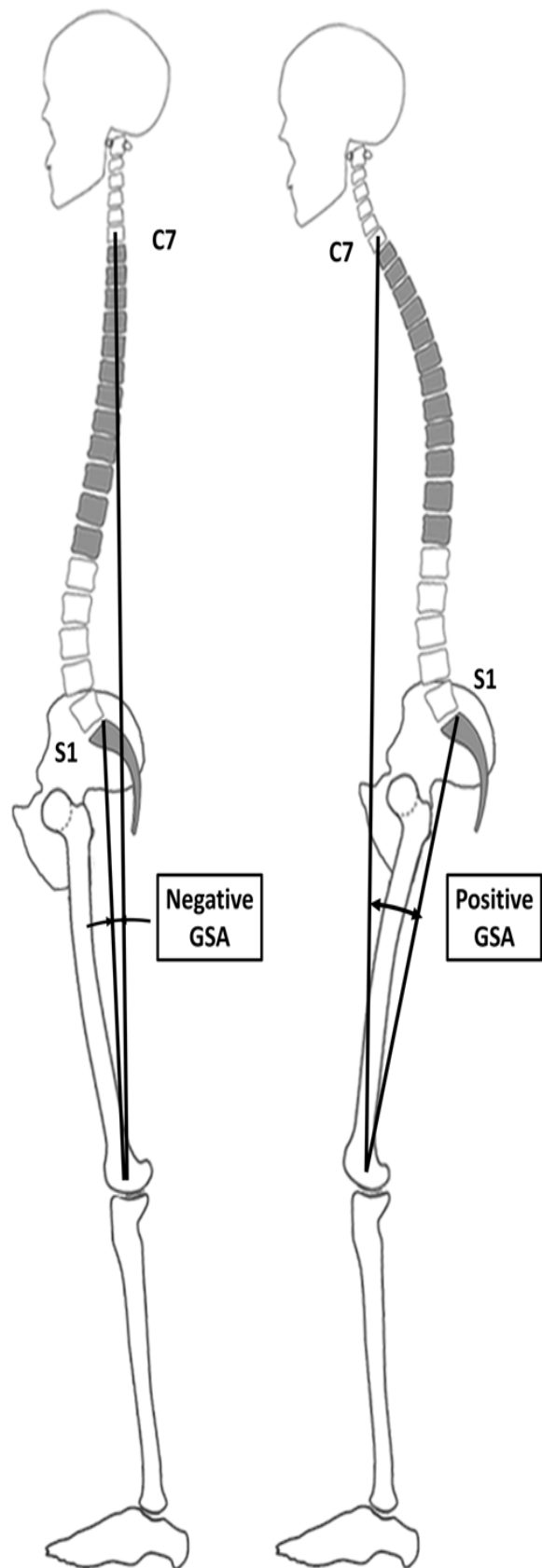


Figure-1. Showing the GSA: negative value (left) and positive value (right).

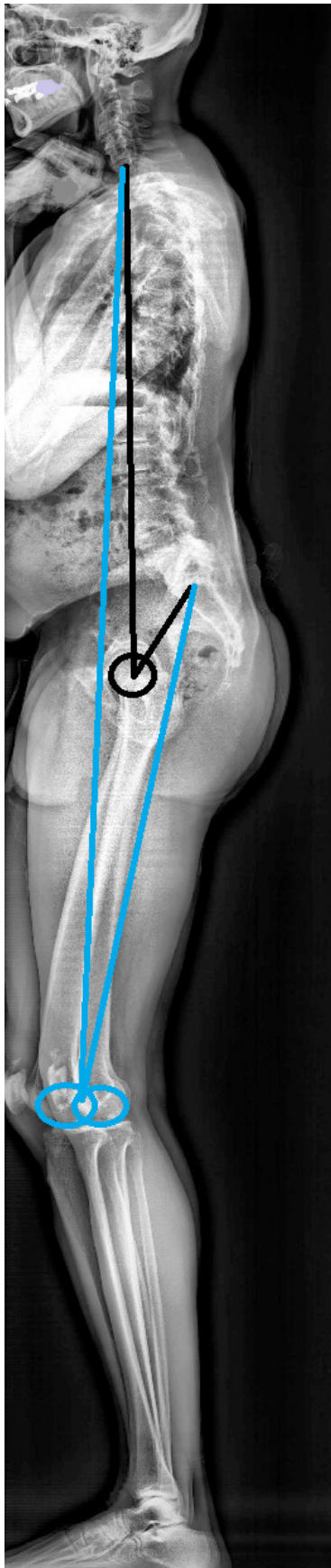


Figure-2. Example of measuring GSA on a radiograph

RESULTS

Eighty four patients met inclusion criteria, all have got degenerative lumbar scoliosis, progressive idiopathic scoliosis, orkyphoscoliosis. The mean age of the cohort was 46.1 ± 23.1 years; 26.8% of patients were younger than 45 years, 31% of patients were between 45 and 65 years, and 42.2% were older than 65 years. Seventy-six percent of patients were women, and the mean body mass index was 25.2 kg/m^2 . Seventy-five percent of patients had no history of spine surgery. Patients had the following mean scores: ODI 24.6 ± 22 , range 0–100; SRS22r 3.4 ± 0.6 , range 1.7–4.7; VAS back 4.6 ± 3.2 , range 0–10; and VAS leg 2.6 ± 3.4 , range 0–10.

Radiographic Measurements

The mean GSA was $0.7^\circ \pm 4.8^\circ$ (range -8.2° to 19.5°). The cohort had a mean PI of $54.6^\circ \pm 12.4^\circ$ (range 21.5° to 103.3°), a mean PI-LL of $4.6^\circ \pm 22.2^\circ$ (range -63.8° to 66.5°), a mean PT of $19.4^\circ \pm 13.6^\circ$ (range -34.1° to 50.0°), a mean TPA of $14.8^\circ \pm 14.6^\circ$ (range -30.4° to 50.8°), and a mean SVA of $17 \pm 56 \text{ mm}$ (range -71.2° to 200.4°). The mean values for lower-limb measurements were as follows: KA $3.2^\circ \pm 8.8^\circ$ (range -15.1° to 42.8°), ankle dorsiflexion $7^\circ \pm 4^\circ$ (range -2.8° to 23.3°), and pelvic posterior shift $1.4 \pm 42 \text{ mm}$ (range -109.8° to 117.9°). The cohort had the following mean values and ranges for cervical parameters: C2–7 cervical curvature $8.4^\circ \pm 24^\circ$ (range -35.7° to 146.2°), C2–7 SVA $16.8 \text{ mm} \pm 56.4 \text{ mm}$ (range -90.8° to 82.4°), and CBVA $6.8^\circ \pm 13.2^\circ$ (range -16.1° to 87.7°).

Correlation Analysis

The GSA significantly correlated with the classic SRS-Schwab spino pelvic sagittal modifiers (PI-LL, PT, and SVA), as well as lower-limb and cranio-cervical parameters. Correlation coefficients are reported in Table-1; all correlations were significant ($p < 0.05$) (Table-1).

The GSA significantly correlated with all scores (ODI, SRS22r, VAS leg pain scores). The GSA had better correlations with ODI, SRS22r, VAS leg pain scores than with any of the other radiographic parameters. Correlation coefficients are reported in Table-2 (Table-2).

Table-1. Correlation coefficients between GSA and full-body

Sagittal Radiographic Measure	GSA
PT	0.632
PI minus LL	0.778
TPA	0.854
SVA	0.952
KA	0.794
Ankle dorsiflexion	0.572
Pelvic posterior shift	0.880
C2–7 cervical curvature	0.328
C2–7 SVA	0.226
CBVA	-0.252

Sagittal radiographic parameters*

* All correlations were significant ($p < 0.05$).**Table-2.** Correlation coefficients between GSA, full-body sagittal radiographic parameters, and scores

Sagittal Radiographic Measure	ODI	SRS22r	VAS Back	VAS Leg
GSA	0.518	-0.545	0.368	0.450
PT	0.268	-0.262	—	0.208
PI minus LL	0.342	-0.346	0.258	0.342
TPA	0.394	-0.396	0.262	0.336
SVA	0.508	-0.534	0.398	0.448
KA	0.510	-0.512	0.336	0.378
Ankle dorsiflexion	0.486	-0.438	0.298	0.332
Pelvic posterior shift	0.394	-0.442	0.266	0.358

— = no-significant correlation.

* All correlations were significant ($p < 0.05$). The highest correlation coefficient

In each column is in bold face type.

DISCUSSION

This study presents sagittal spinopelvic radiographic parameters to measure GSA. Moreover, the GSA expands our understanding of the spine and pelvis to include the full-body axis. According to Diebo et al, the GSA is sensitive to spine, pelvic, and lower-extremity compensatory changes in the sagittal plane and holds one of the strongest correlations with patient-reported clinical scores reported in the literature (0.6 for EQ-5D). GSA reflects the deformity more accurately than previously defined spinopelvic parameters. GSA is important in patients whose pelvic retroversion compensatory mechanism is not enough and those who do not have the ability to compensate by pelvic retroversion.

Researchers tried to divide the sagittal plane into regions to evaluate musculoskeletal components^(6,7). Studies by both Dubousset and Duval-Beaupère et al. Highlighted the importance of incorporating the pelvis in the assessment of spinal malalignment⁽³⁻⁴⁾. Pelvis is the access region of trunk to lower extremities through the hip joint. With the assessment of full-body radiographs, the lower extremities have just begun to get investigated. Lower-extremity compensation via increased flexion of the knees and ankles and subsequent pelvic shift plays a significant role in attempts at sagittal realignment and is therefore the direct effect of a pathological spinal deformity^(2,8,9,10).

Assessing multiple radiographic analysis requires clinical and radiological experience. GSA is a simple method to investigate standing alignment and implied disability.

The simplicity of GSA offers it to be used in screening patients. Once the deformity is identified, more detailed traditional analysis would obviously be required to understand the etiology of the pathology as well as the surgical plan.

CONCLUSIONS

The GSA is a simple method for screening sagittal standing axis of the human body. The GSA is highly correlated with spinal, pelvic, and lower-extremity sagittal parameters and is compatible with clinical score to assess sagittal deformity. GSA also provides information for lower extremities and is able to enlight other pathologies rather than spine and pelvis. Moreover, the GSA is a strong indicator of patient disability and clinical scores. GSA is a simple method for communicating among physicians to address the deformity from cervical spine to ankle.

REFERENCES

1. Baek SW, Kim C, Chang H. The relationship between the spinopelvic balance and the incidence of adjacent vertebral fractures following percutaneous vertebroplasty. *Osteoporos Int* 2015; 26: 1507–1513.
2. Diebo BG, Ferrero E, Lafage R, Challier V, Liabaud B, Liu S, Vital JM, Errico TJ, Schwab FJ, Lafage V. Recruitment of compensatory mechanisms in sagittal spinal malalignment is age and regional deformity dependent: a full-standing axis analysis of key radiographical parameters. *Spine* 2015; 40: 642–649.
3. Dubousset J. Three-dimension analysis of the scoliotic deformity. In: Weinstein SL (ed). *The Pediatric Spine: Principles and Practices*. Raven Press, New York 1994; pp: 479–496.
4. Duval-Beaupère G, Schmidt C, Cosson P. A barycentric study of the sagittal shape of spine and pelvis: the conditions required for an economic standing position. *Ann Biomed Eng* 1992; 20: 451–462.
5. Farcy JP, Schwab FJ. Management of flat back and related kyphotic decompensation syndromes. *Spine* 1997; 22: 2452–2457.
6. Iida T, Suzuki N, Kono K, Ohya Y, Imura J, Ato A, Ozeki S, Nohara Y. Minimum 20 years long-term clinical outcome after spinal fusion and instrumentation for scoliosis. *Spine* 2015; 40: E922–E928.
7. Lafage V, Schwab F, Patel A, Hawkinson N, Farcy JP. Pelvic tilt and truncal inclination: two key radiographic parameters in the setting of adults with spinal deformity. *Spine* 2009; 34: E599–E606.
8. Lazennec JY, Charlot N, Gorin M, Roger B, Arafati N, Bissery A, Saillant G. Hip-spine relationship: a radio-anatomical study for optimization in acetabular cup positioning. *Surg Radiol Anat* 2004; 26(2): 136–144.
9. Obeid I, Hauger O, Aunoble S, Bourghli A, Pellet N, Vital JM. Global analysis of sagittal spinal alignment in major deformities: correlation between lack of lumbar lordosis and flexion of the knee. *Eur Spine J* 2011; 20 (Suppl.-5): 681–685.
10. Schwab F, Lafage V, Boyce R, Skalli W, Farcy JP. Gravity line analysis in adult volunteers: age-related correlation with spinal parameters, pelvic parameters, and foot position. *Spine* 2006; 31: E959–E967.