



CLINICAL OUTCOMES OF THE PATIENTS WHO UNDERWENT SURGERY FOR CEREBRAL PALSY SCOLIOSIS

Ali GÜLEÇ¹,
Sadettin ÇİFTÇİ¹,
Egemen ODABAŞI¹,
Ahmet YILDIRIM¹

¹ Department of Orthopaedics and Traumatology, Selçuk University Faculty of Medicine, 42030, Konya, Turkey.

ORCID Numbers:

- Ali GÜLEÇ:
0000-0001-8265-825X
- Saadettin ÇİFTÇİ:
0000-0003-3249-3420
- Egemen ODABAŞI:
000-0003-0160-8504
- Ahmet YILDIRIM:
0000-0002-3953-091X

Address: Department of Orthopaedics and Traumatology, Selçuk University Faculty of Medicine, 42030, Konya, Turkey.

Phone: +90 530 828 07 75

E-Mail: drag42@gmail.com

Received: 12th April, 2018.

Accepted: 17th June, 2018.

ABSTRACT

Introduction: Static encephalopathy developing linked to damage occurring in the immature brain for any reason is called cerebral palsy (CP). As CP patients have abnormal muscle tonus and linked posture disorders, scoliosis is frequently encountered. In this article, we retrospectively investigated CP scoliosis cases operated at our clinic and complications.

Material and Method: Thirteen patients with surgical treatment at our clinic from 2011-2017 for CP scoliosis were retrospectively investigated. The surgical techniques, improvement rates, perioperative complications and long-term motor function changes (GMFCS) were assessed.

Results: Nine males and 4 females were operated. Mean age was 14.3 years (range: 5-21), and mean Cobb angle was 79.3 (range: 45-135). The improvement amount in the Cobb angle was assessed as 48.2 (range: 20-70). Preoperative GMFCS score was 5 for 7 patients, 4 for 5 patients and 3 for 1 patient. One patient developed paraplegia in the 12th hour after correction (this patient was exitus in the postop 6th month due to later developing pulmonary complications). One patient developed urinary incontinence. Infection was not identified in any patient. One patient had level increased due to development of kyphosis in proximal neighboring segment.

Conclusion: We believe encouraging improvements can be obtained with posterior instrumentation and fusion surgery in CP scoliosis patients minimizing complications including coronal balance, sagittal balance and pelvic obliquity and there is no major disadvantage compared to the unit rod instrumentation system.

Key words: Cerebral palsy, pelvic obliquity, surgical treatment, instrumentation.

Level of Evidence: Retrospective clinical study, Level III.

INTRODUCTION

Development of static encephalopathy linked to damage occurring in the immature brain is called cerebral palsy (22). The most commonly-observed form is quadriplegic spastic CP. The most common risk factor is asphyxia (14). Due to spasticity developing linked to the disease, changes occur first in muscles and later in bone and joint structures. Scoliosis is one of the problems developing linked to cerebral palsy with the disease encountered at different rates according to form (11,18-19).

The scoliosis incidence developing in CP patients is associated with age and GM-FCS (7). It is reported there is an inverse correlation between the 35 scoliosis problem developing in cerebral palsy and ambulation potential (11,20). Patients with hip dislocation, early-onset scoliosis and Cobb degree of 30 before 10 years of age are high risk patients for progression (28). Scoliosis patients with CP may have nutrition and mobilization affected linked to deformity and hygiene may be disrupted (8,13). At the same time, deformity affects lung capacity and cardiac problems may occur. Pelvic

obliquity occurring may disrupt seated balance and make mobilization with a wheelchair impossible ^(8,12). Though the use of a brace may correct this situation slightly, it will not be possible to correct the deformity or stop the progression ⁽¹³⁾. Due to problems like the rapid progression of deformity and this situation making treatment more difficult in these patients, surgical treatment is required in the early period ⁽²²⁾.

Surgical treatment of scoliosis occurring in CP patients ensures significant improvement in quality of life ⁽¹⁵⁾. The aim of this article is to investigate all aspects of CP scoliosis cases treated in our clinic to examine treatment outcomes in light of the literature.

MATERIAL AND METHOD

Ethical permission was obtained from Selçuk University Faculty of Medicine Non Interventional Clinical Research ethics committee.

Thirteen patients operated for CP scoliosis from 2011 to 2017 were retrospectively investigated. Patients with scoliosis linked to CP and with follow-up for at least 6 months postoperative were included in the study. As all 13 patients met the inclusion criteria they were all included in the study.

Patient medical records were investigated for age, sex, ambulation potential, mental status, level according to gross motor functional classification system (GM-FCS), diseases or medical states accompanying CP (gastrointestinal pathologies or gastrostomy tube, cardiopulmonary pathologies, skeletal system pathologies requiring additional surgical intervention). GM-FCS assessment was performed as adapted and recommended by *Palisano et al.* ⁽¹⁷⁾.

The duration of hospitalization, necessity for intensive care, additional surgical intervention requirements, and amounts of blood product replacements were checked from the records. The complications were divided into three groups as intraoperative, early postoperative (within 3 months) and late postoperative (after 3 months) ⁽²²⁾.

Radiography was taken while standing if possible, or sitting if necessary, with AP and lateral investigations. Cobb angle, thoracic kyphosis angle and lumbar lordosis angle were measured with the Cobb method and recorded. The study by *Shrader et al.* determined the most reliable technique in terms of intraobserver and interobserver assessment was the Maloney method for measurement of pelvic obliquity, so in our study the Maloney method was used for measurements taking *Shrader et al.* as reference ^(16, 21). With this technique, the angle between the line determined perpendicular to the horizontal line joining the iliac crests and the line drawn between T1 and S1 is measured ⁽²¹⁾ (Figure-1).

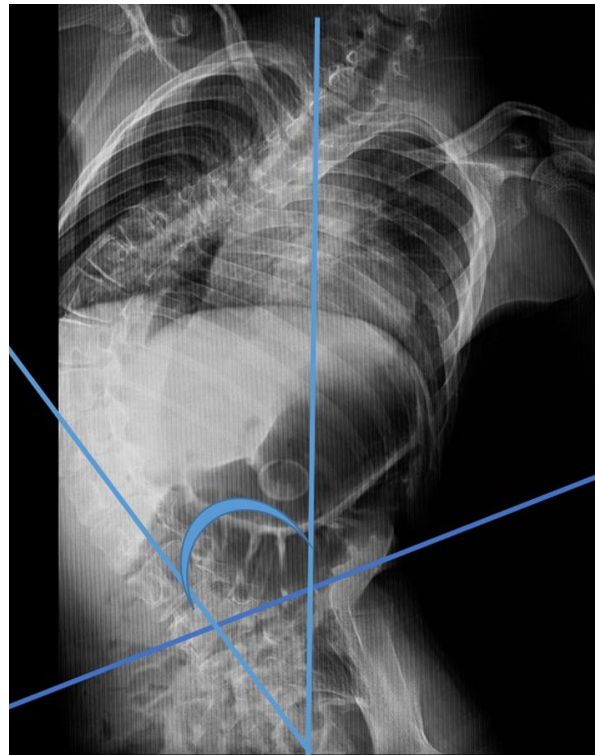


Figure-1. Measurement of pelvic obliquity by Maloney's method

Demographic Data:

Thirteen patients (9 male, 4 female) abiding by the inclusion criteria were included in the study. All patients were quadriplegic CP patients. When GMFCS is assessed, 5 patients were level-4, 7 patients were level-5 and 1 patient was level-3. Eleven children were determined to have severe mental retardation with the remaining two having moderate degree of mental retardation. Mean age was 14.3 years (range: 5-21). Mean follow-up duration was 31.8 months (range: 6-74).

Curvature and Surgical Properties:

All patients had single major curvature. Mean fusion level was 14.6 (range: 14-17). The distribution of the apex of curvature was thoracic (T) in 8 patients, thoracolumbar (TL) in 4 patients and lumbar (L) in 1 patient. Instrumentation was sufficient from L4-T5 with no pelvic fusion in 2 patients, while 5 of the remaining 11 patients had pelvis to T2, 2 patients had pelvis to T4, 1 patient had to T5, 1 patient to T8, 1 patient to T3 and 1 patient to T1. No patient required cervical instrumentation.

All patients only had posterior instrumentation applied. The erythrocyte suspension (ES) replacement amounts, hospitalization stay and blood loss amounts were investigated (Table-1).

The apex curvature was determined for thoracic, thoracolumbar and lumbar regions as described by Lenke⁹⁾. All measurements were taken by the same person.

When determining the surgical indications for patients, solid curvature without correction or slowing possible with orthotic treatment above 40 degrees were determined. All patients had posterior instrumentation and fusion applied with pedicle screw and rod system.

Table-1. Demographic data and surgery

AGE	SEX	GMFCS	FIXATION	ILIAC FUSION
12	M	4	T1 -L5	YES
17	F	5	T2-L5	YES
14	M	5	T2-L4	YES
13	M	5	T3-L4	YES
17	F	4	T4-L5	NO
15	M	5	T2-L5	YES
5	M	4	T2-L5	YES
15	M	5	T2-L5	YES
15	M	4	T5-L5	YES
19	M	5	T8-S1	YES
12	F	3	T4-L5	YES
12	F	4	T4-L5	NO
21	M	5	T4-S1	YES

RESULTS

Preoperative mean Cobb angle was 79.3° (range: 65° (range: 20°-70°) (Figure-2).

Preoperative kyphosis angle was mean 31.9° (range: 0°-90°), while postoperative kyphosis angle was mean 38.4° (range: 15°-70°) (Table-2).

There were 6 major complications; 1 patient developed pneumothorax, 1 patient had paraplegia, 2 patients had pneumonia, 1 patient had urinary incontinence and 1 patient had junctional kyphosis in the postoperative 1st year. One patient was identified to have L5-S1 irritation on the neuromonitor intraoperatively; however no postoperative problem developed. Pneumothorax was treated with closed underwater drainage system in intensive care.

Paraplegia developed during neurological examination in intensive care in the 12th hour postoperative. Steroid treatment was begun. However, with no improvement in neurologic status and progression developing, the patient was re-operated 3 hours later with rods removed and correction canceled. There was still no improvement in neurologic deficit.

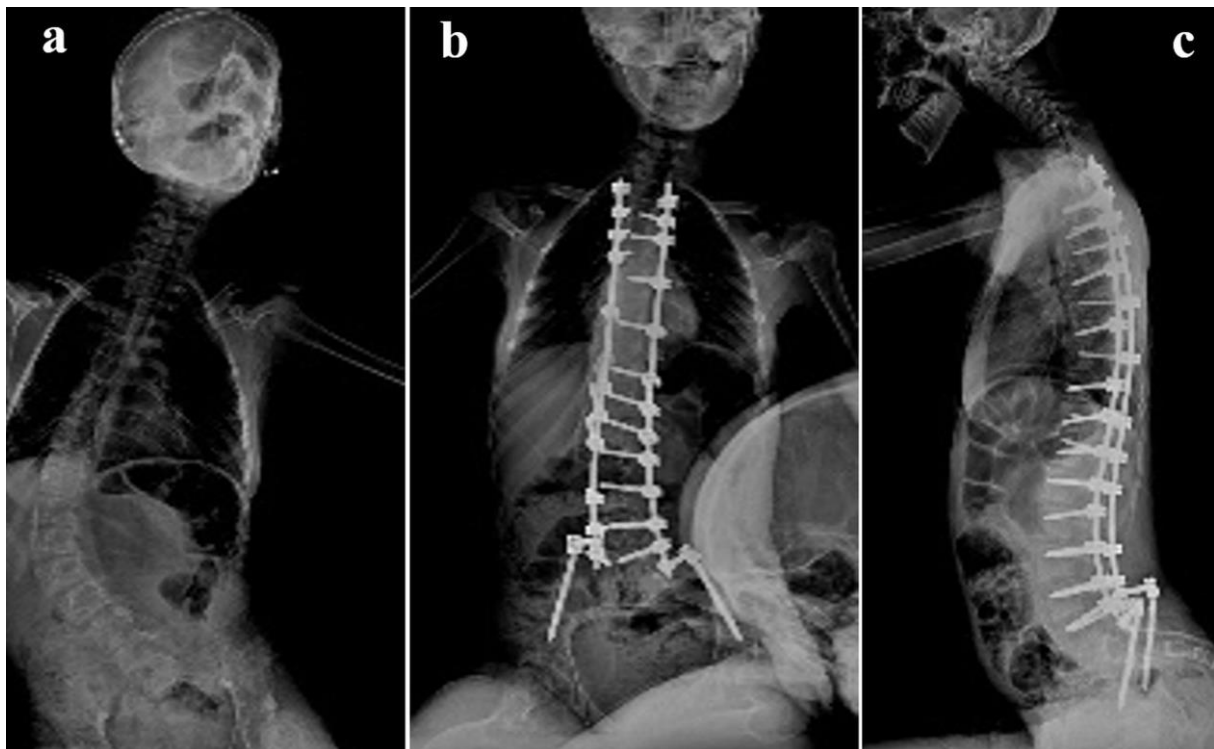


Figure-2.a, b, c. Pre- post operative X-rays.

Patients developing pneumonia were treated with antibiotherapy. The patient developing junctional kyphosis proximal to T4 had revision surgery applied and instrumentation was added to 2 levels above. Urinary incontinence had fully resolved by the 6th month postoperative. No patient developed surface or deep infection (Table-3).

The patient developing postoperative paraplegia was exitus after aspiration pneumonia developed in the 6th month postoperative. No other case developed mortality during follow-up.

Table-2. Blood variations and intensive care duration

PREOP HB	POST HB	ES REP.	IC DURATION
14	9.5	3	5 DAYS
13	9.4	4	3 DAYS
13.6	9.2	4	2 DAYS
13.2	8.5	15	35 DAYS
13	9.5	6	2 DAYS
16	9.5	8	14 DAYS
11	9.5	2	NONE
14	10	5	3 DAYS
13	10	5	NONE
12	9.5	4	1 DAYS
15	9.5	2	2 DAYS
16	10	2	NONE
15	10	7	2 DAYS

Table-3. Correction rates

PREOP COBB	POSTOP COBB	PREOP KYF	POST KYF	PELV OB PRE	PELV OB PST
65	0	70	70	15	5
67	20	36	25	15	0
50	15	15	40	15	5
100	60	10	15	20	5
70	35	70	45	0	0
130	40	90	45	45	5
50	30	45	45	30	15
100	45	35	45	35	10
70	30	30	30	20	5
70	30	45	45	20	5
80	10	0	20	15	0
45	10	30	30	5	0
135	80	45	45	45	10

Table-4. Complications

GMFCS	PULMON.	INFECT	JUNC KYF	iMP FAIL
4	NONE	NONE	T4	NONE
5	NONE	NONE	NONE	NONE
5	NONE	NONE	NONE	NONE
5	NONE	Pneumonia	NONE	NONE
4	NONE	NONE	NONE	NONE
5	Pneumothorax	Pneumonia	NONE	NONE
4	NONE	NONE	NONE	NONE
5	NONE	NONE	NONE	NONE
4	NONE	NONE	NONE	NONE
5	NONE	NONE	NONE	NONE
3	NONE	NONE	NONE	NONE
4	NONE	NONE	NONE	NONE
5	NONE	NONE	NONE	NONE

DISCUSSION

Nearly all scoliosis CP patients develop deformity, with progression especially rapid during the growing period (2-3,11,13,20,22). Additionally, the majority of CP patients have additional problems like mental retardation, gastrointestinal system problems and nutritional disorders. In the patient series of *Sitoula et al.*, 97 % had serious additional problems with 27 % having tracheostomy. In the same series, 94 % of patients were severely mentally retarded and 88 % had gastrostomy (22). Another study reported high rates of mental retardation and rates of additional disease up to 100 % (5). In our study, all patients had quadriplegic CP. Of patients, 84 % had advanced degree of mental retardation, while the remainder had moderate degree of mental retardation.

Posterior instrumentation and the unit-rod system are known to provide successful and permanent improvement in Cobb angle, sagittal balance and pelvic obliquity, necessary for sitting balance (4,22,25,27). However, no matter how much improvement comes from successful interventions, it is reported pelvic obliquity may be disrupted (27). In our cases, correction was only applied with pedicle screws and posterior instrumentation with double rods, without any additional intervention (anterior approach, etc.), and improvement rates of 40-100 % were achieved for Cobb angle.

Sitoula et al. identified nearly 75 % improvement in their series and stated there was a 3 degree improvement loss; however, they did not identify Cranchaft phenomenon (22). Pelvic obliquity improved from 25° preoperative to 3° in the early postoperative period in the series by *Dias et al.* and 4° was determined during follow-up (4). *Lonstein et al.* in a case series identified that the pelvic obliquity with mean 15° degrees in the preoperative period was 8° during postoperative follow-up and mean 40 % improvement was present (10).

Bekmez et al. in a group with multiple osteotomy applied to the posterior column identified mean postoperative pelvic obliquity was 12° and they reported better improvement of pelvic obliquity was obtained with pedicle subtraction osteotomy (1). In our cases, pelvic obliquity of mean 21.5° (range: 0-45) was found to be mean 5° (range: 0°-15°) in the postoperative period.

In broad case-series studies, deep wound infection rates are reported at rates of 1.1 % to 6%. In the same series, surface wound infection rates are reported to reach 10 % (10,23-24). None of our cases developed deep or surface wound infection. However, as our case numbers were limited in a true sense, there is a clear need for data from broader series. In CP scoliosis cases, ambulation potential and neurologic status are the two basic factors proven to be associated with mortality. This risk is greater for quadriplegic patients, with serious mortality

rates of 1/4 to 1/8 of patients. However, some of these deaths occur in the perioperative period (6,25). In our cases, mortality was developed in a patient due to complications in the 6th month postoperative. When cases are looked at from a broad angle, apart from the junctional kyphosis in a patient and mortality in a patient, all the other complications appeared to develop in the early postoperative period. The 2 major complications of mortality and junctional kyphosis occurred during follow-up in the late postoperative period. Our limited number of patients and retrospective data are the basic limitations of our study in terms of reliability.

We believe encouraging improvements can be obtained with posterior instrumentation and fusion surgery in CP scoliosis patients minimizing complications including coronal balance, sagittal balance and pelvic obliquity. When assessed together with the literature, there is a need for larger patient series but no major disadvantage of the pedicle screw and double rod instrumentation technique was found compared to the unit-rod instrumentation technique.

REFERENCES

1. Bekmez S, Ozhan M, Olgun ZD, Suzer A, Ayvaz M, Demirkiran HG, Karağaoglu E, Yazici M. Pedicle subtraction osteotomy versus multiple posterior column osteotomies in severe and rigid neuromuscular scoliosis. *Spine* 2017; Dec 29. doi: 10.1097 / BRS. 0000 0000 0000 2538. [Epub ahead of print].
2. Bell D, Moseley C, Koreska J. Unit rod segmental spinal instrumentation in the management of patients with progressive neuromuscular spinal deformity. *Spine* 1989; 14(12): 1301-1307.
3. Berven S, Bradford D S. Neuromuscular scoliosis: causes of deformity and principles for evaluation and management. *Semin Neurol* 2002; 175.
4. Dias RC, Miller F, Dabney K, Lipton G, Temple T. Surgical correction of spinal deformity using a unit rod in children with cerebral palsy. *J Ped Orthop* 1996; 16(6): 734-740.
5. Edebol-Tysk K, Hagberg B, Hagberg G. Epidemiology of spastic tetraplegic cerebral palsy in Sweden-II. Prevalence, birth data and origin. *Neuropediatrics* 1989; 20(01): 46-52.
6. Evans P, Evans S, Alberman E. Cerebral palsy: why we must plan for survival. *Arch Dis Childhood* 1990; 65(12): 1329-1333.
7. Hägglund G, Pettersson K, Czuba T, Persson-Bunke M, Rodby-Bousquet E. Incidence of scoliosis in cerebral palsy: A population-based study of 962 young individuals. *Acta Orthop Scand* 2018; 1-5. doi: 10.1080/17453674.2018.1450091. [Epub ahead of print].
8. Kalen V, Conklin MM, Sherman FC. Untreated scoliosis in severe cerebral palsy. *J Ped Orthop* 1992; 12(3): 337-340.
9. Lenke LG, Betz RR, Harms J, Bridwell KH, Clements DH, Lowe TG, Blanke K. Adolescent idiopathic scoliosis: a new classification to determine extent of spinal arthrodesis. *J Bone Joint Surg* 2001; 83(8), 1169-1181.

10. Lonstein JE, Koop SE, Novachek TF, Perra JH. Results and complications after spinal fusion for neuromuscular scoliosis in cerebral palsy and static encephalopathy using Luque-Galveston instrumentation: experience in 93 patients. *Spine* 2012; 37(7): 583-591.
11. Madigan RR, Wallace SL. Scoliosis in the institutionalized cerebral palsy population. *Spine* 1981; 6(6): 583-590.
12. Majd ME, Muldowny DS, Holt RT. Natural history of scoliosis in the institutionalized adult cerebral palsy population. *Spine* 1997; 22(13): 1461-1466.
13. Miller A, Temple T, Miller F. Impact of orthoses on the rate of scoliosis progression in children with cerebral palsy. *J Ped Orthop* 1996; 16(3): 332-335.
14. Minocha P, Sitaraman S, Sachdeva P. Clinical spectrum, comorbidities, and risk factor profile of cerebral palsy children: A prospective study. *J Ped Neurosciences* 2017; 12(1): 15.
15. Miyajiri F, Nasto LA, Sponseller PD, Shah SA, Samdani AF, Lonner B, Newton PO. Assessing the risk-benefit ratio of scoliosis surgery in cerebral palsy: surgery is worth it. *J Bone Joint Surg* 2018; 100(7): 556-563.
16. Osebold WR, Mayfield JK, Winter R, Moe J. Surgical treatment of paralytic scoliosis associated with myelomeningocele. *J Bone Joint Surg* 1982; 64-A(6): 841-856.
17. Palisano RJ, Rosenbaum P, Bartlett D, Livingston MH. Content validity of the expanded and revised gross motor function classification system. *Dev Med Child Neurol* 2008; 50(10): 744-750.
18. Persson-Bunke M, Häggglund G, Lauge-Pedersen H, Wagner P, Westbom L. Scoliosis in a total population of children with cerebral palsy. *Spine* 2012; 37(12): E708-E713.
19. Porter D, Michael S, Kirkwood C. Is there a relationship between preferred posture and positioning in early life and the direction of subsequent asymmetrical postural deformity in non ambulant people with cerebral palsy? *Child Care Health Dev* 2008; 34(5), 635-641.
20. Saito N, Ebara S, Ohotsuka K, Kumeta H, Takaoka K. Natural history of scoliosis in spastic cerebral palsy. *Lancet* 1998; 351(9117): 1687-1692.
21. Shrader MW, Andrisevic EM, Belthur MV, White GR, Boan C, Wood W. Inter-and intra-observer reliability of pelvic obliquity measurement methods in patients with cerebral palsy. *Spine Deformity* 2018; 6(3): 257-262.
22. Sitoula P, Holmes Jr L, Sees J, Rogers K, Dabney K, Miller F. The long term outcome of early spine fusion for scoliosis in children with cerebral palsy. *Clin Spine Surg* 2016; 29(8): E406-E412.
23. Sponseller PD, Shah SA, Abel MF, Newton PO, Letko L, Marks M. Infection rate after spine surgery in cerebral palsy is high and impairs results: multicenter analysis of risk factors and treatment. *Clin Orthop Rel Res* 2010; 468(3): 711-716.
24. Szöke G, Lipton G, Miller F, Dabney K. Wound infection after spinal fusion in children with cerebral palsy. *J Ped Orthop* 1998; 18(6): 727- 733.
25. Tsirikos AI, Chang W-N, Dabney KW, Miller F, Glutting J. Life expectancy in pediatric patients with cerebral palsy and neuromuscular scoliosis who underwent spinal fusion. *Dev Med Child Neurol* 2003; 45(10), 677-682.
26. Tsirikos AI, Lipton G, Chang W-N, Dabney KW, Miller F. Surgical correction of scoliosis in pediatric patients with cerebral palsy using the unit rod instrumentation. *Spine* 2008; 33(10): 1133-1140.
27. Watanabe K, Lenke LG, Daubs MD, Watanabe K, Bridwell KH, Stobbs G, Hensley M. Is spine deformity surgery in patients with spastic cerebral palsy truly beneficial? A patient/parent evaluation. *Spine* 2009; 34(20): 2222-2232.
28. Yoshida K, Kajiura I, Suzuki T, Kawabata H. Natural history of scoliosis in cerebral palsy and risk factors for progression of scoliosis. *J Orthop Sci* 2018; Apr 25. pii: S0949-2658(18)30098-8. doi: 10.1016/j.jos.2018.03.009. [Epub ahead of print]