



COMPLEX REGIONAL PAIN SYNDROME FOLLOWING CARPAL TUNNEL SURGERY

Recep BASARAN¹,
Basak CANER¹,
Mustafa EFENDIOGLU¹,
Aslihan CEVIK¹

¹Medical Sciences University Sancaktepe Education and Research Hospital, Department of Neurosurgery, Istanbul, Turkey.

ORCID Numbers:

Recep Başaran:

<https://orcid.org/0000-0001-5186-1116>

Aslihan Çevik:

<https://orcid.org/0000-0001-6103-0527>

Mustafa Efendioğlu:

<https://orcid.org/0000-0003-3663-047X>

Başak Caner:

<https://orcid.org/0000-0002-8706-0430>

Address: Recep Basaran, Sancaktepe Eğitim ve Araştırma Hastanesi, Emek mah. Namık Kemal Cad. 34785, Istanbul, Turkey
E-mail: drecepbasaran@gmail.com
Phone: +90 506 659 72 21
Fax: +90 216 359 73 61
Received: 10th June, 2018.
Accepted: 22th August, 2018.

ABSTRACT

Complex regional pain syndrome (CRPS) is a chronic neurological condition involving the limbs that is characterized by severe pain along with sensory, autonomic, motor and trophic impairment. This condition may be induced by surgery, trauma or minor injury. This condition can complicate recovery and impair one's functional and psychological well-being.

Here, we presented 2 cases as 66 and 52 years old two female patients. They were suffering for 2 years from hypoesthesia and pain on her right hand at the area of median nerve. On neurological examinations, thenar atrophy, positive on tinnel and phallen tests were detected. On EMG, severe carpal tunnel syndrome is detected. Patients were operated under local anesthesia and median nerve was decompressed. 3 days in first patient and 1 week in second after surgery, patients' hands were swollen and symptoms of pain, hypoesthesia and burning sensation were appeared. We detected prominent edema on their hands starting from the wrist area. They were diagnosed as 'complex regional pain syndrome'. They were treated with steroid, NSAID, antidepressant and physical therapy. There was no rheumatological pathology. There is amelioration at their symptoms 1 month follow-up. In conclusion; given the complex nature of this syndrome, it is unlikely that targeting a specific mechanism will be effective. As with other chronic disorders, the future of CRPS treatment may lie in combination therapy and studies investigating this will be necessary.

Key words: carpal tunnel syndrome; complex regional pain syndrome; surgery; complication; painful; swollen hand.

Level of Evidence: Case report, Level IV.

INTRODUCTION

Carpal tunnel syndrome (CTS) is the commonest entrapment neuropathy and is due to combined compression and traction on the median nerve at the wrist. It was first described by James Paget in 1853. In 1913, Marie and Foix published the first description of a neuroma proximal to the flexor retinaculum (FR). The first surgical release of the FR is attributed to Galloway in 1924 ⁽¹⁾. The prevalence of CTS is estimated between 4 and 5 % of the population especially between ages 40 and 60 ⁽²⁾.

In most cases, CTS is said to be idiopathic. It occurs most often in women (65 to 80 % of cases) between 40 and 60 years, bilateral in 50 % to 60 % of cases ⁽¹¹⁾. Bilateralism increases with the duration

of symptoms. It is related to a fibrous hypertrophy of synovial flexor sheath related to connective tissue degeneration with vascular sclerosis, synovial edema and collagen fragmentation ⁽¹²⁾. Meta-analyses ⁽⁸⁾ showed that sex, age, genetic and anthropometric factors (size of the carpal tunnel) are the most important predisposing factors. Repetitive manual work, exposure to vibration, and cold exposure are minor predisposing factors. Other minor predisposing factors have been identified such as obesity and tobacco. Secondary CTS may be related to abnormalities of the container or the contents. Dynamic CTS is frequently encountered in occupational pathology. CTS were diagnosed by examination, provocative tests, associated pathology and differential diagnosis. Additional

tests especially electroneuromyography examination (ENMG) is important.

The principle of surgical treatment is to obtain a reduction in intracanalicular pressure by increasing the volume of the carpal tunnel due to the section of the FR. In most cases, the outcome is good with disappearance of pain crises and nocturnal paresthesia's immediately postoperative.

Complex regional pain syndrome (CRPS) is defined as a disorder of the extremities characterized by regional pain that is disproportionate in time or degree to the usual course of any known trauma or other lesion ⁽⁶⁾. CRPS can be classified into two types: CRPS types-I and II that are characterized by the absence or presence of identifiable nerve injury. CRPS type-I is a syndrome that usually develops after an initiating noxious event, is not limited to the distribution of a single peripheral nerve, and is disproportionate to the inciting event. It is associated with edema, changes in skin blood flow, abnormal sudomotor activity in the region of the pain, allodynia and hyperalgesia and commonly involves the distal aspect of the affected extremity or with a distal to proximal gradient. CRPS type II can be defined as a burning pain, allodynia and hyperpathia occurring in a region of the limb after partial injury of a nerve or one of its major branches innervating that region.

We present two cases of complex regional pain syndrome following carpal tunnel syndrome surgery without nerve injury.

Case Report

66 and 52 years old two female patients without any history of diseases, operation or trauma were suffering for 2 years from hypoesthesia and pain on her right hand at the area of median nerve. On neurological examinations, thenar atrophy, positive on tinnel and phallen tests were detected. On EMG, severe carpal tunnel syndrome was detected. Patients were operated under local anesthesia and median nerve was decompressed. Median nerve was released both in the proximal and distal areas. Three days in first patient and 1 week in second patient after surgery, patients' hands were swollen and symptoms of pain, hypoesthesia and burning sensation appeared. We detected prominent edema on their hands starting from the wrist area (Figure-1).

They were diagnosed as 'complex regional pain syndrome'. They were treated with prednisolone, NSAID, antidepressant and physical therapy. There was no rheumatological pathology. There is amelioration at her symptoms 1 month follow-up.

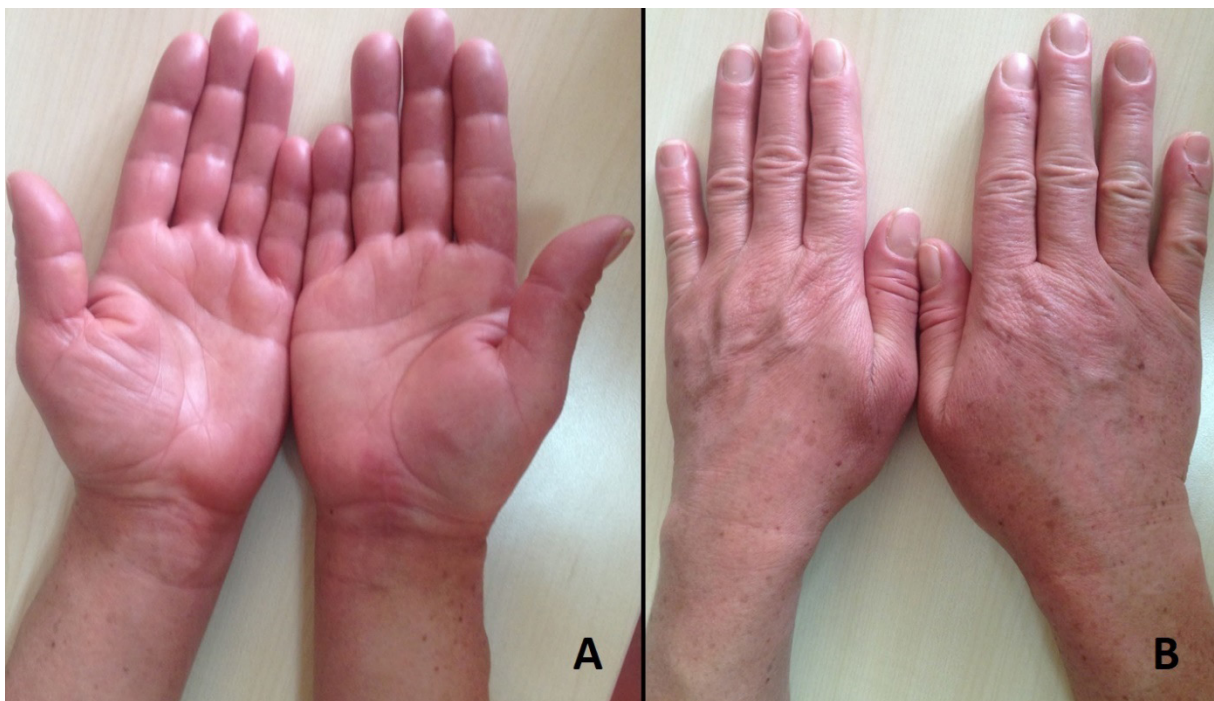


Figure-1. Anterior (A) and posterior (B) aspect of both hands. We detected prominent edema on operated hand starting from the wrist area according to another hand.

DISCUSSION

Prophylaxis for treatment is essential in occupational pathology and includes the modification of the workplace and tools. Other non-surgical treatment choices are conservative treatment with corticosteroid injection, night splint in neutral wrist position, modification of mechanical and ergonomic measures. The principle of surgical treatment is to obtain a reduction in intracanalicular pressure by increasing the volume of the carpal tunnel due to the section of the FR. The operation is usually unilateral.

Three techniques are currently used: open; techniques known as “mini-open”; and endoscopic techniques. Whatever the technique, the procedure must be atraumatic and care must be taken not to place the median nerve in the extension of the scar incision to minimize postoperative epineural adhesions. In most cases, the outcome is good with disappearance of pain crises and nocturnal paresthesias immediately postoperative. Turner et al. ⁽¹⁴⁾ concluded that the worst results were observed in case of: diabetes mellitus including polyneuropathy and impaired general condition; alcohol and tobacco; normal preoperative ENMG; occupational disease; thenar atrophy; multiple nerve compression; length of symptoms. Complication of surgery can be divided into minor and major complications. Minor complications are neuropathic scar pain, pillar pain, complex regional pain syndrome type 1 and instability of ulnar flexor tendons through the cut FR. Major complications are rare but serious. Benson et al. ⁽³⁾ reported 0.49 % serious complications for open surgery and 0.19 % for endoscopic surgery. These are nerve complications, injury to the superficial palmar arch, and section of the flexor tendons of the fingers.

CRPS is a clinical diagnosis made based on the findings during the history and physical examination of the patient, for which diagnostic criteria including the Orlando Criteria for Complex Regional Pain Syndrome and The Budapest Clinical Diagnostic Criteria for Complex Regional Pain Syndrome by the International Association for the Study of Pain (IASP) have been developed ⁽¹⁰⁾. The incidence rate of CRPS type I was 5.46 per 100000 person/years, and the incidence rate of CRPS type-II was 0.82 per 100000 person-years, giving rise to a combined incidence rate for both CRPS types-I and II of 6.28 per 100000 person-years ⁽⁵⁾. The incidence of CRPS in carpal tunnel syndrome was ranged between 1.9-5 % ^(7,9,13).

Management of CRPS-I continues to be a therapeutic challenge. Several treatment protocols using various opioid analgesics, antipsychotics, antidepressants and anti-inflammatory agents have been carried out with the goal of treating CRPS-I ⁽⁴⁾. Physical and occupational therapy is a key component of the rehabilitation process in patients with CRPS and is recommended as the first-line treatment. Interventional treatments are used for more

serious CRPS. These are sympathetic blocks, medullary stimulation and psychological pain management ⁽⁴⁾.

Conclusion

Given the complex nature of this syndrome, it is unlikely that targeting a specific mechanism will be effective. As with other chronic disorders, the future of CRPS treatment may lie in combination therapy and studies investigating this will be necessary.

Disclosure of interest:

The authors declare that they have no conflicts of interest concerning this article.

REFERENCES

1. Amadio PC. The first carpal tunnel release? *J Hand Surg (British & European Volume)* 1995; 20: 40-41.
2. Atroshi I, Gummesson C, Johnsson R, Ornstein E, Ransam J, Rosén I. Prevalence of carpal tunnel syndrome in a general population. *JAMA* 1999; 282: 153-158
3. Benson LS, Bare AA, Nagle DJ, Harder VS, Williams CS, Visotsky JL. Complications of endoscopic and open carpal tunnel release. *Arthroscopy: J Arthroscopic Rel Surg* 2006; 22: 919-924. e912
4. Gay A-M, Béréni N, Legré R. Type I complex regional pain syndrome. *Chirurgie Main* 2013; 32: 269-280.
5. Goh EL, Chidambaram S, Ma D. Complex regional pain syndrome: a recent update. *Burns Trauma* 2017; 5: 2.
6. Harden RN, Bruehl S, Perez RS, Birklein F, Marinus J, Maihofner C, et al. Validation of proposed diagnostic criteria (the “Budapest Criteria”) for complex regional pain syndrome. *Pain* 2010; 150: 268-274
7. Lichtman DM, Florio RL, Mack GR. Carpal tunnel release under local anesthesia: evaluation of the outpatient procedure. *J Hand Surg* 1979; 4: 544-546
8. Lozano-Calderón S, Anthony S, Ring D. The quality and strength of evidence for etiology: example of carpal tunnel syndrome. *J Hand Surg* 2008; 33: 525-538.
9. MacDonald RI, Lichtman DM, Hanlon JJ, Wilson JN: Complications of surgical release for carpal tunnel syndrome. *J Hand Surg* 1978; 3: 70-76.
10. Merskey HE. Classification of chronic pain: descriptions of chronic pain syndromes and definitions of pain terms. *Pain*, 1986.
11. Michelsen H, Posner MA. Medical history of carpal tunnel syndrome. *Hand Clin* 2002; 18: 257-268.
12. Schuind F, Ventura M, Pasteels JL. Idiopathic carpal tunnel syndrome: histologic study of flexor tendon synovium. *J Hand Surg* 1990; 15: 497-503.
13. Shinya K, Lanzetta M, Conolly W. Risk and complications in endoscopic carpal tunnel release. *J Hand Surg (British & European Volume)* 1995; 20: 222-227.
14. Turner A, Kimble F, Gulyás K, Ball J. Can the outcome of open carpal tunnel release be predicted? A review of the literature. *ANZ J Surg* 2010; 80: 50-54.