



THE FACTORS AFFECTING FUSION AFTER ANTERIOR ODONTOID SCREW FIXATION FOR TYPE II ODONTOID FRACTURES: A RETROSPECTIVE STUDY OF 12 CONSECUTIVE PATIENTS

¹Anas ABDALLAH¹,
²Ali Ender OFLUOĞLU²

¹ Department of Neurosurgery,
Bezmialem Vakif University, Istanbul,
Turkey

² Department of Neurosurgery, Health
Science University, Bakırköy Research
and Training Hospital for Neurology
Neurosurgery, and Psychiatry, Istanbul,
Turkey

Orcid no:

Anas Abdallah,

<https://orcid.org/0000-0003-3600-089X>

Ali Ender Ofluoglu,

<http://orcid.org/0000-0003-2362-9648>

* There are no financial disclosures or
conflicts of interest.

** This retrospective study was approved
under decision number: (507/2015) by
the medical ethics committee of Bakırköy
Research and Training Hospital for
Neurology Neurosurgery, and Psychiatry
(BRSHH) in Istanbul-Turkey.

Address: Anas Abdallah,
MD, Department of Neurosurgery,
Bezmialem Vakif University, Adnan
Menderes Bulvarı, Vatan Street, 34093
Fatih, Istanbul, Turkey

E-mail: abdallahanas@hotmail.com;
aabdallah@bezmialem.edu.tr

Phone: +90 212 523 22 88-2175

Cell-Phone: +90 553 223 35 35

Fax: +90 212 453 18 69

Received: 11th June, 2018.

Accepted: 30th August, 2018.

ABSTRACT

Background: The injury mechanism of type II odontoid fractures (TIOFs) generally occurs as a result of strong flexion or extension that associated to axial overload. This study aimed to find the factors that may affect the surgical outcomes of TIOF by evaluating the long-term surgical outcomes of 12 consecutive cases.

Material and methods: Medical records were retrospectively reviewed for all TIOF cases that were diagnosed or/and underwent surgery in our hospitals from 2011 to 2016. All TIOF patients who were underwent anterior screw fixation constituted the core sample for this study.

Results: This series included three females and nine male patients, with a mean age of 48.8±20.9 (16–85) years. The mean follow-up period was 44.9±22.4 (12–74) months. The mean of duration between the accident and surgery was 9.6±22.0 (0–77) days. Traffic accident (n=6) and falling (n=6) were the causes of the TIOF in our patients. The most common complaint was neck pain (100%). Preoperative Frankel scale was D (4) in four patients while all patients were discharged with Frankel grade E (5). On 12th month-control visit the rate of fusion was 83.3% (10/12). Two patients were revised for malposition.

Conclusions: Anterior odontoid screw fixation is a minimal invasive approach. Using this approach is safety for the posterior cervical elements. Despite our series is not big enough to generalize, smoking and etiologies did not affect fusion, whereas advanced age (> 79) and history of more than one chronic disease can cause delayed fusion.

Key words: Anterior transodontoid, traction, type II odontoid fractures, minimal invasive approach

Level of Evidence: Retrospective clinical study, Level III

INTRODUCTION

Odontoid process fractures are common cervical spine injuries, accounting for 10 to 20 % of all cervical spine fractures (7). The most common odontoid process fractures are type II odontoid fractures (TIOFs) which are occur at the junction of the odontoid process and the body of the second cervical vertebra. These fractures usually result in atlantoaxial instability (1). The injury mechanism of TIOFs generally occurs because of strong flexion or extension that associated to axial overload.

TIOFs are occurring in 65 % to 74 % of the odontoid process fracture cases (14). These fractures have similar biomechanical properties as transverse

ligament injuries, i.e., a loss of the translational restriction of axis (i.e. the first cervical) vertebra on dens (i.e. the second cervical) vertebra, creating the potential for spinal cord injury and severe late craniocervical deformities when healing is not obtained (10,12). Treatment strategies for odontoid fractures can vary from observation [i.e. nonoperative management with an external immobilization (such as a cervical collar, Minerva, and other cervicothoracic orthoses, and halo orthosis)], to operative management with anterior odontoid screw fixation and/or posterior cervical fusion with or without supplemental screw fixation (3-4,10).

The most common etiologies falling in elderly adults, and traffic accidents in

normal population. Only transodontoid anterior screw fixation provides immediate stabilization of the spine and can preserve normal motion between first and second cervical vertebrae. Anterior transodontoid screw fixation that is a minimal invasive method should be the first choice for treating TIIOF. This study aimed to find the prognostic factors that may affect the surgical outcomes of TIIOF by evaluating the long-term surgical outcomes of 12 consecutive cases.

MATERIALS AND METHODS

Patient population

This retrospective study was approved by the medical ethics committee of our hospital. Written informed consent was obtained from the patients for the publication of their cases and accompanying images.

Medical records were retrospectively reviewed to identify all cases of TIIOF diagnosed and surgically treated in the Department of Neurosurgery of our hospitals, between 2011 and 2016. All spinal TIIOF patients (n = 12) who were underwent anterior screw fixation constituted the core sample for this study. The patient characteristics, etiology, the period between diagnosis and surgical intervention, co-morbidity factors, hospital stay length, surgical complications, Frankel classes/grades (Table-1) ⁽⁶⁾ for pre- and postoperative neurological functional assessments have been evaluated, and the prognostic factors that may affect the fusion and surgical outcomes of TIIOF.

Table-1. Frankel scale (8).

Class	Description	Grade
A	Complete loss of motor and sensory function	1
B	Complete motor and incomplete sensory damage	2
C	Severe, but incomplete motor and partial sensory damage	3
D	Partial motor and sensor damage	4
E	Normal motor and sensory function	5

Statistical analysis

All data are expressed as the mean ± standard deviation with the range shown in parentheses. Differences between groups were assessed by a one-way analysis of variance (ANOVA) using the SPSS 21.0 statistical package. Significance in the multivariate model was determined using a p value of < 0.05, and a trend-level effect was assigned to a p = 0.05–0.10. All p values were presented with an odds ratio (OR). OR are presented with the 95

% confidential interval (CI). When OR could not be calculated, relative risk ratio (RR) was calculated. All tests were two tailed.

Surgery

Under general anesthesia the patients are positioned supine with the head held in fixation device after supporting roll on neck to get extension of head in like 15 degrees. This position may change according to manner that the odontoid fracture is best oriented so as to achieve optimum reduction. If the fracture needs reduction, reduction was performed using Gardner-Wells tongs (2-3 Kg).

A pad is placed between the shoulders. A radiolucent bite block is positioned if the transoral anteroposterior odontoid view will be used radiologically. In our series, reduction used in seven patients. C-armed fluoroscopic images are obtained in the anteroposterior and lateral planes. The patient's neck is prepared and draped, and a unilateral horizontal incision is made at approximately the level fifth cervical vertebra. The platysma is then elevated and divided, and the fascia of the sternocleidomastoid is incised approximately with a 5-cm incision along its medial border. Blunt dissection is used to expose the spinal column by opening natural corridors medial to the carotid artery sheath and lateral to the trachea and esophagus. The fascia of the musculus longus colli is incised in the midline, and the muscle is elevated from the vertebral bodies at the C5-6 level. Caspar retractor is then inserted beneath the musculus longus colli bellies bilaterally and secured with a special lateral self-retaining retractor. This forms a stable base for the rostral retraction. Blunt dissection in the retropharyngeal space is used to open a tunnel in front of the second cervical vertebral body. A K-wire is then inserted through the incision, up to the inferior edge of second cervical vertebra, under fluoroscopic control and impacted into the inferior edge of the second cervical vertebra. A single transodontoid anterior screw was used for all our patient, therefore a midline entry site is chosen for placement. Then, a hollow 8-mm drill is placed over the K-wire and rotated by hand to create a shallow groove in the face of third cervical vertebra and the C2-3 disc and annulus to the inferior border of the second cervical vertebra without removing any of the second cervical vertebra. The drill guide system is then placed over the K-wire. A plastic impactor cover is placed over these, and the spikes of the outer guide tube are firmly set into third cervical vertebra under fluoroscopic guidance. The inner drill guide is then extended to contact the inferior edge of second cervical vertebra. Once the guide tubes are secured, the K-wire is removed and replaced with a drill bit, which engages the starter hole made by the K-wire. The drill is calibrated to allow accurate depth measurement. The drilled hole is then tapped by removing the drill and the inner drill guide, replacing them with

the tap that is manipulated by hand while monitoring its progress fluoroscopically. The screw, selected based on the measured depth, is placed through the outer guide tube and into the body of the second cervical vertebra through the drilled and tapped hole. The screw is placed into the odontoid and tightened firmly, as progress is monitored fluoroscopically (Fig. 1).

At this point, flexion-extension of the patient's neck under fluoroscopy is used to confirm spinal stability. The retractors are then removed. After hemostasis using serum physiologic water, All layers were closed appropriately with their anatomy.

Patients are not required to wear cervical collars postoperatively unless radiographic evidence of osteopenia or the presence of associated cervical fractures were observed.

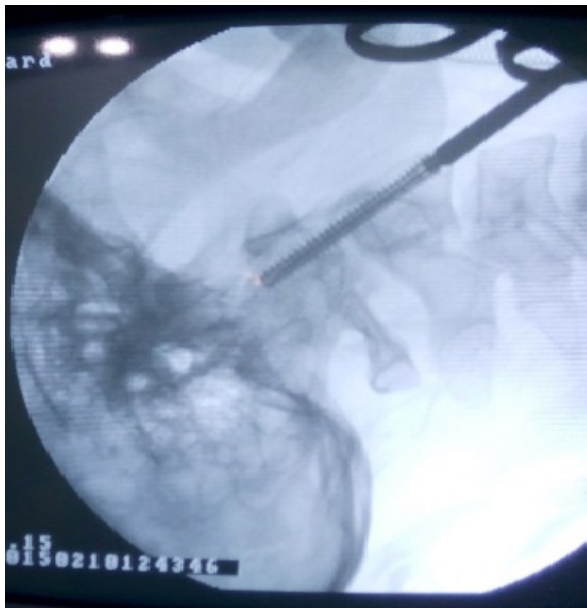


Figure-1. Perioperatively obtained lateral plain radiographs revealed on correct placement of a single anterior odontoid screw across the odontoid fracture site.

Patient Follow-up

As a part of standard care, the patients undergoing surgical intervention for TIIOFs using single anterior odontoid screw fixation received routine clinical evaluations and serial postoperative early CT, anteroposterior and lateral flexion-extension x-rays films (in first 24 hours after surgery) as well as during their follow-up visits at 6 weeks, 3, 12, 24, 48 months x-rays were performed. To assess the

patients' neurological status we used Frankel grades (Table 1). Since Frankel et al. introduced their scale in 1961⁽⁶⁾, this scale (i.e., Frankel scale) which is a 5-point severity scale has commonly been used to determine the severity of the spinal cord injuries. Postoperative CT were obtained at 12, 18 and 24 months to investigate the status of fusion. Anatomical bone fusion was considered successful if there was trabeculation across the fracture site, the absence of movement on lateral flexion-extension films, and anatomical alignment of the fracture fragment. Non-anatomical bone union was considered to have occurred if there was trabeculation across the fracture site, the absence of movement on lateral flexion-extension radiographic studies, and the presence of non-anatomical alignment of the odontoid fracture fragment. The presence of fibrous union was accepted if a visible fracture line was present and movement was absent on flexion-extension x-ray films⁽¹⁾. The patients who had developed nonunion on his/her 12th months-visit considered as delayed fusion, if he/she had fusion in his/her follow-up visits.

The patients' neurological symptoms before surgical intervention and at all clinical follow-up were recorded. Any clinical symptoms such as hemiparesis, loss of sensation, new neurological deficits, surgical site infection, dysphagia, CSF fistula, worsening deficits or death during the first 30 postoperative day were considered to be surgical-related complications.

RESULTS

Patients Characteristics

This series included three females and nine male patients, with a mean age of 48.8 ± 20.9 (16–85) years. The mean follow-up period was 44.9 ± 22.4 (12–74) months. The mean of duration between the accident and surgery was 9.6 ± 22.0 (0–77) days. Traffic accident (n=6) and falling (n=6) were the causes of the TIIOF in our patients. The most common complaint was neck pain (100%). Comorbidity factors are shown in Table-2.

Preoperative Frankel grade was D [4] in four patients while all patients were discharged with Frankel grade E [5]. The mean hospital stay length was 5.4 ± 7.4 (1–26) days. On 12th month-control visit the rate of fusion was 83.3% (10/12) (Table-2). The most common associated physical finding was cranial fracture which was detected in a total of six patients; five patients in traffic accident group and in one patient in falling group. Mean operation duration was 77.3 ± 16.1 minutes (range, 52–96 minutes). Mean intraoperative blood loss was 90 ± 42.4 cc (range, 35–130 cc).

Table-2. Baseline clinical and demographic characteristics of the 12 TIIOF patients.

No.	Age/ Sex	Casue	Diagn. Time	Pre Frankel	Co-Morbidity	POD (day)	Follow (mn)	Post Frankel	Complication
1	24,M	Traffic	Same day	5 (E)	Smoking	14	74	5 (E)	Revised
2	16,M	Traffic	After 77 days	5 (E)	-	4	70	5 (E)	-
3	73,F	Falling	After 20 days	5 (E)	HT, DM Hypothyroidism	26	68	5 (E)	SSI, transient dysphagia
4	63,M	Falling	Next day	5 (E)	Smoking, Alcohol	2	64	5 (E)	-
5	49,F	Traffic	After 4 days	4 (D)	HT, Smoking	3	62	5 (E)	-
6	33,M	Falling	Same day	5 (E)	Smoking	4	45	5 (E)	-
7	46,M	Falling	Same day	4 (D)	Smoking	3	41	5 (E)	-
8	36,M	Traffic	Same day	5 (E)	Smoking	4	38	5 (E)	Revised
9	85,M	Falling	After 2 days	4 (D)	HT, DM, Smoking	1	26	5 (E)	-
10	46,M	Traffic	After 3 days	5 (E)	Smoking	1	25	5 (E)	-
11	72,M	Falling	After 6 days	4 (D)	-	2	14	5 (E)	-
12	42,F	Traffic	After 2 days	5 (E)	-	1	12	5 (E)	-

M: Male; F: Female; HT: Hypertension; DM: Diabetes Mellitus; POD: Postoperative day; SSI: Surgical site infection.

Surgical Complications

Two patients were revised for malposition. Delayed fusion was seen in two patients; one female patient who had fusion on her 15th month follow-up and one male patient had fusion on his 18th follow-up. The former patient had transient dysphagia and surgical site infection. She was treated with antibiotics and no pains. Both of them are advanced age (73 and 85) and they have hypertension and diabetes mellitus. No patient had new neurological deficits, CSF fistula, worsening deficits or death. No patient needed posterior C1-2 fusion.

Surgical Outcomes and the Factors Affecting Surgical Outcomes

Despite the fact that our series is not big enough to make generalization, we divided patients into two groups; the first group who had delayed anatomical fusion (i.e., fusion had been occurred after the first postoperative 12 months) (n = 2) and the second group who had normal anatomical fusion (i.e., fusion had been occurred in the first postoperative 12 months) (n = 10). The comparison between both groups is given in Table 3. Because of the sample size is too small comorbidities could not investigate separately. History of one or all of chronic diseases such as hypertension, diabetes mellitus, or hypothyroidism was considered as a comorbidity factor. Advanced age (according to our study > 79) [p < 0.0001; X² = 19.45 (student's T-test)] and history of more than one chronic disease delayed fusion [p = 0.045; RR = 10.0 (1.6–64.2)].

Table-3. Factors affecting surgical outcomes in our patients.

	Delayed Fusion Group	Good Fused Group	p	OR/RR and CIs
Number of patients	n = 2	n = 10		
Mean of age (Years)	79±8.5 (73-85)	42.7±16.8 (16-72)	< 0.0001*	X ² = 19.45
Sex (F/M)	1/1	2/8	1.0	OR = 0.25 (0.01 – 6.0)
Etiology (Traf/Fall)	0/2	6/4	0.45	RR = 2.5 (1.1 – 5.3)
Comorbidity** (-/+)	0/2	9/1	0.045*	RR = 10.0 (1.6 – 64.2)
Smoking (-/+)	1/1	3/7	1.0	OR = 0.43 (0.02 – 9.3)
Preoperative deficit (-/+)	1/1	7/3	1.0	OR = 2.3 (0.1 – 51.0)

p < 0.05 is significant. F: Female; M: Male; Traf: Traffic accident; Fall: Falling; OR: Odds ratio; RR: Relative risk ratio; OR and RR are presented with the 95% confidential interval. RR: relative risk ratio.

* Statistically significant; ** Presence of one or more chronic diseases such as hypertension, diabetes mellitus, or hyperthyroidism except for smoking or alcohol abusing.

DISCUSSION

Since the beginning of 1980s several spine surgeons (1,3-4,7-8,10-14) have advocated anterior odontoid screw fixation. Thanks of advances in the quality of intraoperative fluoroscopy and improvements in surgical instrumentation were made that this procedure gained wider acceptance in recent years.

Stabilization of TIIOFs requires surgical fixation and/or rigid external immobilization. External immobilization using a rigid orthosis may allow for fusion without the necessity for surgical procedure, but it is limited because of prolonged limitation of the patient's function and higher nonunion rates. In surgical stabilization procedures surgeon has relied primarily on posterior atlantoaxial fusion in which he uses a variety of bone and wire constructs. However, posterior fusion is associated with lower rates of nonunion, it restricts normal rotatory motion between first and second cervical vertebrae, which accounts for more than 50 % of all cervical spine rotatory motion, and reduces cervical spine flexion and extension rotation by 10 % (1,10).

The most common seen problem in TIIOFs is the difficulty in the formation of fusion. In the chronic or late-diagnosed TIIOFs, the difficulty of spontaneous fusion due to sclerosis that occurs on both sides of the fracture line becomes a significant problem (11). In such cases, a K wire with a narrow diameter is inserted on the surface of the vertebral column towards the sclerotic odontoid surface and passes the sclerotic band four or five times in order to support the development of fusion by damaging the surface on both sides; thus, fusion may achieved in such late-diagnosed patients (15).

If the gap between the fracture and vertebrae is more than 6 mm, this space affects the formation of fusion negatively. Apuzzo et al. found the non-union rates of fractures to be 33 % in the cases with dislocations more than 4 mm in their series of 45 patients (2). The dislocation gap of the dens is also an important factor for fusion in patients with a brace. In their series of 107 patients, Hadley et al., reported the non-union rates in patients who had a dislocation over 6 mm as 67 % while the rate was 9 % for dislocations below 6 mm (9). Furthermore, age is another important factor and spontaneous fusion rates decrease after the age of 40 (5,9). In our results advanced age was a significant factor affected anatomical bone fusion negatively.

Apfelbaum et al. study (1) reported a total of 147 patients who received anterior odontoid screw fixation; 138 patients with TIIOFs and 9 patients with TIIIOfs. They described 129 patients as recent fractures (< 6 months) and 18 patients as remote fractures (≥ 18 months). The study investigated the factors may affect bone fusion in their long series and they found that anatomical bone fusion

was significantly affected by only fracture orientation. Patients' sex, age, fracture type, number of screws placed and degree of odontoid displacement had not impact on anatomical bone fusion. According to Apfelbaum et al., fractures oriented in the anterior oblique orientation were significantly more likely to result in nonanatomical union, fibrous union, or nonunion than posterior oblique and horizontal oriented fractures (1). In our series 7 patients needed reduction. After reduction all orientations were the same so we could not compare orientations between delayed and normal fused groups. On opposite to Apfelbaum et al. study, we found that advanced age and comorbidity factors are factors can significantly affect anatomical bone fusion. Because of the limited patients number we could not be sure if these factors (advanced age and comorbidities) are independent factors or not.

The high rate limitations associated with either conservative or posterior surgical methods for odontoid fracture stabilization, several spine surgeons have begun to use direct anterior screw fixation to treat TIIOFs. Direct anterior screw fixation is an osteosynthetic technique that can provide immediate spinal stabilization. The results of several clinical studies have shown that anterior screw fixation can preserve normal C1-2 rotatory motion (8,13). Montesano et al. study has reported that in 83% of their patients seen in follow up, full range of motion was maintained after anterior screw fixation of odontoid fractures (13).

The study has several limitations: first, it's a retrospective study that may suffer from the inherent bias. Second, the sample size of our cohort is small to make generalizations. Third, the results are a single center results. Further prospective studies with larger sample size are needed to validate our results.

CONCLUSIONS

Anterior odontoid screw fixation is a minimal invasive approach. Using this approach is safety for the posterior cervical elements. Despite our series is not big enough to make generalization, smoking and etiologies did not affect fusion, whereas advanced age (> 79) and history of more than one chronic disease can cause delayed fusion.

Disclosure of Potential Conflicts of Interest

The authors declare that they have no conflict of interest.

REFERENCES

1. Apfelbaum RI, Lonser RR, Veres R, Casey A. Direct anterior screw fixation for recent and remote odontoid fractures. *Neurosurg Focus* 2000; 8(6): Article 2.
2. Apuzzo ML, Heiden JS, Weiss MH, Ackerson TT, Harvey JP, Kurze T. Acute fractures of the odontoid process. An analysis of 45 cases. *J Neurosurg* 1978; 48: 85-91.

-
3. Dailey AT, Hart D, Finn MA, Schmidt MH, Apfelbaum RI. Anterior fixation of odontoid fractures in an elderly population. *J Neurosurg Spine* 2010; 12: 1-8.
 4. Denaro V, Papalia R, Di Martino A, Denaro L, Maffulli N. The best surgical treatment for type II fractures of the dens is still controversial. *Clin Orthop Relat Res* 2011; 469: 742-750.
 5. Dunn ME, Seljeskog EL. Experience in the management of odontoid process injuries. An analysis of 128 cases. *Neurosurgery* 1986; 18: 306-310.
 6. Frankel HL, Hancock DO, Hyslop G, Melzak J, Michaelis LS, Ungar GH, Vernon JD, Walsh JJ. The value of postural reduction in the initial management of closed injuries of the spine with paraplegia and tetraplegia. *Paraplegia* 1969; 7: 179-192.
 7. Fujii E, Kobayashi K, Hirabayashi K. Treatment in fractures of the odontoid process. *Spine* 1988; 13: 604-609.
 8. Geisler FH, Cheng C, Poka A, Brumback RJ. Anterior screw fixation of posteriorly displaced type II odontoid fractures. *Neurosurgery* 1989; 25: 30-38.
 9. Hadley MN, Walters BC, Grabb PA, Oyesiku NM, Przybylski GJ, Resnick DK, Ryken TC. Isolated fractures of the axis in adults. *Neurosurgery* 2002; 50 (Supp.-3): 125-139.
 10. Joaquim A, Patel AA. Surgical treatment of Type II odontoid fractures: anterior odontoid screw fixation or posterior cervical instrumented fusion? *Neurosurg Focus* 2015; 38(4): E11.
 11. Keskin F, Gomleksiz C, Sasani M, Oktenoglu T, Suzer T, Ozer AF. Clinical Results of Anterior Odontoid Screw Fixation for Type II Odontoid Fractures. *Turk Neurosurg* 2014; 24(5): 750-756.
 12. Mashhadinezhad H, Samini F, Mashhadinezhad A, Birjandinejad A. Clinical results of surgical management in type II odontoid fracture: a preliminary report. *Turk Neurosurg* 2012; 22: 583-587.
 13. Montesano PX, Anderson PA, Schlehr F, Thalgott JS, Lowrey G. Odontoid fractures treated by odontoid anterior screw fixation. *Spine* 1991; 16 (Suppl.-3): S33-S37.
 14. Müller EJ, Schwinnen I, Fischer K, Wick M, Muhr G. Nonrigid immobilisation of odontoid fractures. *Eur Spine J* 2003; 12: 522-525.
 15. Ozer AF, Cosar M, Oktenoglu TB, Sasani M, Iplikcioglu AC, Bozkus H, Bavbek C, Sarioglu AC. A new transodontoid fixation technique for delayed type II odontoid fracture: Technical note. *Surg Neurol* 2009; 71(1): 121-125.